

The posterior maxilla: An update of anatomical notions based on advances in endosseous implant surface technology. A case report

Miguel Faria **LIMA***

Raquel Parreiras **FERREIRA***

Alex Martins **GOMES****

João Lima **RODRIGUES***

Paulo Franco **TAITSON*****

Abstract

Objective: Fixed implant-supported rehabilitation of the posterior maxilla is a challenge to dental professionals. Limitations of technique and material have established wrong concepts, especially with regard to bone classification. For instance, the concept of poor-quality bone has been associated with high rates of therapeutic failure because of implants with poorly evolved surfaces. A literature review on the embryological origin of tissues and the anatomy of the maxilla highlight the high regenerative ability of trabecular bone, which is rich in mesenchymal cells. **Methods:** The present report describes a case of failure of a machined-surface implant placed by osteotomy at the maxillary first molar region. The implant was replaced by a sandblasted, large grit, acid-etched SLA surface with a six-year survival rate follow-up. Clinical and radiographic assessments were performed every six months. **Results:** Data revealed implant osseointegration stability as well as tissue biocompatibility and prosthetic functionality. **Conclusion:** The literature on technically advanced implant surfaces suggests that the posterior maxilla is a safe and predictable site for fixed implant-supported rehabilitation.

Keywords: Maxilla. Dental implants. Osteotomy. Osseointegration. Anatomy.

How to cite this article: Lima MF, Ferreira RP, Gomes AM, Rodrigues JL, Taitson PF. The posterior maxilla: An update of anatomical notions based on advances in endosseous implant surface technology. A case report. *Dental Press Implantol.* 2013 July-Sept;7(3):61-5.

» The authors inform they have no associative, commercial, intellectual property or financial interests representing a conflict of interest in products and companies described in this article.

Contact address

Miguel Faria Lima

Rua Juiz de Fora, 1268 - Conjunto 1301 - Bairro Sto. Agostinho
Belo Horizonte/MG - Brazil - CEP: 30180-061
E-mail: migbern@yahoo.com.br

» The patient displayed in this article previously approved the use of her facial and intraoral photographs.

Submitted: March 03, 2013

Revised and accepted: July 16, 2013

* MSc in Prosthesis, Catholic University of Minas Gerais (PUC-MINAS)

** MSc in Periodontology, Catholic University of Minas Gerais (PUC-MINAS)

*** Adjunct professor, Department of Human Anatomy, Catholic University of Minas Gerais (PUC-MINAS)

Introduction

The development of Implantology as a dental specialty has resulted in new possibilities for the oral rehabilitation of edentulous patients, and, as a consequence, has made the outcomes of such treatments increasingly predictable.¹ However, the technology used in its early stages resulted in a high osseointegration failure rate, mostly due to the lack of interaction at the interface of contact between the bone and smooth or machined-surface implants. Some hypotheses have mistakenly associated structural deficiencies in certain craniofacial regions with implant failure. Such regions, particularly the posterior maxilla, have thus been classified as poor-quality bone.²

The posterior maxilla predominantly consists of trabecular or spongy bone. It is characterized not only by fast absorption of the alveolar bone after tooth loss, but also by maxillary sinus pneumatization, which usually worsens the prognosis of implant-supported rehabilitation. Moreover, the literature emphasizes the importance of the anatomical formation of the posterior maxilla and the advances in implant surfaces treatment.^{3,4}

Bone classifications are being currently reviewed by studies that address technologically advanced implants, particularly those with rough, high-energy, hydroxylated, and bioactive surfaces. Such surfaces stimulate the migration and transformation of mesenchymal cells into osteoblasts, thus shortening the healing process and improving the predictability of implant-supported rehabilitation therapy in the posterior maxilla. In addition, implants are placed using non-invasive techniques, such as osteotomy.^{5,6,7}

Case report

The present case report describes the treatment performed on a Caucasian, 59-year-old, female, non-smoker patient in good overall health who required periodontal treatment and oral rehabilitation. After conservative periodontal treatment was performed, unfavorable elements

of the anterior and posterior maxilla were removed, and fixed implant-supported rehabilitation was planned. After extraction of #24 and 26, machined-surface implants (Steri-Oss system, Yorba Linda, CA) were placed using 3.8 x 10 mm implant burs in the region of #25, and by means of osteotomy with a 4.5 x 8 mm implant installed in the region of #26. In accordance with the manufacturer's instructions, the healing cap was placed six months after the first procedure.

However, after a follow-up period of 20 months, osseointegration failed (Fig 1) at the second surgical stage, and the implant was covered by fibrous tissue (Figs 2, 3, 4, and 5). The affected area was subjected to scaling, and six months were allowed for healing (Figs 6 and 7). After this six-month healing period, a non-submerged wide-neck 4.8 x 8 mm implant with a sandblasted, large-grit, acid-etched surface (SLA® Straumann Dental Implant System, Basel, Switzerland) was installed in the same region by means of the same osteotome technique (Figs 8 and 9).

After a healing period of sixteen weeks (Figs 10 and 11), the patient was subjected to solid abutment fixation (Fig 12) with torque of 35 N and provisionalization. Masticatory load was established after eight months when implants were finalized with metal-ceramic crowns (Figs 13 and 14). Since then, the patient has been monitored every six months. Results were considered satisfactory after five years (Figs 15 and 16).

Discussion

A wide body of scientific evidence supports the success of treatment using SLA surfaces⁸ at the posterior maxilla.^{9,10,11} Nevertheless, the literature still refers to bone classifications that describe the posterior maxilla as poor-quality bone. Such classifications are based on the results of the interaction between the bone and smooth or machined surfaces, which demand longer implants and a greater initial stabilization in the cortical bone. The classification of stabilization in

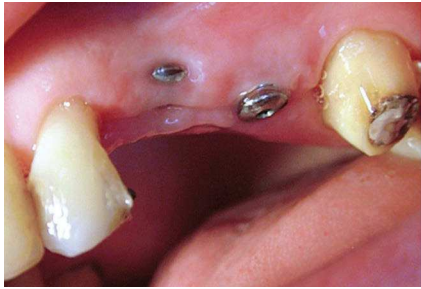

Figure 1 - Failure in implant #26 osseointegration was observed after 20 months.

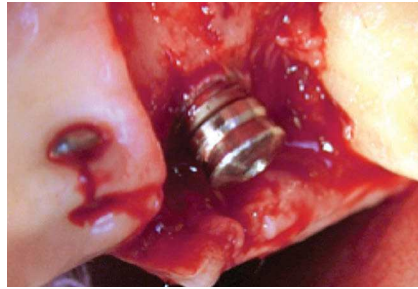


Figure 2 - Implant removal without osseointegration.

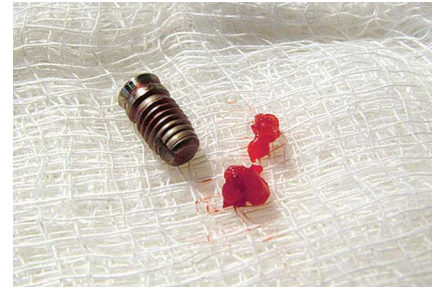


Figure 3 - Removed implant and fibrosis associated with the machined surface.

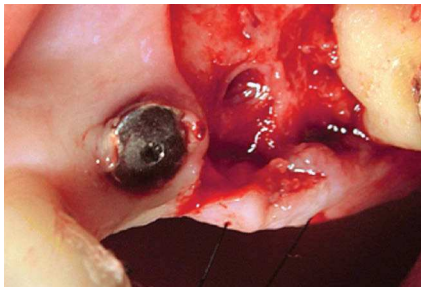


Figure 4 - Fibrosis associated with the implant site.

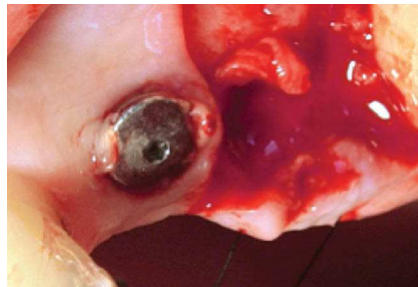


Figure 5 - Removal of fibrosis.

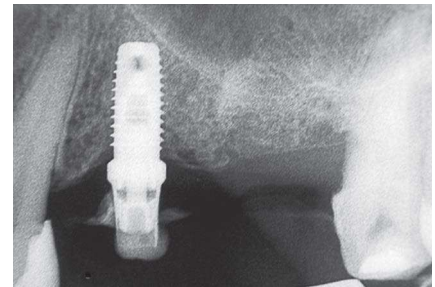


Figure 6 - Radiograph showing healing six months after failure in implant #26 and the presence of machined implant surface of #24.

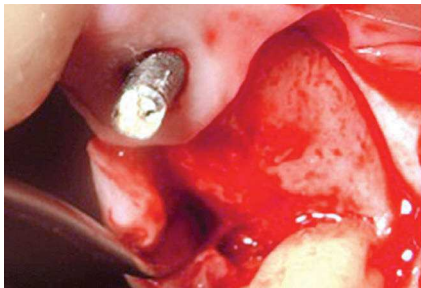


Figure 7 - Complete bone repair after six months.




Figure 8 - Straumann wide-neck 4.8 x 8 mm SLA Plus implant.

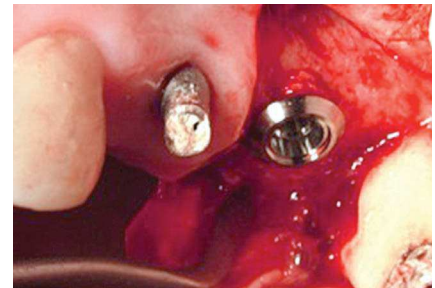

Figure 9 - Implant placement by osteotomy.

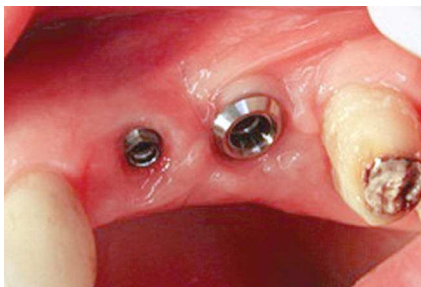

Figure 10 - Sixteen weeks after healing.

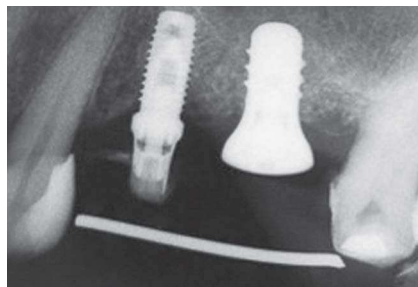


Figure 11 - Radiographic image after healing.

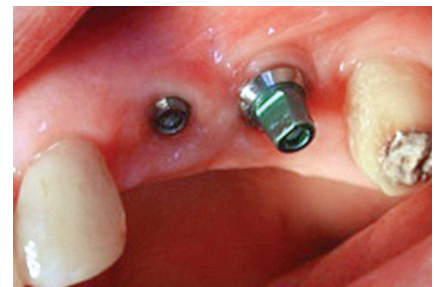

Figure 12 - Solid abutment fixation with torque of 35 N.

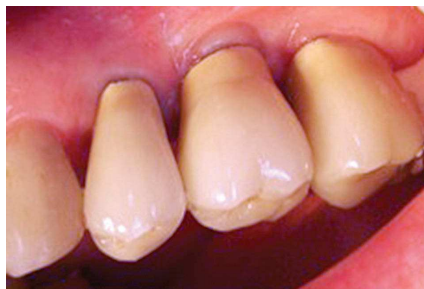

Figure 13 - Fixed metal-ceramic restorations.

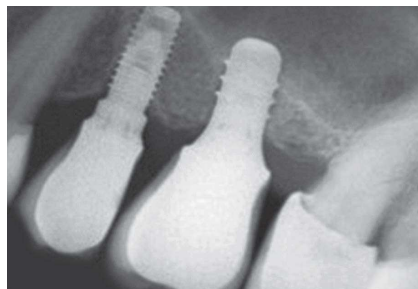

Figure 14 - Radiographic image after restoration placement.

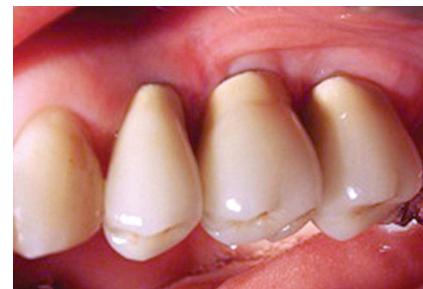

Figure 15 - Metal-ceramic rehabilitation after five years.

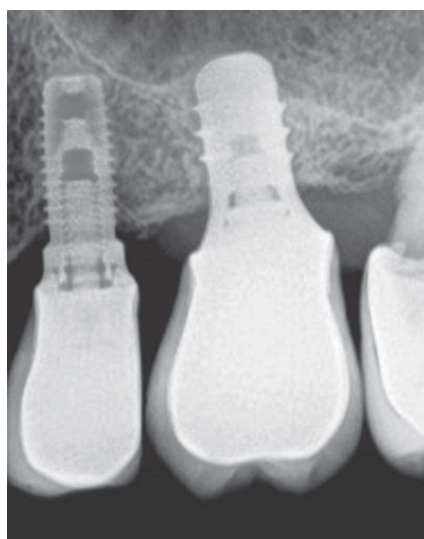


Figure 16 - Digitized radiograph after five years. Note the Bragger index applied in the region.

the cortical bone is based on radiographic assessments and on the feeling of resistance that dental surgeons experience upon implant placement.¹¹²

As a function of the advances in the design and surfaces of implants, osseointegration is accomplished via the activation of mesenchymal cells which are found in large numbers at the posterior maxilla. Treated rough implant surfaces induce the transformation of the mesenchymal cells into osteoblasts, whereas smooth surfaces preferentially induce differentiation into fibroblasts.¹³⁻¹⁶

Rough-surface implants, such as SLA, exhibit higher surface energy and activate stationary mesenchymal cells at the treated region, promoting the fast formation of secondary bone and consequently increasing the predictability of treatment outcomes. They are placed with simple surgical techniques and are associated with lower degrees of morbidity. It is also important to emphasize the increase in bone height that is achieved at the region of the osteotomy and the SLA implant, as measured by Bragger's index.^{2,5}

In an *in vitro* experiment, Kunzler et al¹⁸ showed that the number of osteoblasts at the rough end of implants was almost two-fold greater than the number found at their smooth end, whereas the number of fibroblasts was almost three times higher at the polished titanium surfaces of rough surfaces.

In another *in vitro* experiment, Grösnerr-Schreiber et al¹⁹ found a strong correlation between the number of fibroblast focal adhesion contacts (FACs) and surface roughness, with the highest number of FACs found on the surfaces with the lowest degree of surface roughness. Subcrestal placement of ITI implants showed that reabsorption occurs in the bone adjacent to the polished surface of implants, thus clinically confirming the results of the *in vitro* experiments.^{18,20} The present case report shows the difference between the results obtained with the two approaches, and the follow-up analyses demonstrate the

degree of stability that was achieved in rehabilitation using an implant with an SLA surface. Consequently, scientific evidence and technological advances indicate a need to review the outdated bone classification system that

rates the posterior maxilla as poor-quality bone. The results obtained from this study are similar to those presented by the current literature and suggest that the SLA surfaces are suitable for posterior maxilla.

REFERENCES

- Lekholm U, Zarb GA, Albrektsson T. Patient selection and preparation. In: Brånemark PI, Zarb G, Albrektsson T, editors. *Tissue-integrated prostheses: osseointegration in clinical dentistry*. Chicago: Quintessence; 1985. p. 199-209.
- Davies JE. Understanding peri-implant endosseous healing. *J Dent Educ*. 2003;67(8):932-49.
- Trisi P, Rao W. Bone classification: clinical-histomorphometric comparison. *Clin Oral Implants Res*. 1999;10(1):1-7.
- Molly L. Bone density and primary stability in implant therapy. *Clin Oral Implants Res*. 2006;17(S2):124-35.
- Rupp F, Scheideler L, Olshanka N, de Wild M, Wieland M, Geis-Gerstorfer J. Enhancing surface free energy and hydrophilicity through chemical modification of microstructured titanium implant surfaces. *J Biomed Mater Res A*. 2006;76(2):323-34.
- Buser D, Broggini N, Wieland M, Schenk RK, Denzer A, Cochran D, et al. Enhanced bone apposition to a chemically modified SLA titanium surface. *J Dent Res*. 2004;83(7):529-33.
- Rosen P, Summers R, Mellado JR, Salkin, LM, Shanaman RH, Marks HM, et al. The bone-added osteotome sinus floor elevation technique: multicenter retrospective report of consecutively treated patients. *Int J Oral Maxillofac Implants*. 1999;14(6):853-8.
- Roccuzzo M, Wilson T. A prospective study evaluating a protocol for 6 weeks' loading of SLA implants in the posterior maxilla: one year results. *Clin Oral Implants Res*. 2002;13(5):502-507.
- Lambert FE, Weber HP, Susarla SM, Belser UC, Gallucci GO. Descriptive analysis of implant and prosthodontic survival rates with fixed implant-supported rehabilitations in the edentulous maxilla. *J Periodontol*. 2009;80(8):1220-30.
- Marković A, Calasan D, Colić S, Stojčev-Stajčić L, Janjić B, Mišić T. Implant stability in posterior maxilla: bone-condensing versus bone-drilling: a clinical study. *Oral Surg Oral Med Oral Pathol Oral Radiol Endod*. 2011;112(5):557-63.
- Brägger U, Gerber C, Joss A, Haenni S, Meier A, Hashorva E, et al. Patterns of tissue remodeling after placement of ITI® dental implants using an osteotome technique: a longitudinal radiographic case cohort study. *Clin Oral Implants Res*. 2004;15(2):158-66.
- Buser D, Nydegger T, Oxland T, Cochran DL, Schenk RK, Hirt HP, et al. Interface shear strength of titanium implants with a sandblasted and acid-etched surface: a biomechanical study in the maxilla of miniature pigs. *J Biomed Mater Res*. 1999;45(2):75-83.
- Buser D, Broggini N, Wieland M, Schenk RK, Denzer AJ, Cochran DL, Hoffmann B, Lussi A, Steinemann SG. Enhanced bone apposition to a chemically modified SLA titanium surface. *J Dent Res*. 2004;83(7):529-33.
- Nedir R, Bischof M, Vazquez L, Szmukler-Moncler S, Bernard JP. Osteotome sinus floor elevation without grafting material: a 1-year prospective pilot study with ITI implants. *Clin Oral Implants Res*. 2006;17(6):679-86.
- Nedir R, Bischof M, Vazquez L, Nurdin N, Szmukler-Moncler S, Bernard JP. Osteotome sinus floor elevation technique without grafting material: 3-year results of a prospective pilot study. *Clin Oral Implants Res*. 2009;20(7):701-7.
- Jemt T, Lekholm U. Implant treatment in edentulous maxilla: a five-year follow-up report on patients with different degrees of jaw resorption. *Int J Oral Maxillofac Implants*. 1995;10:303-11.
- Kunzler TP, Drobek T, Schuler M, Spencer ND. Systematic study of osteoblast and fibroblast response to roughness by means of surface-morphology gradients. *Biomater*. 2007;28(13):2175-82.
- Grössner-Schreiber B, Herzog M, Hedderich J, Dück A, Hannig M, Griepentrog M. Focal adhesion contact formation by fibroblasts cultured on surface-modified dental implants: an in vitro study. *Clin Oral Implants Res*. 2006;17(6):736-45.
- Hämmerle CH, Brägger U, Bürgin W, Lang NP. The effect of subcrestal placement of the polished surface of ITI implants on marginal soft and hard tissues. *Clin Oral Implants Res*. 1996;7(2):111-9.