

# Mini-implant assisted anterior retraction

Carlo Marassi\*, Cesar Marassi\*\*

## Abstract

**Introduction:** Evidence has established orthodontic mini-implants as important anchorage method, which has proved helpful for orthodontists throughout all orthodontic treatment stages, eliminating the need for patient compliance while achieving more predictable results.

**Objective:** This article describes the key aspects of performing anterior retraction with mini-implant anchorage and presents an analysis of mini-implant indications, amount of anterior tooth movement, retraction force vectors, vertical control, mini-implant positioning, different types of anterior support and the amount of force to be applied. The most common mini-implant installation sites used for anterior retraction are highlighted, as well as the factors which should be controlled during space closure. Finally, some clinical considerations are presented to shed light on the use of mini-implants during this significant orthodontic treatment stage.

**Keywords:** Orthodontics. Orthodontic anchorage procedures. Mini-implants. Anterior retraction.

## INTRODUCTION

The anterior retraction stage has great significance in orthodontic treatment. It is in this phase that orthodontists need to maintain or achieve relevant objectives such as cuspid key, molar key, overbite correction and midline coincidence. In order for these goals to be accomplished adequate management of the anchorage unit is required.

For many years orthodontists have utilized mechanics that encompasses anchorage preparation, headgear appliance, and intermaxillary elastics as the key tools to stabilize the posterior segment during the anterior retraction stage.

Today we can rely on resources such as skeletal anchorage, in particular with mini-implants, which have proved efficacious as an anchorage control method by significantly reducing or even eliminating the need for patient compliance, thereby rendering treatment more predictable and efficient (Fig. 1)<sup>5,8,11</sup>.

## INDICATIONS

The use of mini-implants to assist in the anterior retraction phase is likely to benefit individuals who: 1) Find it difficult to cooperate by wearing headgear, intermaxillary elastics or other

\* Orthodontics Specialist – São Paulo University (USP), Bauru. Professor and Scientific Director of the Rio de Janeiro Straight-Wire Group. Coordinator of the Orthodontics Specialist Course of the Leopoldo Mandic Dental Research Center (CPOSLM/RJ); Holds a Master's Degree in Orthodontics from the Leopoldo Mandic Dental Research Center (CPOSLM/Campinas).

\*\* Orthodontics Specialist – Grande Rio University (Unigranrio). Stomatology Specialist – Grande Rio University (Unigranrio). Radiology Specialist – Brazilian Dental Association, Rio de Janeiro (ABORJ).

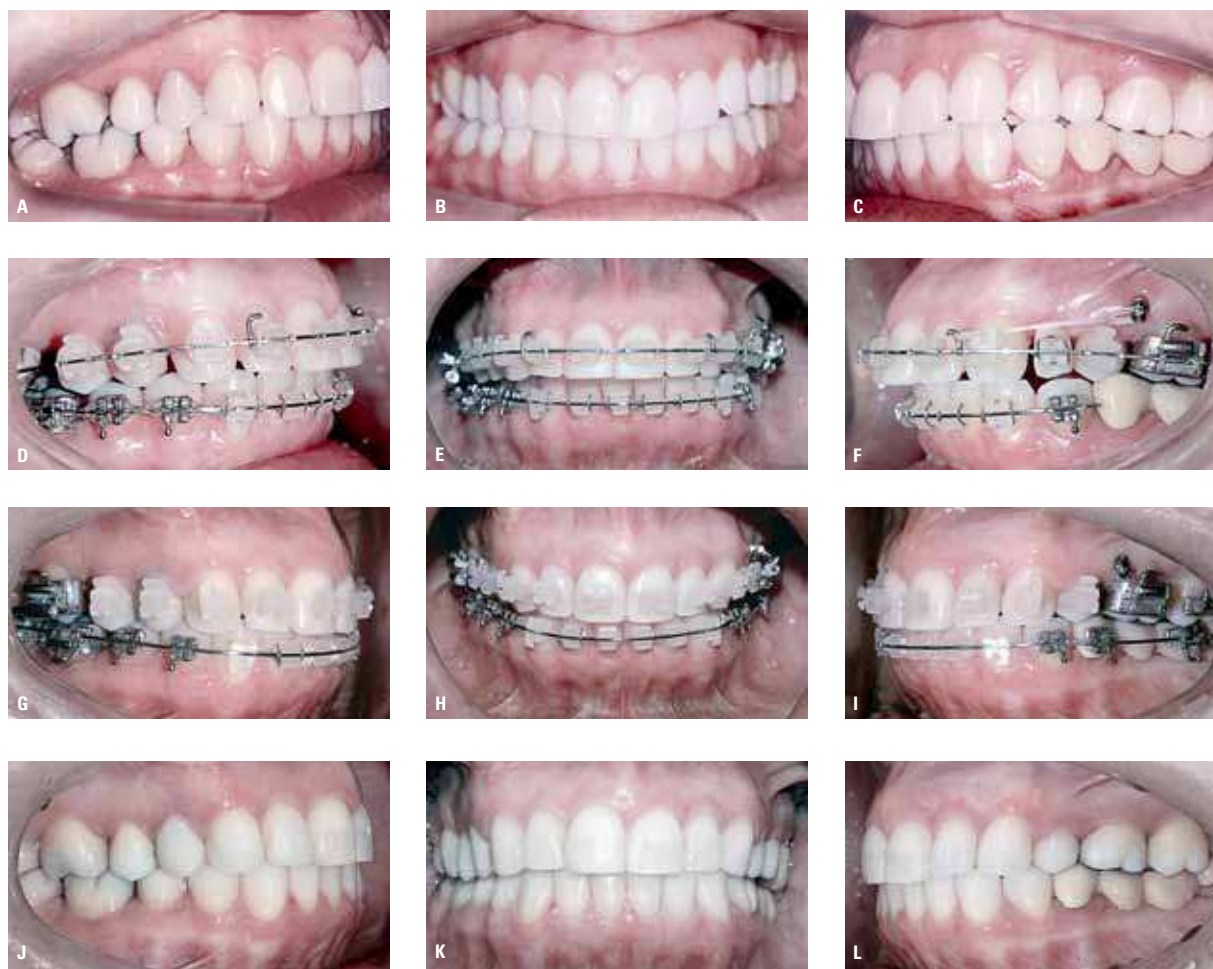

FIGURE 1 - Initial photos: **A)** Class I on the right; **B)** upper midline shifted to the right; **C)** Class II on the left. **D, E, F)** Start of space closure. **G, H, I)** End of space closure with overcorrected midline. **J, K, L)** Finished case.

traditional anchorage methods; 2) Have the need for maximum anchorage on the upper arch, lower arch or both. 3) Whose anchorage may be compromised by too few dental elements, due to root resorption or periodontal disease sequelae; 4) Whose occlusal plane is tipped towards the anterior region<sup>1,12,15</sup>.

## PLANNING AND BIOMECHANICAL CONSIDERATIONS

Judicious planning is crucial for mini-implant success. Orthodontists are strongly advised to con-

sider the factors described below with a view to choosing the best-suited biomechanics for each patient<sup>8,11</sup>.

### Amount of anterior teeth retraction

Although the use of mini-implants allows significant retraction of anterior teeth, caution should be exercised to prevent patient discomfort or injury. A significant incisor retraction can impair an orthodontic patient's facial esthetics, particularly those who present with retrognathic mandible. It should also be noted that slightly increased lip

projections are seen as an asset in society, whereas a significant decrease in lip projection can convey a facial appearance typical of old age.

The amount of bone available in the mandibular symphysis or in the alveolar process of the anterior maxilla is yet another factor that deserves consideration, particularly if an incisor “en-mass” retraction has been planned. Orthodontists should also ascertain that the underlying periodontium allows ample movement, especially in adult patients with periodontal disease sequelae. In addition, it is advisable to assess root length and anatomy relative to resorption risk, mainly when anterior retraction is planned in combination with lingual root torque<sup>8,14</sup>.

### Retraction force vectors and vertical incisor control

Space closure mechanics tend to increase overbite and orthodontists have to add compensatory bends to archwires in order to control this side

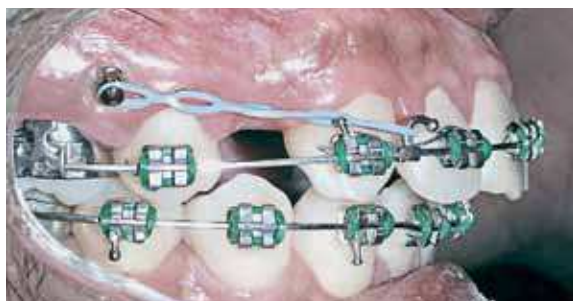


FIGURE 2 - Anterior retraction with direct anchorage

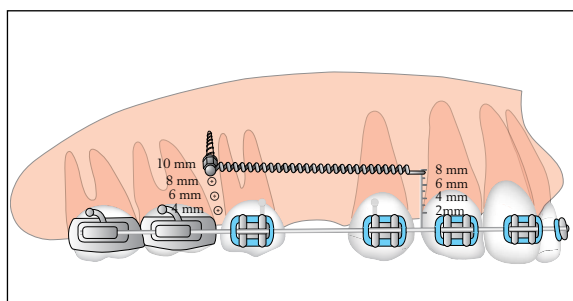


FIGURE 3 - Different possibilities for mini-implant vertical positioning and different anterior region support heights.

effect. Since mini-implants are usually inserted more apically than molar hooks it should be noted that anterior retraction with direct mini-implant anchorage tends to generate a more intrusive force vector on the incisors compared to traditional mechanics (Fig. 2)<sup>8</sup>. This force vector can be controlled by changing mini-implant insertion height and/or anterior region support height, thereby raising a number of different force action line alternatives (Fig. 3). Orthodontists should, therefore, prior to mini-implant installation, define which force action lines will be employed and determine the vertical effect that the force vector will exert upon the anterior teeth<sup>5,8</sup>. Some authors refer to these retraction force vectors as high, medium and low installation. Although such terms are suitable for the maxilla, applying them to the mandible can make their interpretation by surgeons and orthodontists more difficult. Therefore, force vectors are described below according to their impact on the anterior region.

### Retraction with intrusive force vector

This type of retraction is indicated for individuals who present with overbite compounded by incisor extrusion. In this case, mini-implants are usually inserted away from the archwire combined with a short hook in the anterior region (Fig. 4). This type of force vector tends to cause the maxillary occlusal plane to rotate counterclockwise. On the mandible the retraction tends to bring about an occlusal plane clockwise rotation. To enhance

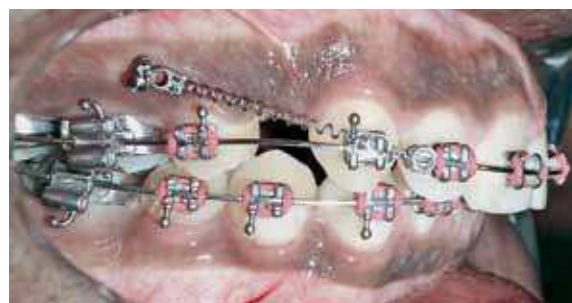

FIGURE 4 - Anterior retraction with intrusive force vector on upper incisors.

the intrusive effect on the incisors, the anterior region hook can be turned towards the occlusal plane (Fig. 13A) instead of the conventional orientation. This mechanics is contraindicated for individuals with reduced overbite or open bite. The intrusive force vectors generated by the mini-implants also tend to yield unfavorable results in unilateral retractions, since these can cause frontal occlusal plane inclination due to the intrusion of one single side of the archwire<sup>5,8</sup>.

### Retraction with extrusive force vector

This type of retraction is used in anterior open bite cases, where a mini-implant is installed close to the archwire and combined with long hooks on the cuspids' mesial region to strengthen incisor extrusion and bite closure (Fig. 5). It is recommended that the degree of incisor exposure be assessed to verify that such approach can be applied to the maxilla since, despite its efficiency, this mechanics tends to cause the occlusal plane to rotate clockwise, thereby increasing anterior teeth exposure. On the mandible there is a tendency for counterclockwise occlusal plane rotation, which helps bite closure. Open bite correction can be further enhanced through the use of elastics connecting the mini-implants to the archwire in the posterior region and achieving lower molar intrusion, which will further benefit the counterclockwise mandibular plane rotation and help even more significantly in the correction of this malocclu-

sion. On the maxilla one could either connect the mini-implants to the posterior segment archwire (Fig. 6) or use a mini-implant on the palatal suture connected to hooks on the transpalatal bar to achieve vertical control of molars during anterior retraction<sup>18</sup>. It should be underscored that upper molar intrusion also causes the maxillary occlusal plane to rotate clockwise, which is likely to over-expose the upper incisors<sup>5,8</sup>.

### Retraction with intermediate force vector

Used in patients with a next-to-normal overbite when little or no occlusal plane alteration is desired. Even in patients with a normal overbite, a slightly intrusive force vector can be used to offset an incisor extrusion tendency, which takes place during anterior retraction (Fig. 7)<sup>5,8</sup>.

Incisor vertical control can also be accomplished by means of archwire bends or the insertion of a mini-implant in the anterior region to achieve incisor intrusion during the retraction stage (Fig. 8). This mechanics is indicated for individuals presenting with either a narrow attached gingiva on the posterior segment or a low maxillary sinus, which may hinder the installation of a more apically positioned mini-implant<sup>2,5,8,12</sup>.

### Vertical positioning and insertion angle of mini-implants<sup>1,5,8,12</sup>

When mini-implants are used as direct anchorage, installation height is likely to exert a

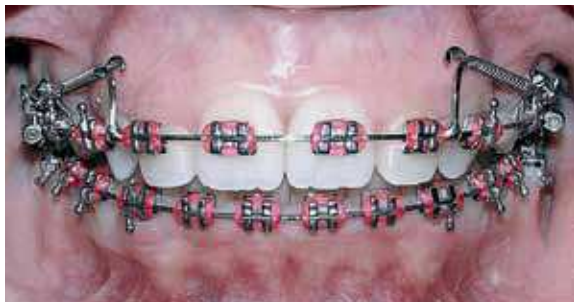

FIGURE 5 - Anterior retraction with extrusive force vector on upper incisors.

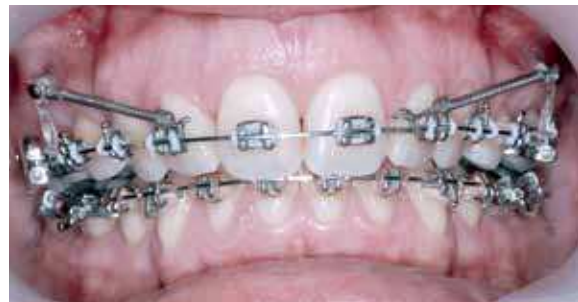

FIGURE 6 - Anterior retraction combined with upper molar vertical control.

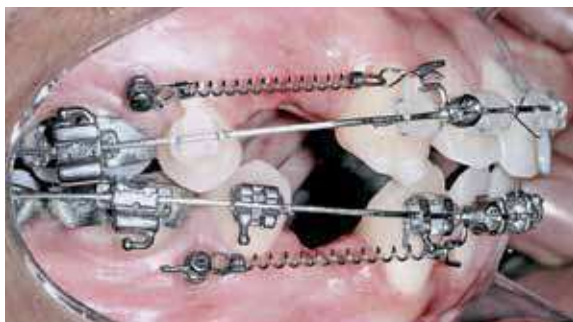

FIGURE 7 - Anterior retraction with intermediate vector on upper and lower incisors.

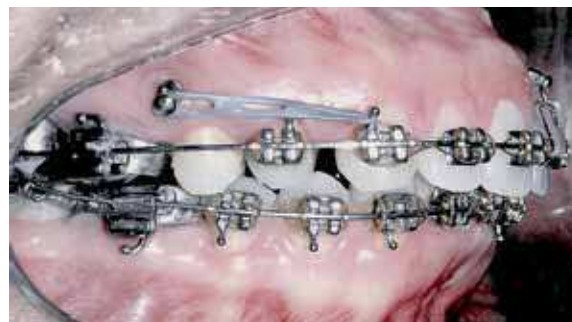

FIGURE 8 - Anterior retraction with intermediate force vector combined with anterior intrusion and a mini-implant inserted between incisors.

considerable impact on the force action line used in incisor retraction. Orthodontists are advised to determine insertion height in line with treatment goals, taking into account each patient's anatomical limitations. A more apical installation, i.e. farther away from the bone crest and the orthodontic archwire (8mm insertion point above the papilla or higher) is recommended in cases where an anterior retraction movement is intended, in combination with incisor intrusion. This installation is limited by the width of the zone of attached gingiva available and by the presence of the maxillary sinus. In general, the mucogingival line sets the apical installation limit since mini-implants that are inserted in the attached gingiva yield better results and are more comfortable for the patient. Orthodontists should assess whether or not it would be wise to install the mini-implant in the alveolar mucous membrane to achieve a more intrusive vector. The maxillary sinus is usually present in the upper molar region starting at 8mm distance from the alveolar bone crest and should be avoided during mini-implant insertion. Mini-implant insertion close to the occlusal installation limit (insertion point about 4mm to 5mm above the papilla) is indicated for anterior open bite cases. This installation can be combined with the use of long hooks in the anterior region to enhance anterior open bite closure in cases where increased incisor exposure is possible. Interme-

diate height installation (insertion point about 6mm to 8mm above the papilla) is desirable for individuals who present with a normal or slightly increased overbite. In most retractions, orthodontists normally wish to maintain frontal occlusal plane inclination. For this purpose, it is important to install the mini-implants at the same height on both sides since different heights could generate an uneven occlusal plane in the anterior segment (Fig. 9). It is advisable to measure the distance between the orthodontic archwire and the perforation on one side, and then replicate such distance in the opposite side. The same installation angle for both mini-implants is also recommended so that their extremities can remain equidistant in relation to the archwire. In planning mini-implant installation height, in angular insertions, it should be noted that the mini-implant extremities will be more occlusal than the perforation mark. Therefore, the perforation point should be marked more cervically than the point planned as force vector source.

For individuals who present with an inclined frontal occlusal plane it is advisable to install mini-implants at different heights, thereby generating a force vector with a more intrusive component in one side in order to improve or straighten out the altered plane's inclination. Should the occlusal plane inclination also reach as far as the posterior segment, an elastic module can be con-

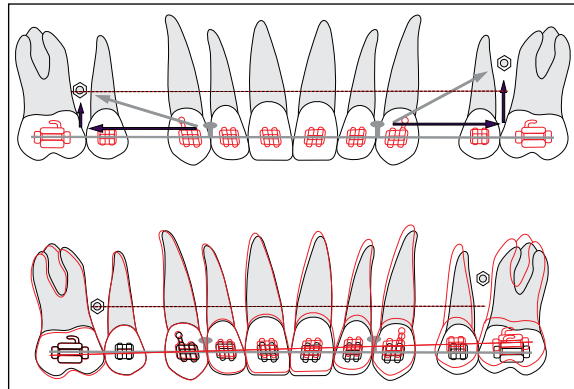


FIGURE 9 - Different vertical positioning of mini-implants can generate an uneven occlusal plane in the anterior segment.

nected from the mini-implant to the archwire in the region where molars may require intrusion, but one should be careful to control a proclination tendency caused by the intrusive force.

For anterior retraction with indirect anchorage the mini-implant installation height is not as crucial as in direct anchorage since the mini-implant's role will be only to stabilize posterior elements while the orthodontist is likely to use the same biomechanics used in conventional treatments. Indirect anchorage has the advantage of exerting little impact on retraction force vectors. However, if the mini-implant begins to show certain mobility, the teeth comprised in the anchorage unit may also move.

### Force application point<sup>5,8,21</sup>

In sliding mechanics, hooks are used on the archwire as force application points to achieve anterior retraction. These hooks can be crimped, screwed on, soldered to the archwire with silver solder or welded; auxiliary appliance hooks can also be used as well as power arms, which can be bonded directly onto teeth. Prefabricated hooks are available for different heights (Fig. 11) and soldered hooks can be customized for each specific case (Fig. 12).

Hook height plays a fundamental part in de-

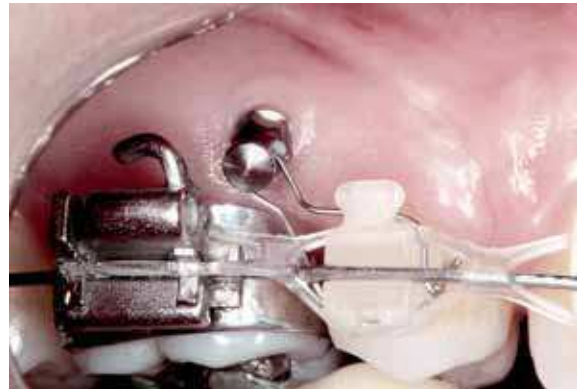

FIGURE 10 - Indirect anchorage for anterior retraction.

termining the force action line. Shorter hooks tend to generate more intrusive force vectors in the anterior region.

One can choose to install hooks towards the occlusal, shift them from cuspid mesial to cuspid distal, thereby strengthening even further the intrusive vector acting on the dental elements in that region. (Fig. 13A) Intermediate height hooks are used when one does not wish to make any alterations to the occlusal plane or little vertical modification in the anterior region (Fig. 13B).

In anterior open bite cases, the use of longer hooks is suggested in order to prevent any intrusive vector from acting on the incisors or to provide these with an extrusive vector (Fig. 13C). Esthetic concerns and the depth of the vestibule, however, limit hook height. These limitations can be overcome by soldering hooks on the cuspids via the palatal region and performing a retraction with the aid of mini-implants inserted in the palatal alveolar process between the first and second upper molars. To help in the anterior retraction of patients who present with frontal occlusal plane inclination, orthodontists can use a shorter hook in the side where a greater anterior intrusion is desired.

Some hook height variation can also be employed to compensate for an unexpected asym-

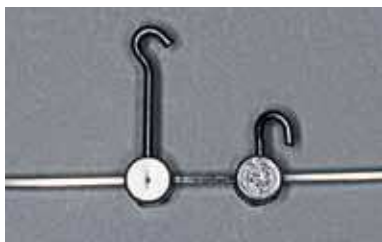


FIGURE 11 - Illustration of two prefabricated screw-on hooks of different heights.

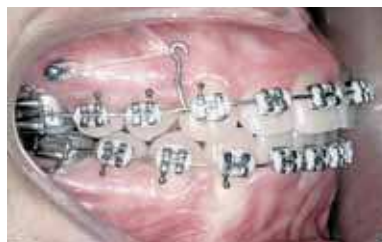

FIGURE 12 - Machine welded long hook used in anterior retraction, with a slightly extrusive force action line on the upper incisors.

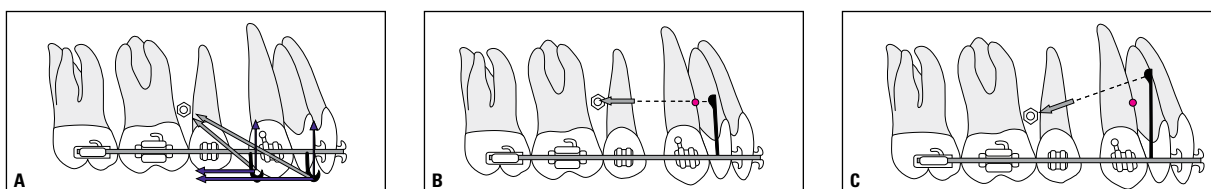


FIGURE 13 - Different hook installation heights generate different force vectors for anterior retraction.

metrical mini-implant installation. This is achieved by installing a shorter hook in the side where the mini-implant was inserted closer to the occlusal and a longer hook where the mini-implant was positioned more towards the apical, thereby keeping similar force vectors on both sides. It should be noted that, as the anterior retraction progresses, the force application point (hook) gets closer to the mini-implant while the force action line becomes increasingly vertical, generating more intrusive force vectors on the incisors. The need may arise to increase hook height during the anterior retraction phase to achieve a force action line as parallel as possible to the occlusal plane (Fig. 14). In specific cases, where one wishes to reduce the time length of orthodontic fixed appliance utilization, a removable acetate plate can be used as anterior retraction support (Fig. 15). This alternative approach involves a treatment with bicuspid extractions and a partial or total closure of extraction space through the use of a plate with a hook placed next to the anterior teeth's center of resistance. This alternative method should prove more convenient for patients with increased inci-

sor inclination, increased cuspid tipping, decreased overbite and slight anterior region crowding.

### Incisor buccolingual inclination

An object will respond with a rotational movement every time a force is applied to it without going through the center of resistance (CR). The same phenomenon tends to occur with teeth in the retraction phase since the force action line usually travels more occlusally than the anterior teeth's CR, causing a side effect which leads these dental elements to incline towards the palatal or lingual regions<sup>20</sup>.

In order to avert this tendency to incline, a moment of force can be applied against the direction of the retraction force by means of buccal torque on the crown or compensatory bends on the archwire. Depending on the force/moment present in the retraction an uncontrolled inclination movement, controlled inclination, "en-mass" movement or root movement may occur.

Uncontrolled tipping will continue to occur as long as the slack between the archwire and the bracket slot is not eliminated<sup>20</sup>. In the anterior

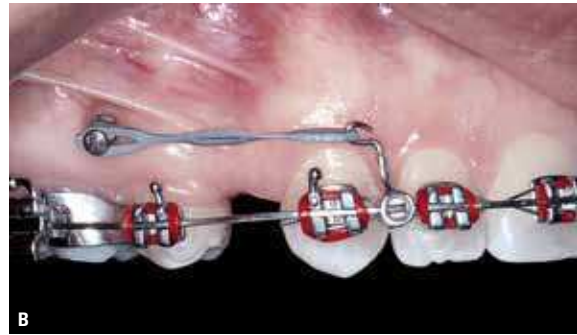
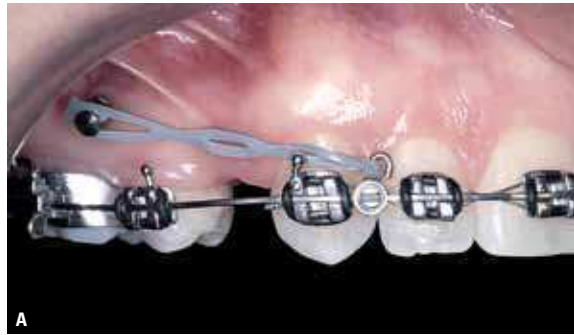


FIGURE 14 - **A)** Retraction with short hook and intrusive force vector on incisors. **B)** Change to long hook: force vector more parallel to occlusal plane.

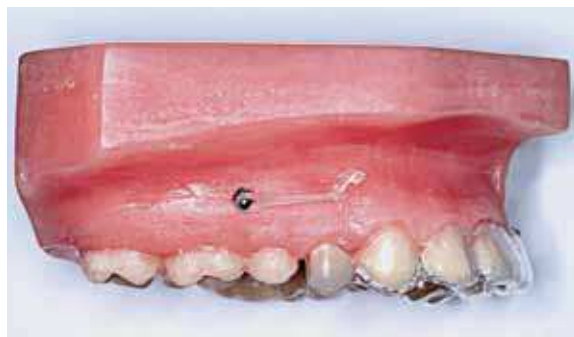

FIGURE 15 - A model illustrating the removable acetate plate with a mockup on the extraction area, used for anterior retraction.

retraction phase a 0.019" x 0.025" stainless steel archwire is recommended for 0.022" x 0.028" brackets. In this system, there is a slack of approximately 10 degrees between the archwire and the bracket slot, which can cause some loss of buccal inclination on the incisors, especially in large retractions<sup>14</sup>. If this happens, the orthodontist will have to apply buccal torque on incisor crowns and a mini-implant anchorage would come in handy to prevent proclination of these dental elements as well as posterior anchorage failure, which tends to occur during the process of anterior torque recovery<sup>8</sup>.

Intrusion forces in the anterior region, when applied in front of the incisors' center of resistance, are likely to increase buccal inclination of these dental elements. These forces can be generated by reverse or accentuated curve archwires, compensatory bends on the archwire or by using

mini-implants inserted between the central incisors to intrude the anterior region during the retraction phase. These resources can be employed whenever the need arises to maintain or enhance the buccal inclination of incisors<sup>8</sup>. On the other hand, in patients presenting with significantly increased incisor inclination and reduced extraction space, one can choose to achieve anterior retraction using a round stainless steel 0.20" or even 0.018" archwire, which enables a quick reduction in the inclination of these teeth. This strategy is particularly efficient in patients who, besides having an increased inclination, also present with anterior open bite since the side effects of palatal inclination and incisor extrusion will make for a favorable scenario<sup>6,10</sup>.

The force action line accomplished by way of mini-implant direct anchorage is likely to exert some impact on the buccolingual inclination of incisors, since the more occlusally positioned this line is found to be relative to the center of resistance of anterior teeth, the greater will be the tendency of incisor inclination towards the palatal or lingual region. Orthodontists, therefore, should be wary of cases involving apically inserted mini-implants in combination with short hooks. With the purpose of bringing the force action line closer to the center of resistance of the incisors it would be advisable to insert 8mm to 10mm mini-implants above the archwire and make use of hooks with 6mm to 8mm of height in the anterior region.

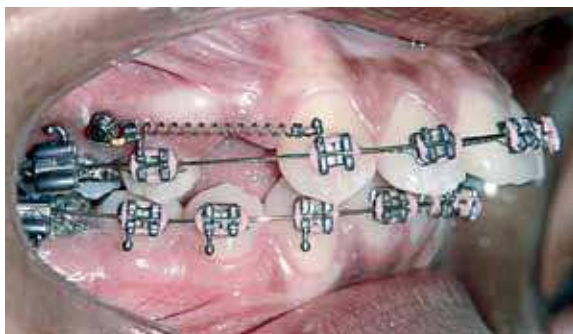


FIGURE 16 - Start of anterior retraction using a round stainless steel archwire for quick incisor inclination correction.

The CR of anterior teeth is located approximately 10mm above and 7mm posterior to the brackets on normally inclined central incisors<sup>5,8</sup>.

Some professionals resort to a mechanical strategy whereby the incisors are allowed to tip towards the palatal region and then later, after space has been closed, they will apply buccal torque to the crown with the purpose of reducing molar anchorage loss during this treatment stage. This approach is not required when using stable mini-implants because anchorage control would no longer be an issue.

### Force applied

Certain treatment philosophies advocate prior cuspid retraction as a means to reduce anchorage loss during anterior retraction. In view of the fact that mini-implants are an efficacious anchorage alternative, prior cuspid retraction, to this end, is rendered unnecessary. Should orthodontists choose to carry out anterior retraction in two stages, they can use mini-implants for cuspid retraction and, subsequently, for incisor retraction. "En-mass" retraction, however, can mean an important time saving treatment tool<sup>1</sup>, in addition to being a more esthetic retraction method since it prevents diastemas between cuspids and lateral incisors.

For "en-mass" retraction, a 150cN to 300cN force is prescribed for each side (1 Newton = 100cN = 102g, therefore 150 to 300cN are equivalent to what orthodontists usually refer to as

150 to 300g, although the appropriate force measure unit is the Newton). This amount of force is sufficient to close 0.5mm to 1.0mm space per month while allowing adequate control of side effects. Stronger forces tend to produce various undesirable side effects and can lead to mini-implant failure. A force gauge should always be used since orthodontists tend to apply more force than they believe they are applying<sup>14</sup>. On average, mini-implants can sustain forces of about 200cN to 400cN. This limit can vary depending on the patient's facial pattern (braquifacials have greater limits), on the type of bone where a mini-implant is inserted (thicker cortical bone offers more resistance) and on mini-implant diameter<sup>3,4,8,17</sup>.

Anterior retraction can be started on the same day of mini-implant insertion since mini-implants owe their stability, in large measure, to mechanical retention and not to osseointegration. In fact, histological evaluations have demonstrated a larger contact area with immediate load mini-implants than with those which were not loaded or which received load after a period of rest<sup>4,8,17</sup>.

In sliding mechanics, retraction activation can be achieved by means of superelastic Nitinol springs, conventional Nitinol springs, elastic modules for retraction (Fig. 17) or chain elastic modules. Superelastic Nitinol springs are the foremost recommendation given their narrower force variation. Special springs are available which can be easily attached to mini-implants (Fig. 18) and some companies have adapted the outer area of mini-implants to accept springs that are available in the market, thereby dispensing altogether with the use of special springs or spring attachments using ligature wire (Fig. 19). Although purportedly superelastic, the force exerted by these springs should be gauged since force intensity varies in tandem with the distance between mini-implant and hook. Usually, 150g or 200g springs are chosen because they generate greater forces than these when fully installed. Should an orthodontist choose to employ elastic modules, excessive initial

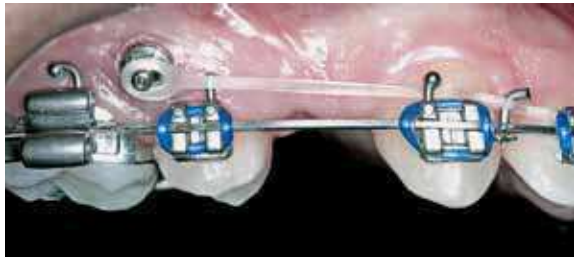


FIGURE 17 - Anterior retraction using an elastic module.




FIGURE 18 - Comparison between Nitinol spring with conventional attachment (A) and spring with special attachment for use with mini-implants (B).

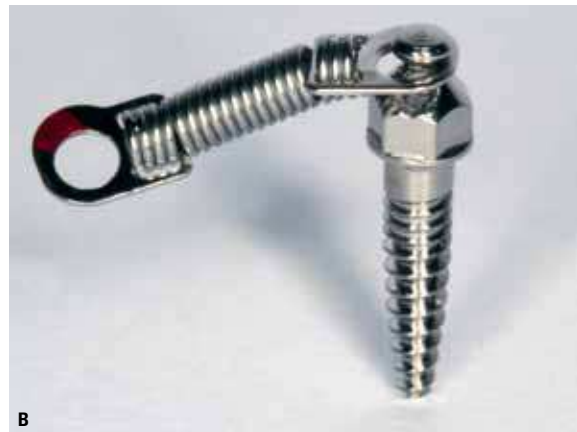
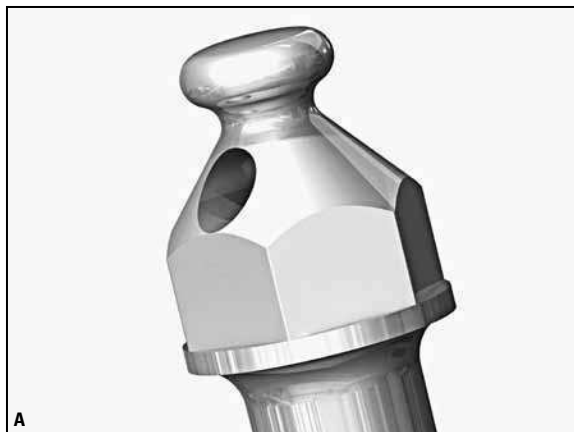
FIGURE 19 - A) Close-up detail of a mini-implant head, duly sized for Nitinol spring attachment. B) Nitinol spring attached directly to the mini-implant head.

forces should be avoided.

Since mini-implants tend to grow increasingly stable with use, as a result of an increase in bone density around it and in response to functional demand (secondary stability), it is advisable to begin retraction with a weaker force than originally planned so as to increase the chances of mini-implant success<sup>15,17</sup>.

### Ideal moment for mini-implant installation

In cases where the need arises for an initial cuspid retraction, mini-implants can be installed at treatment onset to ensure better alignment. Subsequently, the same mini-implant can be used for anterior retraction. Should a mini-implant be required only during the anterior retraction phase,

insertion should be performed after installation of the whole retraction system so that the mini-implant can be used immediately following installation. If the mini-implants are inserted at treatment onset and are used during anterior retraction phase only, they will be exposed to unnecessary risk for several months<sup>13,16,17</sup>.

### KEY MINI-IMPLANT INSTALLATION SITES

Due to their minute diameter, mini-implants can be inserted in a number of different sites to support anterior retraction. It is recommended that orthodontists select two or three potential installation sites taking into account the force vector orientation relative to the center of resistance of anterior teeth. Orthodontists should not underes-

timate the importance of conducting biomechanical planning prior to mini-implant installation. A diagram should be drawn out depicting the force action line and the mechanics to be utilized in different insertion site scenarios. Based on this analysis, orthodontists can pinpoint the best suited site as well as a second or even third installation site option<sup>10,13</sup>.

Periapical and interproximal radiographs of the potential installation sites should be acquired using the paralleling technique and a positioner, with the radiation source running perpendicular to the insertion site. These radiographs will be used to assess the possibility of contact between the mini-implant and relevant anatomical structures and to ascertain that there is adequate embrasure.

For a 1.5mm mini-implant, the recommended minimum interradicular space should be 2.5mm (or 3.5mm for not so experienced professionals). Images acquired through volume computed tomography can be indicated for specific cases.

In the event that interradicular space is not sufficient in the first potential installation site, orthodontists can: 1) choose another installation site; 2) wait until the alignment and levelling phase has ended and the roots should be better positioned with more comfortable interradicular space; 3) make an orthodontic preparation for inserting the mini-implants using typical bonding and segmented archwires to deliberately move away the roots of teeth in the neighborhood of the installation site. Since the anterior retraction phase occurs a few months following treatment onset, orthodontists can easily – from a biomechanical standpoint – prepare the space for mini-implant insertion in the best-suited site.

### Potential installation sites in the upper arch<sup>4,5,7,8,12</sup>

For anterior retraction in the upper arch the installation options, in order of preference, are:

1) Buccal alveolar process between the first

molars and second bicuspid. This is the installation site most often used for anterosuperior retraction with direct anchorage. It can also be used for indirect anchorage by attaching the mini-implant to the second bicuspid. On occasion, this site may not be available due to insufficient space between the roots or an enhanced curvature of the upper first molar mesiobuccal root. In cases of second bicuspid exodontia it is advisable to assess the thickness of the bone crest mesial to the molar and, in the event of insufficient space, some other site is indicated;

2) Palatal alveolar process between the first and second molars. This is usually utilized for indirect anchorage by attaching the mini-implants to the first molars and using a transpalatal bar to prevent the mesial rotation of the first molar (Fig. 20). This is the site of choice for anterior retraction with fixed lingual appliances. This region normally features sufficient interradicular space, although insertion access is significantly compromised in comparison with the buccal alveolar process, requiring, therefore, the use of an angle piece or digital key. This region also features greater mucous membrane thickness, which has an unfavorable impact on mini-implant placement since it moves the mini-implant's external point away from the cortical bone. Prior to installing in this area, gingiva thickness should be measured in order to determine an appropriate extension for the transmucous profile and total mini-implant length. The transmucous profile extension (smooth area on the mini-implant) should approximately match soft tissue thickness and the mini-implant should be inserted into the bone at about 6mm to 8mm depth;

3) Buccal alveolar process between the first and second molars. This is used most often for indirect anchorage by attaching the mini-implants to the first permanent molars with ligature wire. This region does not usually feature enough interradicular space but this should be evaluated on a case by case basis (Fig. 21);

4) Maxillary tuberosity region. Ligature wire is used to connect the mini-implant to the first and second molars for an indirect anchorage (Fig. 22). This area features less dense bone and in order to attain greater stability the use of a longer, thicker mini-implant is strongly recommended;

5) Between the buccal roots of the first permanent molars. One can resort to this option in atypical cases where molars present with rather divergent buccal roots and other sites are not available;

6) Mid-palatal suture (or next to the suture in young patients). Used most often for indirect anchorage, thereby stabilizing molars by means of a transpalatal bar either tied or bonded to the mini-implants. When the bar is attached to the mini-implant by means of ligature wire, molar control is reduced. Therefore, molars will tend to

tip towards the mesial in response to the anterior retraction force. When a transpalatal bar is bonded with composite resin to the mini-implant head, control of molar position is enhanced. The masticatory load, however, is conveyed to the mini-implants, which can loosen or even cause the failure of these devices. Therefore, this type of indirect anchorage has not proved hitherto as efficient as other methods mentioned above. Mini-implants with bracket shaped extremities and with left and right threading, have rendered this installation site more versatile and favorable.

### Potential installation sites in the lower arch<sup>5,8,12</sup>

1) Buccal alveolar process between the first and second molars. This area typically features greater interradicular space and greater cortical bone thickness in the lower arch. Ligature wire can be used to stabilize the first molars and mini-implants can be used for indirect anchorage (Fig. 23).

2) Buccal alveolar process between the second bicuspid and first molars (Fig. 24) for anterior retraction using direct anchorage.

3) Second molar distal region (Fig. 25) or retromolar region (Fig. 26) for the use of indirect anchorage.

Table 1 provides suggestions for choosing mini-implant models according to insertion site.

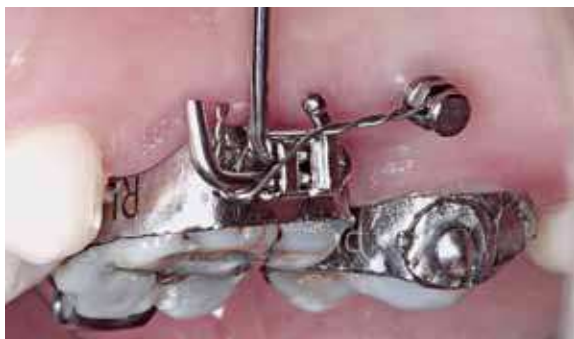

FIGURE 20 - Indirect anchorage with mini-implant attached to the first molar's transpalatal bar tube using ligature wire.

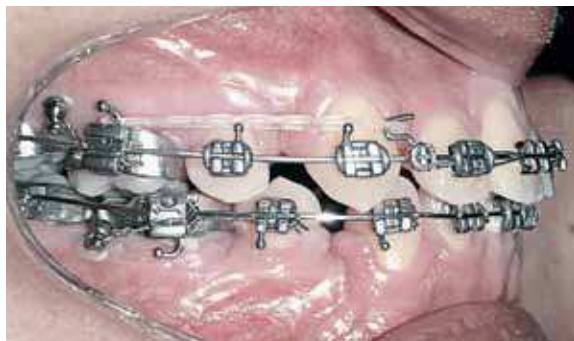

FIGURE 21 - Illustration of mini-implants being used for indirect anchorage, inserted between the first and second molars.

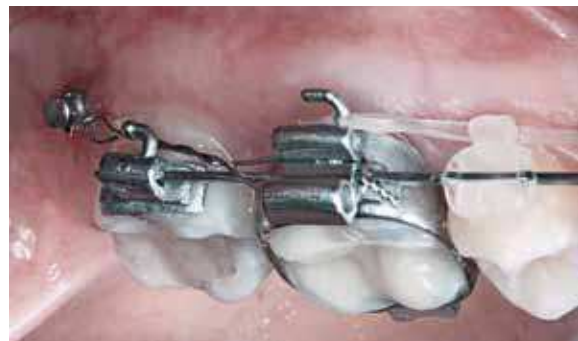

FIGURE 22 - Indirect anchorage with mini-implant inserted into the maxillary tuberosity.

## ANTERIOR RETRACTION CONTROL

Even with adequate biomechanical planning, drawbacks and undesirable side effects can arise during the anterior retraction stage. For a successful treatment in this phase, orthodontists are advised to control the following factors.

### Peri-implant region control

It is important to check, at every appointment, the condition of the tissues surrounding the mini-implants and raise the patient's awareness as to how important it is to adequately brush this area since infection and peri-implant inflammation can cause mini-implant failure. In the event of mechanical cleaning difficulties, it is recommended that the brush be dipped into a 0.12% clorexidine

gluconate solution or, preferably, into a 0.2% clorexidine digluconate gel, and apply this solution or gel around the mini-implant<sup>9,11,13</sup>.

### Mini-implant stability

In the event of a slight mini-implant drift, without mobility and with no contact with essential structures, the same mini-implant can be used for retraction. In cases where slight mobility is present, the mini-implant should be tightened by a  $\frac{1}{2}$  diameter or one full diameter and kept under moderate force only. If this adjustment is not carried out, mobility will likely be worse by the following appointment. In cases where there is excessive drift or mobility, the mini-implant should be removed and another one inserted in an alternative site<sup>13</sup>.

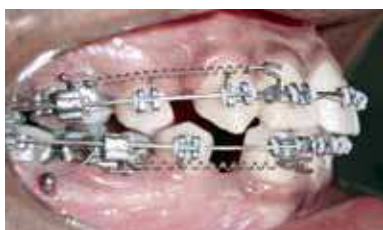

FIGURE 23 - Indirect anchorage for anteroinferior retraction.



FIGURE 24 - Installation site for anterior retraction with direct anchorage.

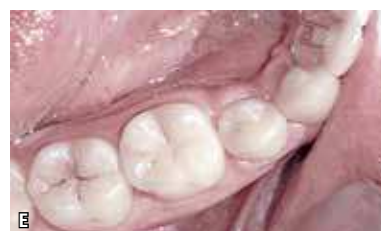
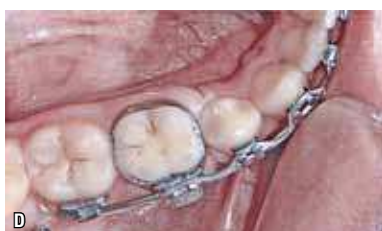
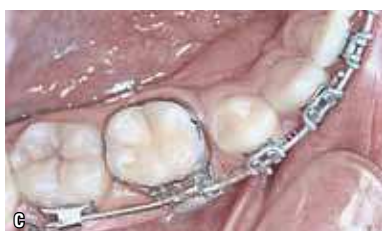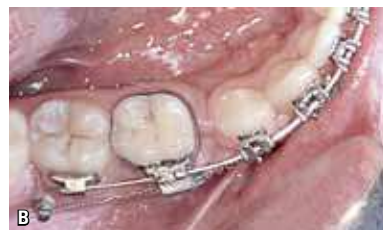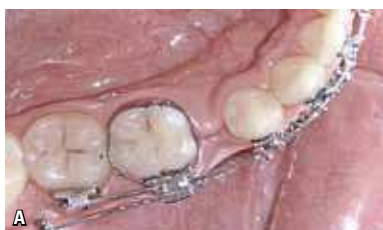FIGURE 25 - **A)** Beginning of incisor, cuspid and bicuspid retraction using mini-implant indirect anchorage. **B)** Progress of "en-mass" anterior retraction using indirect anchorage. **C)** Near the end of the anterior retraction phase. **D)** Anterior "en-mass" retraction completed without any regard for anchorage. **E)** Final photo.

### Frontal occlusal plane inclination

By periodically assessing the patient's frontal aspect, either through a clinical examination or frontal smiling photographs, one should ensure no frontal occlusal plane inclination is taking place during retraction. Particular attention should be paid to the treatment of individuals presenting with unilateral extraction or bilateral extractions where a mini-implant will be used in one side only. In these cases, the retraction on the mini-implant side tends to generate a force action line that differs from the opposite side, thereby tipping the frontal occlusal plane. In order to avoid any side effects, it is suggested that the anterior retraction be conducted using a force action line in parallel to the occlusal plane<sup>2,8,9</sup>. In the event that this plane alteration has already occurred, the orthodontist can use asymmetrical hooks to help in solving the problem (Fig. 27).

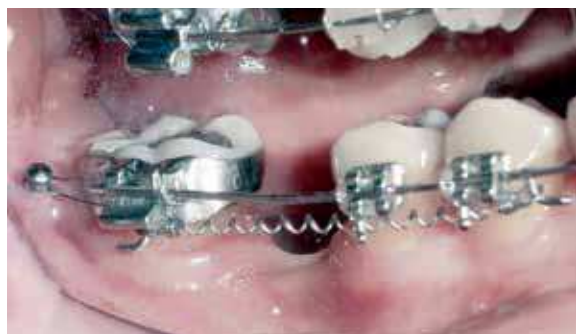

FIGURE 26 - Mini-implant inserted in the retromolar region and being used as indirect anchorage for "en-mass" retraction.

### Attrition between archwire and brackets

When performing sliding mechanics space closure it is important to verify, at the start of the retraction, whether there is significant attrition between archwire and posterior segment brackets. Should this be the case, in addition to the anterior retraction, there could be posterior segment distalization and intrusion (Fig. 28) or, on occasion, mini-implant failure due to the excessive force deployed to move all teeth. Should there be significant attrition, it is recommended that the posterior segment archwire be abraded to benefit the sliding mechanics<sup>8,14</sup>.

### Lateral bite opening control

During the space closure phase, there is a tendency for the bicuspid region to undergo open bite due to archwire deflection, which can lead to the distal tipping of the cuspid crown and mesial tipping of molars and bicusps. The greater the retraction force and the more flexible the archwire, the greater the tendency towards lateral open bite. In order to avert these side effects, it is recommended that the force be controlled, flexible archwires be utilized, a reverse curve archwire be used in the lower arch, and an accentuated archwire be used in the upper arch during the space closure phase<sup>8,14</sup>. Whenever mini-implants are used, the reverse curve or accentuated curve archwire should be made less deep and should not stand out so much on the posterior segments as is

**Table 1** - Initial protocol for choosing orthodontic mini-implants. The suggested averages are those most often used. It is advisable, however, to check the interradicular space and the presence of anatomical structures such as maxillary sinus, palatal artery and mandibular nerve. It is also necessary to check the attached gingiva or alveolar mucous membrane and the bone density prior to a final choice of mini-implant.

	Region	Diameter	Active threading	Transmucous profile	Angulation
1	anterior buccal maxilla or mandible	1,5mm	6mm	1mm	60° a 90°
2	posterior buccal maxilla	1,5mm	6mm	1mm	30° a 60°
3	posterior palatal maxilla	1,8mm	6mm	2mm	30° a 60°
4	mid-palatal suture	2,0mm	6mm	1mm	90° a 110°
5	posterior buccal mandible	1,5mm	6mm	1mm	30° a 60°
6	edentulous, retromolar or tuberosity area	2,0mm	8mm	2mm	90°

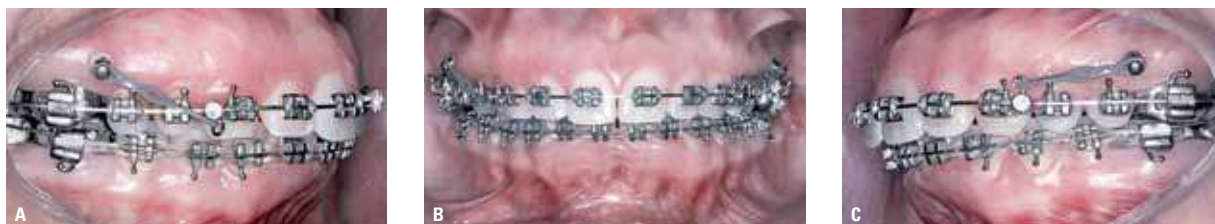

FIGURE 27 - **A)** Hook directed towards the occlusal and installed on the cuspid's distal region to enhance the intrusive vector with the purpose of helping to correct occlusal plane inclination. **B)** Frontal view of the anterior retraction with asymmetrical force vectors. **C)** Distal retraction on the left with a less intrusive vector than on the right.

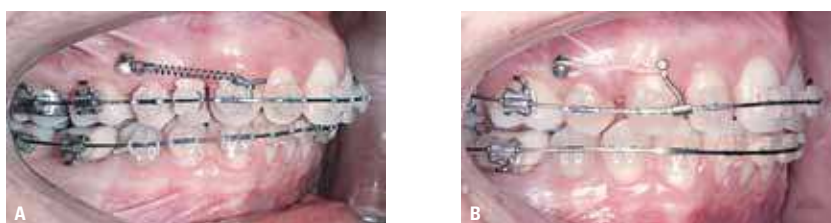


FIGURE 28 - **A)** Anterior retraction phase without a proper evaluation of the attrition, involving the archwire and the brackets on the posterior teeth. **B)** Side effect caused by the distalization of the posterior segment as a result of archwire attrition.

the case in traditional mechanics. Otherwise, molars will tend to intrude and, consequently, undergo proclination (as a result of the intrusive force impinging buccally on the molars' CR).

### Overbite control

Overbites tend to increase during the anterior retraction phase. To such an extent that, towards treatment completion, the incisal edge of the lower incisors may touch the upper incisors' palatal region. In these cases it does not help to increase the retraction force. It will be necessary to correct the overbite prior to proceeding to the space closure phase (Fig. 29).

Force increase may lead to the mini-implant drifting or might even result in mini-implant failure. To help in correcting the overbite, the orthodontist can increase the amount of reverse or accentuated curve and, if necessary, bend intrusion steps on the archwire. It is convenient to reassess the force in use and check whether there has been any loss of buccal tipping on the anterior teeth<sup>14</sup>.

### Control of buccolingual tipping on incisors

The orthodontist may notice a decrease in

buccolingual inclination, above and beyond what was expected, during the space closure phase. Should this happen, it will be necessary to reduce the retraction force and add buccal torque to the archwire in the incisor region.

Those orthodontists who make use of preadjusted appliances featuring additional anterior torque – Roth prescription, for example, applies +12° buccal torque and MBT has +17° buccal torque on central incisors instead of the standard 7° - can choose to use a thicker archwire instead of adding torque to the archwire. 0.021" x 0.025" archwires have a slight 2° slack inside a 0.022" slot, which will enable a better expression of the torque built into the brackets and afford greater incisor tipping control.

For individuals with increased overbite, it would be a good idea to increase the amount of reverse or accentuated curve, imparting increased torque to the incisor region and helping to control the loss of buccal inclination which tends to occur during retraction<sup>14</sup>.

### Cuspid angulation and rotation control

During the space closure phase cuspids tend

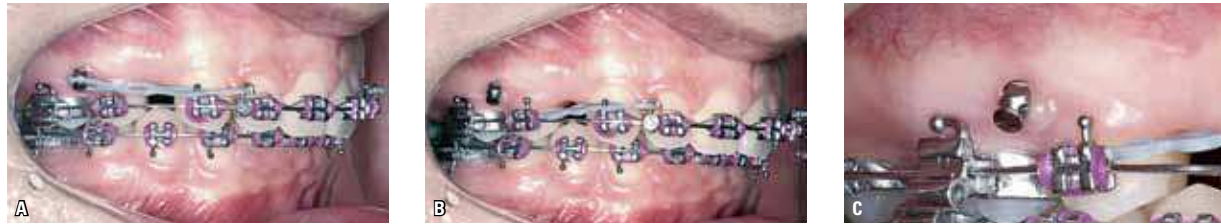

FIGURE 29 - **A)** Retraction with inappropriate overbite and force. **B)** Alterations to the gingival tissue on the mesial region of the mini-implant due to excessive force. **C)** Close-up view of a higher degree of gingival alteration on the mini-implant's mesial side.

to rotate distally, which tends to contract the archwire in the bicuspid region when not so stiff archwires are employed. It is recommended that stainless steel ligature wire be used on cuspids to prevent them from rotating distally. During anterior retraction, one should also control cuspid proneness to tip distally, which can lead to incisor extrusion, overbite increase and occlusal plane alteration. These side effects can be controlled with the use of stiff stainless steel archwires and reverse or accentuated curve archwires<sup>8</sup>.

### Midline control

Should it become necessary to correct a midline shift during the space closure phase, it is advisable to use a longer hook on the side where the midline is to be corrected. This longer hook, combined with a mini-implant inserted at an intermediate or apical height will generate a force action line closer to the center of resistance of the incisor, thus facilitating their movement and preventing crown tipping alone, which tends to occur when sliding mechanics is applied using short hooks<sup>8</sup>.

### Space closure difficulties

Certain situations should be monitored which are likely to hinder anterior retraction and cause excessive force on mini-implants. In addition to the aforementioned archwire attrition and increased overbite, the following are also worthy of note: Contact between upper and lower cuspid cusps; torque or bends on the archwire which may hamper distal sliding; gingival tissue trapped

in the extraction space due to fast space closure; contact between cuspid roots and the buccal cortical bone region in patients who present with a narrow alveolar process in this region; contact between the cuspid root and the second bicuspid root due to laceration or inadequate tipping of the cuspid and/or second bicuspid root<sup>1,14</sup>.

## CLINICAL CONSIDERATIONS

### Space closure stabilization

Following anterior retraction the mini-implants can be used to stabilize space closure by connecting these devices with the archwire hook using ligature wire (Fig. 30). In the event that the archwire used during this space closure phase has been abraded to facilitate sliding mechanics, a brand new archwire should be installed to achieve proper root positioning. The maintenance of this archwire for three months after completion of the anterior retraction will prevent extraction spaces from reopening after treatment<sup>14</sup>.

### Sliding mechanics retraction X loop mechanics

Mini-implants can be used during the anterior retraction phase in combination with straight archwires or loops, depending on the orthodontist's preference. Retraction mechanics with the use of loops (Fig. 31) enables the incorporation of first, second or third order bends to adjust tooth position in the posterior segment without impairing space closure. On the other hand, sliding mechanics allows easier archwire formation, a more predictable movement and, at times, better

esthetics, since it precludes the use of loops in the anterior segment<sup>1,5,9</sup>.

### Total retraction

Anterior retraction can be performed in conjunction with posterior segment dental elements in a type of retraction which could be named total retraction. This mechanics is recommended for individuals who present with a discreet biprotrusion or an anteroposterior 2mm to 3,5mm discrepancy between dental arches. To this end, mini-implants can be inserted between the roots of upper bicuspids and molars as well as between lower molar if there is sufficient interradicular space (Fig. 32). Other individuals may have an increased bone volume which allows the insertion of angled mini-implants buccally, relative to the tooth roots. Another alternative mini-implant installation for total retraction is the tuberosity region in the maxilla and the retromolar region in the mandible<sup>5,6,9,19,20</sup>.

### Mini-implants X Tweed-Merrifield mechanics

The combination of high mini-implants with

short hooks yields similar effects to those produced by J-hook retraction, used in traditional mechanics, such as Tweed-Merrifield, although a mini-implant retraction can retract cuspids and incisors in one go, thereby reducing treatment time. The use of mini-implants dispenses with the need for tip-back bends, which averts the extrusive effect often caused by anchorage preparation on posterior teeth. Additionally, mini-implants can also be used for posterior vertical control while concurrently being utilized to provide support for anterior retraction by intruding molars with elastics connected to the mini-implants. This biomechanics differentiation can prove relevant for retrognathic mandible patients with an increased lower face third, since any lower molar intrusion achieved with the help of mini-implants can produce a counterclockwise mandibular movement (Fig. 33), reducing cuspid and molar Class II, and may require an anterosuperior retraction and anteroinferior face height adjustment, which may bring about a greater projection of the mentum and an improved face profile<sup>20</sup>.

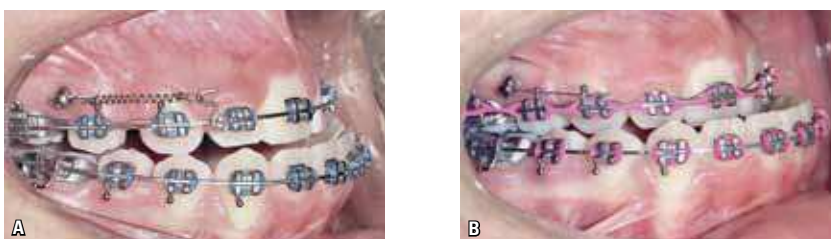


FIGURE 30 - **A)** Ortho-surgical case using mini-implants to enhance anterosuperior retraction. **B)** Space closure stabilization using ligature wire to connect mini-implants to upper molars.



FIGURE 31 - Anterior retraction with loop mechanics.

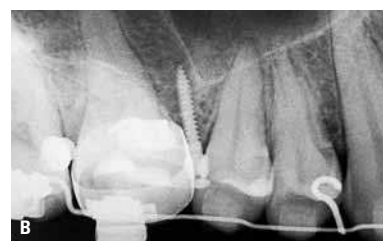
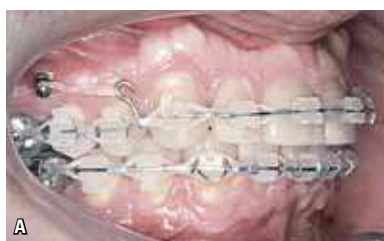
FIGURE 32 - **A)** Mini-implant being used for total retraction on the upper arch. **B)** Periapical radiographic image showing sufficient space between roots as to allow a total retraction.

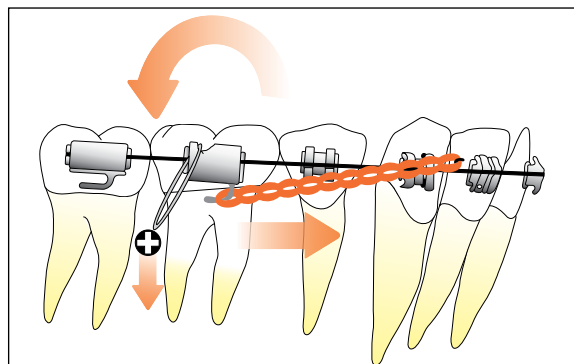


FIGURE 33 - Anteroinferior retraction combined with lower molars intrusion generating a counterclockwise mandibular rotation.

Submitted: March 2008

Revised and accepted for publication: May 2008

## CONCLUSION

Mini-implants can contribute significantly to the anterior retraction phase. Orthodontists, however, should acquaint themselves with the peculiarities of using mini-implants in this treatment stage. If used appropriately, mini-implants can be more efficient than traditional anchorage methods besides making treatments more predictable.

## ACKNOWLEDGEMENTS

For their invaluable assistance in writing this article, I would like to thank Paulo and Zelna Marassi; Patrícia M. Marassi, Mirella Ferraz; Wagner Luz; Orlando Chianelli; Paulo César Nery; André Leal and the entire Marassi Ortodontia Clinic team.

## REFERENCES

1. ARAUJO, T. Ancoragem esquelética com mini-implantes. In: LIMA FILHO, R. M. A.; BOLOGNESE, A. M. **Ortodontia: arte e ciência**. Maringá: Dental Press, 2007. p. 393-446.
2. CARANO, A. et al. Clinical applications of the miniscrew anchorage system. **J. Clin. Orthod.**, Boulder, v. 39, no. 1, p. 9-24, 2005.
3. DEGUCHI, T. et al. Quantitative evaluation of cortical bone thickness with computed tomographic scanning for orthodontic implants. **Am. J. Orthod. Dentofacial Orthop.**, St. Louis, v. 129, no. 6, p. 721, 2006.
4. FAVERO, L.; BROLLO, P.; BRESSAN, E. Orthodontic anchorage with specific fixture: related study analysis. **Am. J. Orthod. Dentofacial Orthop.**, St. Louis, v. 122, no. 1, p. 84-94, 2002.
5. KYUNG, H. M. et al. **Mini-implantes**. Nova Odessa: Ed. Napoleão, 2007.
6. KYUNG, H. M. et al. Development of orthodontic micro-implants for intraoral anchorage. **J. Clin. Orthod.**, Boulder, v. 37, no. 6, p. 321-328, 2003.
7. LEE, J. S.; PARK, H. S.; KYUNG, H. M. Micro-implant anchorage for lingual treatment of a skeletal Class II malocclusion. **J. Clin. Orthod.**, Boulder, v. 35, no. 10, p. 643-647, 2001.
8. LEE, J. S. et al. **Applications of orthodontic mini-implants**. Chicago: Quintessence, 2007.
9. MARASSI, C. et al. Clinical applications of mini-screws as anchorage. In: AMERICAN ASSOCIATION OF ORTHODONTISTS, 104th, 2004, Orlando. **Annual Session...** Orlando: American Association of Orthodontists, 2004.
10. MARASSI, C. et al. O uso de mini-implantes como método auxiliar do tratamento ortodôntico. **Ortodontia**, São Paulo, v. 38, n. 3, p. 256-265, 2005.
11. MARASSI, C.; LEAL, A.; HERDY, J. L. Mini-implantes como método de ancoragem em Ortodontia. In: SAKAI, E. et al. **Nova visão em Ortodontia: Ortopedia Funcional dos Maxilares**. 3. ed. São Paulo: Ed. Santos, 2004. p. 967-974.
12. MARASSI, C. Carlo Marassi responde (parte I): Quais as principais aplicações clínicas e quais as chaves para o sucesso no uso de mini-implantes em Ortodontia? **Rev. Clin. Ortodon. Dental Press.**, Maringá, v. 5, n. 4, p. 13-25, ago./set. 2006. (Entrevistadora: Rosely Suguino).
13. MARASSI, C. Carlo Marassi responde (parte II): Quais as principais aplicações clínicas e quais as chaves para o sucesso no uso dos mini-implantes em Ortodontia? **Rev. Clin. Ortodon. Dental Press.**, Maringá, v. 5, n. 5, p. 14-26, out./nov. 2006. (Entrevistadora: Rosely Suguino).
14. MCLAUGHLIN, R. P. **Mecânica sistematizada de tratamento ortodôntico**. São Paulo: Artes Médicas, 2001.
15. MELSEN, B.; VERNA, C. Miniscrew implants: the archus anchorage system. **Semin. Orthod.**, Philadelphia, v. 11, no. 1, p. 24-31, 2005.
16. MIYAWAKI, S. et al. Factors associated with the stability of titanium screw placed in the posterior region for orthodontic anchorage. **Am. J. Orthod. Dentofacial Orthop.**, St. Louis, v. 124, no. 4, p. 373-378, 2003.
17. OHMAE, M. et al. A clinical and histological evaluation of titanium mini-implants as anchors for orthodontic intrusion in the big dog. **Am. J. Orthod. Dentofacial Orthop.**, St. Louis, v. 119, no. 5, p. 489-497, 2001.
18. PAK, C. H.; WOO, Y. J.; BOYD, R. L. Treatment of an adult patient with vertical maxillary excess using miniscrew fixation. **J. Clin. Orthod.**, Boulder, v. 37, no. 8, p. 423-428, 2003.
19. PARK, H. S. et al. Simultaneous incisor retraction distal molar movement with microimplant anchorage. **World J. Orthod.**, Carol Stream, v. 5, no. 2, p. 1-8, 2004.
20. PARK, H. S. et al. **The orthodontic treatment using micro-implant**. Seoul: Deahan, 2001.
21. PARK, Y. C. et al. Extraction space closure with vacuum-formed splints and miniscrew anchorage. **J. Clin. Orthod.**, Boulder, v. 39, no. 2, p. 76-79, 2005.

### Contact address:

Carlo Marassi  
Av. das Américas, 4790 Sala 526 - Barra da Tijuca  
CEP: 22.640-102 - Rio de Janeiro  
E-mail: marassi@ortodontista.com

