

# Condylar hyperactivity: Diagnosis and treatment - case reports

Maria Christina Thomé Pacheco\*, Robson Almeida de Rezende\*\*, Rossiene Motta Bertollo\*\*\*, Gabriela Mayrink Gonçalves\*\*\*\*, Anita Sanches Matos Santos\*\*\*\*

## Abstract

**Introduction:** Condylar hyperactivity is a condition triggered by an imbalance in bone growth factors, which causes facial asymmetry. It can be classified into three different types: hemimandibular hyperplasia (HH), hemimandibular elongation (HE) and a hybrid form. It is essential that a correct diagnosis of these hyperactivities be reached since each type of anomaly requires a different approach. Treatment options include surgery and high condylectomy. **Objectives:** The purpose of this article is to present two cases of facial asymmetry caused by condylar hyperactivity, showing the importance of an accurate diagnosis and the means used to achieve it while seeking an appropriate treatment for each case.

**Keywords:** Maxillomandibular anomalies. Facial asymmetry. Condylar hyperplasia.

## INTRODUCTION

Skeletal asymmetries of the mandible caused by condylar hyperactivity can pose serious functional, esthetic and psychosocial problems for patients. Although their etiology is still unknown, some authors believe they can be caused by trauma, inflammation, hypervascularity, genetic factors and hormonal disorder.<sup>4,7,11,13</sup>

Several classifications are available. Some are etiology-related while others divide these anomalies according to the growth factors involved in its development. Asymmetries can therefore be acquired or developmental, and since each situation presents with different features a differential diagnosis can be more easily established. Acquired asymmetries involve pain, symptom changes, alterations in facial appearance and

function with time. The volume of facial muscles remains unchanged. Other features include TMJ crepitation (crackling/popping sounds), limited mandibular movements (rotation, protrusion and mouth opening), severe crossbite and irregular condyle anatomy. Developmental changes do not involve pain, symptoms usually remain unchanged over time, changes may occur in the size or function of the facial muscles, no functional changes take place in the TMJ, there may be limited protrusion without limiting mandibular rotation movements, a pronounced dental compensation in the asymmetric mandible may be present and the condyle remains pronounced and smooth, even in the presence of volumetric changes.<sup>15</sup>

According to Obwegeser and Makek,<sup>13</sup> hy-

\* PhD in Orthodontics, Federal University of Rio de Janeiro (UFRJ). Professor of Orthodontics, Federal University of Espírito Santo, Vitória, Espírito Santo State.

\*\* MSc in Oral and Maxillofacial Surgery, PUC-RS. Professor of Oral and Maxillofacial Surgery I and Oromaxillofacial Prosthesis and Traumatology, Federal University of Espírito Santo.

\*\*\* MSc in Oral and Maxillofacial Surgery and Traumatology, PUC-RS. Substitute Professor of Oral and Maxillofacial Surgery II, Federal University of Espírito Santo.

\*\*\*\* Dentistry graduate, Federal University of Espírito Santo.

peractivity can be classified into three different types: hemimandibular hyperplasia (HH), hemimandibular elongation (HE) and a hybrid form. Many authors use the term condylar hyperplasia to refer to these three forms, but this is not appropriate, since it is only in HH and hybrid cases that a true condylar hyperplasia is found.

Condylar hyperactivity is common to these three forms and occurs primarily due to an imbalance in the growth regulatory factors located in the cartilaginous layer of the condyle. One such factor is responsible for height growth (Factor L), and manifests itself in hemimandibular elongation; the other factor is responsible for bone mass growth (Factor M) and remains active in hemimandibular hyperplasia.<sup>12</sup>

Hemimandibular elongation may occur as an extension of the condyle or ramus in the vertical plane, or as an extension of the body in the horizontal plane. Combined vertical and horizontal elongations are possible.<sup>9</sup> Their main clinical feature are an elongation of one side of the mandible with no increase in bone mass production. Both the chin and the midline of the lower teeth are shifted to the side opposite to the elongation and, typically, a crossbite is also present. The teeth on the affected side are usually in infra-occlusion when compared with the teeth on the opposite side.<sup>16</sup> A flattening of the gonial angle in the affected side can also be observed.<sup>9,12,16</sup> Typically, elongation stabilizes when patients cease to grow.

Hemimandibular hyperplasia is characterized by a three-dimensional increase in the affected side of the mandible extending to the symphysis region.<sup>2,12</sup> Its major characteristics are: lower border of the mandible on the affected side positioned further down when compared with the contralateral side; increased distance between tooth apices and mandibular canal.<sup>2,12</sup> An inclination of the occlusal plane and rima oris on the affected side can also be observed. Depending on the stage in which

asymmetry development occurs it may cause maxillary inclination in response to mandibular growth.<sup>2</sup> Otherwise, there will be unilateral posterior open bite.<sup>13</sup> The dental midline is usually shifted to the malformed side. The gonial angle is either normal or more acute<sup>16</sup> and, in general, a growth period elapses after the patient's asymmetric growth is completed.

The hybrid form can produce the strangest forms of facial and mandibular asymmetry. The condyle may have an increased bone mass, there may be a crossbite, chin deviation toward the opposite side and a vertical increase in the affected hemimandible, creating an oblique occlusal plane. Different signs will emerge depending on which growth factor is being activated.<sup>12</sup>

It is important that clinicians learn to identify such hyperactivities because development time, dentoalveolar compensation and the likelihood of an intervention achieving success are different for each type of anomaly.<sup>9</sup>

Diagnosis must be based on anamnesis, an evaluation of previous medical and dental history, clinical examination, model analysis, complementary tests such as computed tomography and bone scintigraphy.<sup>6,14,16</sup>

The purpose of this article is to present two cases of facial asymmetry caused by condylar hyperactivity, showing the importance of an accurate diagnosis while seeking an appropriate treatment for each case.

## CASE REPORT

### Case 1

A female Caucasian patient, aged 17, sought orthodontic treatment with the chief complaint of asymmetrical facial growth, which made her different from her identical (monozygotic) twin sister. No history of trauma or asymmetry cases in the family were reported. She presented with a swelling in the left side of the mandible, chin deviation to the opposite side, posterior open bite on

the left side and inclined maxillary occlusal plane (Fig 1). Radiographs showed a three-dimensional increase of the hemimandible and an increase in distance between root apices and mandibular canal (Figs 2, 3 and 4). Bone scintigraphy showed active growth of the left condyle (Fig 5). Through the association of clinical and imaging features we

concluded that this was a case of condylar hyperactivity of the hemimandibular hyperplasia type. Treatment comprised presurgical orthodontic preparation, orthognathic surgery (upper maxillary repositioning and reduction of body, ramus and gonial angle height) and high condylectomy with external access.

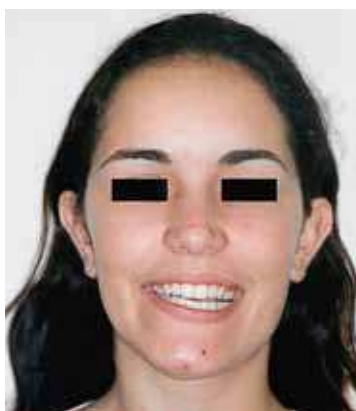

FIGURE 1 - Initial facial appearance.

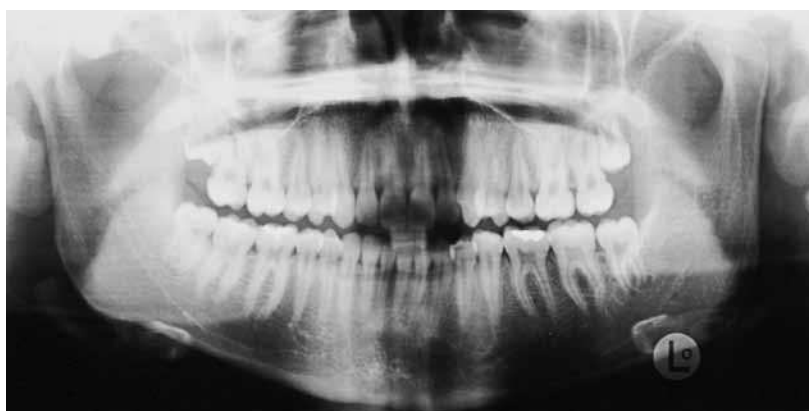


FIGURE 2 - Initial radiographic appearance.

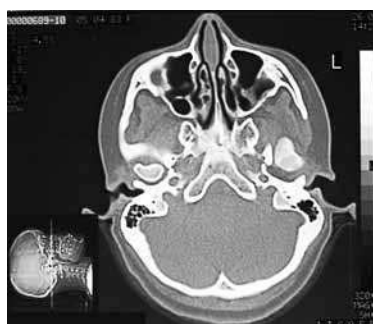

FIGURE 3 - Computed tomography showing size differences between condyles.

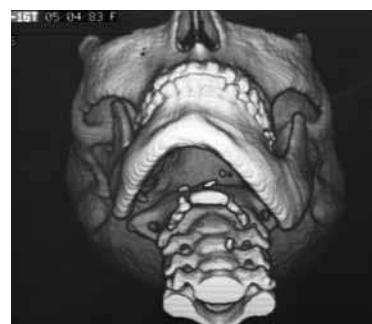

FIGURE 4 - Three-dimensional reconstruction.

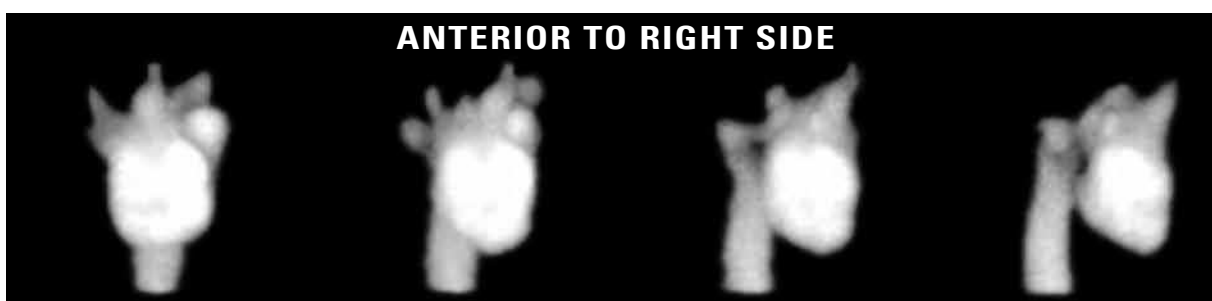


FIGURE 5 - Bone scintigraphy showing increased uptake in the left condyle.

## Case 2

A male Caucasian patient, 16 years old, sought dental care because of a facial asymmetry. He had no history of trauma. Clinically, he showed a mandibular deviation and lower midline shift to the right side, inclined maxillary occlusal plane, chin deviation and misalignment in a typical case of hybrid form condylar hyperactivity (Fig 6).

Radiographs showed a volume increase in condylar mass on the left side and increased distances between root apices and mandibular canal (Fig 7). Treatment consisted of presurgical orthodontic preparation, unilateral maxillary intrusion with skeletal anchorage provided by a miniplate and, at the final growth stage, mandibular orthognathic surgery and genioplasty, without condyle removal.

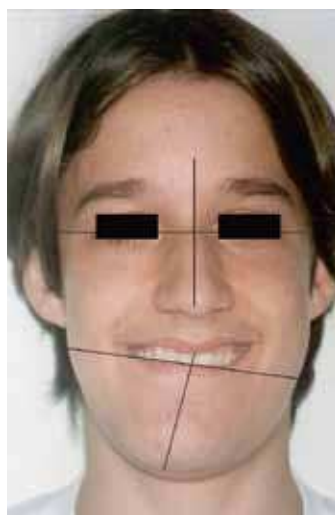


FIGURE 6 - Initial facial appearance.

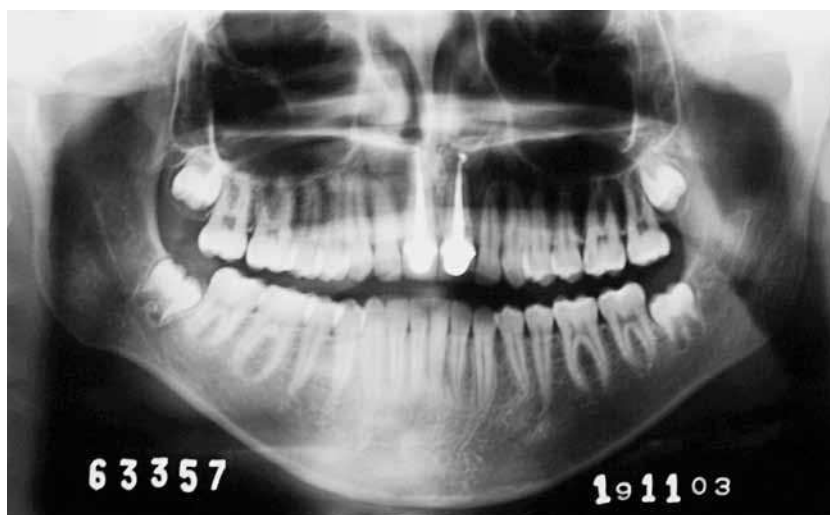

FIGURE 7 - Initial radiographic appearance.

## DISCUSSION

An accurate diagnosis of the different types of anomalies is essential for a suitable treatment plan. Besides clinical analysis and the use of conventional radiographs, computed tomography with three-dimensional reconstruction (3D) allows for greater visualization of the skeleton and better assessment of the affected areas. Bone scintigraphy is an auxiliary diagnostic method that makes it possible to detect diseases or metabolic changes and has proven effective in monitoring bone growth. It normally uses

technetium pyrophosphate 99, which identifies areas with increased osteoblastic activity.<sup>1,3</sup> It is noteworthy, however, that some procedures that cause osteoblastic or osteoclastic activity, such as dental extractions, can interfere with imaging results.<sup>16</sup> Therefore, one should always associate imaging results with other clinical data.

The treatment of choice for condylar hyperactivity is debatable and varies among different authors. Patient age, clinical progress and severity of the deformity<sup>2</sup> should be taken into account before treatment planning.

In the past, asymmetry treatment consisted only of orthognathic surgery. However, relapse occurred if condylar hyperactivity was still active. Nowadays, thanks to the development of new diagnostic techniques growth can be assessed, and with it the risk of relapse, making it possible to administer a more suitable therapy, such as orthosurgical treatment and high condylectomy when necessary.<sup>4</sup>

In case 1, the patient presented with maxillary occlusal plane inclination and mandibular asymmetry. Given the fact that orthodontic anchorage methods with the use of miniplates for intrusion of maxillary segment were not yet reported in the literature, the treatment consisted of orthognathic surgery. A Le Fort I type osteotomy was performed with gradual intrusion of the left side, leveling the maxillary occlusal plane. In the mandible osteoplasty of the body, ramus and gonial angle were performed and since there was active growth in the left side, a high condylectomy was chosen, thus removing the growth center responsible for the asymmetry (Figs 8, 9 and 10).

Different approaches can be adopted for the treatment of condylar hyperactivity. Some authors believe that high condylectomy should be performed as soon as possible after diagnosing hyperactivity and when there is a tendency towards further development of asymmetry. This would result in the removal of the center responsible for hyperactivity, but the need may arise for a second procedure to correct deformities.<sup>12</sup> Currently, it is known that the condyle is a center of regional growth and not responsible for the overall growth of the mandible. An intervention in the condyle can therefore be performed without causing major changes in facial growth.<sup>5,10</sup> Moreover, when condylectomy is performed before the end of growth it has the additional advantage of spontaneously remodeling soft tissue and the condyle in the articular fossa.<sup>2</sup>

Some authors base their treatment choice on patient age and asymmetry development speed. In young patients with active hyperactivity they usually perform a high condylectomy.<sup>2</sup> However, if asymmetry development is slow and does not cause an unsightly facial appearance, treatment should only be carried out after growth has ceased. In adult patients whose growth is inactive the recommended therapy is orthognathic surgery, but if condylar growth is active, condylectomy and orthognathic surgery are indicated. Other authors, however, disagree.<sup>9</sup> They believe that a longer time period should elapse to allow for latent or continuous hyperplastic growth to manifest.

Currently, complex cases such as the intrusion of posterior teeth<sup>8</sup> can be resolved with the aid of miniplates. These devices are installed temporarily in the maxilla or mandible and afford stable and effective skeletal anchorage, enabling the performance of orthodontic movements<sup>17</sup> and thereby restoring the occlusal level.

In case 2, as the patient's maxilla was involved, orthodontic anchorage was performed with miniplates, which allowed the intrusion of the posterior segment of the left maxilla (Figs 11 and 12). Thus, the maxillary occlusal plane was aligned, setting the stage for a less invasive surgical treatment plan and the correction of asymmetry through intervention in the mandible (vertical technique) and chin, for esthetic correction. No intervention was made in the condyles as the bone scintigraphy performed preoperatively showed symmetrical uptake in the condyles, showing that there was no hyperactivity but only the patient's normal growth (Figs 13 and 14). The two cases demonstrate different behaviors in the timing and form of intervention as new techniques emerged, allowing the administration of less invasive treatments. Satisfactory results were achieved even with different approaches, i.e., occlusal stability was gained and maintained during a monitoring period of four years in case 1 and one year in case 2.



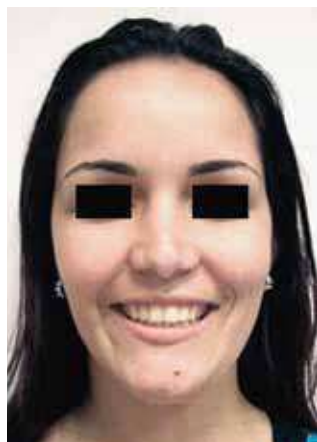

FIGURE 8 - Postoperative facial appearance.

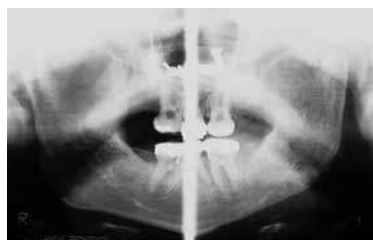

FIGURE 9 - Postoperative radiograph showing a remodeled left condyle.

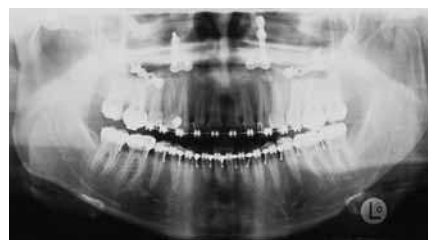

FIGURE 10 - Postoperative panoramic radiograph.

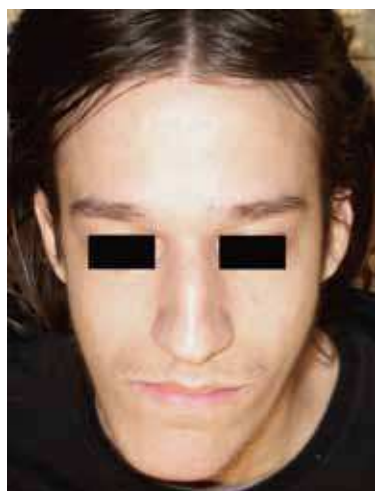

FIGURE 11 - Preoperative facial appearance after leveling of upper occlusal plane.




FIGURE 13 - Postoperative facial appearance.

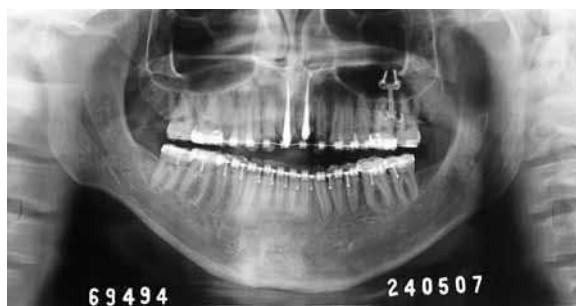

FIGURE 12 - Panoramic radiograph showing leveling of upper occlusal plane with the use of miniplates.

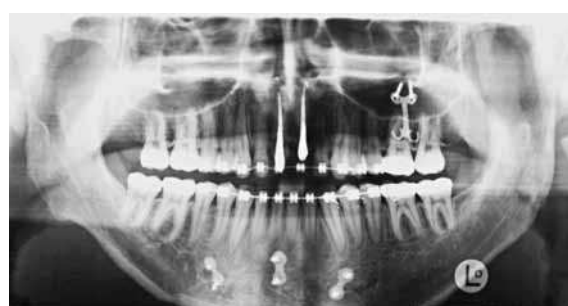

FIGURE 14 - Postoperative panoramic radiograph.

## CONCLUSIONS

Facial asymmetries caused by condylar hyperactivity can cause considerable inconvenience to patients. Early diagnosis and the establishment of an appropriate therapy is of utmost importance to avoid development of secondary deformities, which would render the treatment more complex. Therefore, we must conduct a proper clinical examination as well as complementary examinations such as radiography, 3D computed tomography and bone scintigraphy.

After diagnosis, an appropriate treatment must take into account patient age, deformity development rate, whether or not hyperactivity is present, asymmetry severity level and functional constraints. Only then, the best possible procedure should be selected

## REFERENCES

1. Araújo A, Gabrielli MFR, Medeiros PJ. Aspectos atuais da cirurgia e traumatologia bucomaxilofacial. São Paulo: Ed. Santos; 2007.
2. Bertolini F, Bianchi B, De Riu G, Di Blasio A, Sesenna E. Hemimandibular hyperlasia treated by early condylectomy: a case report. *Int J Adult Orthodon Orthognath Surg*. 2001 Fall;16(3):227-34.
3. Bittencourt LP. Verificação da condição condilar em pacientes com padrão esquelético classe III por intermédio da cintilografia óssea. *Radiol Bras*. 2005;38(4):273-7.
4. Cervelli V, Bottini DJ, Arpino A, Trimarco A, Cervelli G, Mugnaini F. Hypercondylia: problems in diagnosis and therapeutic indications. *J Craniofac Surg*. 2008 Mar;19(2):406-10.
5. Delaire J. Le traitement des hypercondyles mandibulaires (plaidoyer pour la condylectomie). *Actual Odontostomatol*. 1977;117:29-45.
6. Silva EDO, Laureano JR Filho, Rocha NS, Annes PMR, Tavares PO. Tratamento cirúrgico de assimetria mandibular: relato de caso clínico. *Rev Cirur Traumatol Buco-Maxilo-Facial*. 2004 jan-mar;4(1):23-9.
7. Egyedi P. Aetiology of condylar hyperplasia. *Aust Dent J*. 1969 Feb;14(1):12-7.
8. Faber J, Berto PM, Anchieta M, Salles F. Tratamento de mordida aberta anterior com ancoragem em miniplacas de titânio. *Rev Dental Press Estét*. 2004 out-dez;1(1):87-100.
9. Joondeph DR. Mysteries of asymmetries. *Am J Orthod Dentofacial Orthop*. 2000 May;117(5):577-9.
10. Moyers RE. Ortodontia. 4ª ed. Rio de Janeiro: Guanabara Koogan; 1991.
11. Muñoz MF, Monje F, Goizueta C, Rodríguez-Campo F. Active condylar hyperplasia treated by high condylectomy: report of a case. *J Oral Maxillofac Surg*. 1999 Dec;57(12):1455-9.
12. Obwegeser HL. Hemimandibular hyperplasia. In: Obwegeser HL. Mandibular growth anomalies. Berlin: Springer-Verlag; 2001. p. 145-98.
13. Obwegeser HL, Makek MS. Hemimandibular hyperplasia-hemimandibular elongation. *J Maxillofac Surg*. 1986 Aug;14(4):183-208.
14. Paulsen HU, Rabol A, Sorensen SS. Bone scintigraphy of human temporomandibular joints during Herbst treatment: a case report. *Eur J Orthod*. 1998 Aug;20(4):369-74.
15. Ross RB. Developmental anomalies of the temporomandibular Joint. *J Orofac Pain*. 1999 Fall;13(4):262-72.
16. Sakar O, Sanli Y, Marsan G. Prosthodontic treatment of a patient with hemimandibular elongation: a clinical report. *J Prosthet Dent*. 2006 Sep;96(3):150-3.
17. Umemori M, Sugawara J, Mitani H, Nagasaka H, Kawamura H. Skeletal anchorage system for open-bite correction. *Am J Orthod Dentofacial Orthop*. 1999 Feb;115(2):166-74.

Submitted: August 2008  
Revised and accepted: June 2009

### Contact address

Anita Sanches Matos Santos  
Rua Tupinambás, 255, ap. 401 – Jardim da Penha  
CEP: 29.060-810 – Vitória/ES, Brazil  
E-mail: anitasms@gmail.com