

Evaluation of the effect of rapid maxillary expansion on the upper airway using nasofibroscopy: case report and description of the technique

Edmilsson Pedro Jorge*, Ary dos Santos-Pinto**, Luiz Gonzaga Gandini Júnior***, Odilon Guariza Filho*, Anibal Benedito Batista Arrais Torres de Castro****

Abstract

The aim of the present investigation is to evaluate the effect of rapid maxillary expansion on the upper airway. A clinical case is presented to describe how patients with atresic maxilla and reduced naso-respiratory function can have benefits from rapid maxillary expansion. In order to better understand the morphological alterations present in patients with respiratory disorders, it is necessary to understand the anatomy and physiology of the respiratory system. However, it is relevant to mention that this patient undergoes a multidisciplinary treatment, involving the orthodontist, the otorhinolaryngologist and the speech therapist.

Keywords: Nasofibroscopy. Rapid maxillary expansion. Buccopharynx. Nasopharynx. Nasorespiratory function. Upper airway.

* M.Sc. in Orthodontics by the Department of Orthodontics and Pedodontics of the School of Dentistry of the University of São Paulo (FOUSP). Ph.D in Orthodontics by the Pediatric Clinic Department of the School of Dentistry of the Paulista State University (UNESP - Araraquara).

** Adjunct Professor of the Pediatric Clinic Department of the School of Dentistry of the Paulista State University (UNESP - Araraquara).

*** Assistant Professor of the Pediatric Clinic Department of the School of Dentistry of the Paulista State University (UNESP - Araraquara).

**** Adjunct Professor of the Department of Otorhinolaryngology and Human Communication Disorders of the Federal University of São Paulo (UNIFESP).

INTRODUCTION

The breathing pattern may have influence on the craniofacial development, affecting the maxillary transverse relation, which may cause a posterior crossbite.¹⁴ In the patients with reduced nasorespiratory function, the most frequently observed craniofacial alterations are the reduction of the maxillary transverse width and the uni or bilateral posterior crossbites.^{12,15} The posterior crossbite usually occurs in the deciduous dentition and presents a narrowing of the upper arch transverse dimension that, usually, does not correct itself. Based on this concept, this malocclusion shall be corrected as early as possible, preferably during the deciduous and mixed dentition period.^{21,23}

The opening procedure of the midpalatal suture by rapid maxillary expansion, performed for more than a century, has aroused the interest of many researchers for its effects on morphology and nasal function. This technique introduced by E. H. Angell in 1860 was clinically consolidated by the studies of Haas.^{7,8} Since the early studies, it has been shown the effect of rapid maxillary expansion (RME) in the arch's transverse dimension, in the arch perimeter and in the nasal cavity. Several studies have associated the RME with the enlargement of the nasal cavity and a possible improvement in the nasal patency.^{29,30}

There is no doubt that the rapid maxillary expansion provides an increase in the interdental distance and, consequently, in the arch perimeter. However, calculating this increase resultant from the expansion procedure is a questionable method, given the diversity of results found on several existing papers in the literature.^{13,21,30,32}

During the first six months of life, the lead cause of nasal obstructions arises from the ingestion of proteins extraneous to the organism, causing allergic rhinitis.^{19,20} During childhood and adolescence, the respiratory insufficiency, which affects an expressive number of children at different levels, may be associated with several etiologic

factors, such as palatine tonsillar hypertrophy, pharyngeal tonsillar hypertrophy, nasal concha hypertrophy, nasal septum deviation, chronic allergy, sinusitis, nasal trauma, nasal polyps and extraneous organisms. Consequently, these several factors may cause a long and narrow face, maxillary atresia, mandibular retrognathia, increase in the anterior facial height, increase of the mandibular plane angle, deep palate, overjet and high incidence of posterior crossbite.^{2,15,22,25}

The pharyngeal complex, called Waldeyer's lymphatic ring, formed by the lingual, tubal, pharyngeal and palatine tonsils, may be influenced by genetic and environmental factors that lead to a temporary or prolonged increase of these tissues with consequent obstruction of the upper airway.^{4,5} The lymphoid tissue presents rapid growth during the first three years of life, keeps growing gradually, and reaches a growth peak before adolescence; beginning to gradually decline up to its full atrophy in the adult phase of life.⁵ Studies by Handelman and Osborne⁹ showed that the nasopharynx grows in girls until the age of thirteen and in boys until the age of seventeen. The highest pharyngeal tonsil growth peak occurs between 10 and 15 years of age,^{26,27} and the nasopharyngeal airway space increases in early adolescence, due to the simultaneous growth of the nasopharynx and the involution of the adenoid tissue.⁹ Many authors consider the pharyngeal tonsil hypertrophy as one of the triggering factors of mouth breathing and malocclusion.^{3,15,24,26,27} However the palatine tonsil hypertrophy may have the same obstructive effect of the pharyngeal tonsil hypertrophy, besides causing changes in the position of the mandible and in the positioning of the tongue down and forward. However, if these postural changes persist for long periods, especially during the active stage of growth, they may cause dentofacial disorders of different severity levels.^{2,5,12,26,33}

Therefore, before any attempt of treatment, it is important to determine whether the cause of the nasal obstruction is in fact obstructive or

just habitual. For that, it is necessary to perform a detailed anamnesis, clinical exam, functional tests, supplementary exams and follow-ups by a multidisciplinary team involving the pediatrician, the otorhinolaryngologist, the orthodontist and the speech therapist,^{19,24,25} for only then an accurate diagnosis is obtained so that the patient is treated properly, avoiding incorrect procedures that might compromise the treatment.

The frontal cephalometric radiography (posteroanterior) has been used in several studies for being a diagnostic method that allows the differentiation of the alterations produced by the rapid maxillary expansion (RME) in the orthodontic and orthopedic treatment, besides quantifying the transverse increase of the nasal cavity.^{7,8,23,30}

However, nasofibroscopy has revolutionized the diagnostic method nowadays, for the use of small-sized flexible or rigid telescopes connected to a micro-camera and a light source through optical fiber cables enables viewing and recording in VHS tape the images obtained from the buccopharyngeal and nasopharyngeal regions, allowing a direct visualization of the palatine tonsils, nasal cavities, pharyngeal tonsil, with an excellent image quality, thus making the highest diagnostic accuracy possible. Therefore, this extremely important exam has been shown to be more effective than the lateral radiograph of the pharyngeal cavum in the evaluation of size and shape of the pharyngeal tonsil.³ While the lateral cephalometric radiograph and the pharyngeal cavum radiograph are efficient to evaluate the buccopharynx and nasopharynx adjacent structures only in the two-dimensional aspect, being ineffective to provide a reliable indication of the nasal obstruction,²⁸ the nasofibroscopy, in addition to the ability to evaluate the nasopharyngeal region in three dimensions, is able to show a large variety of etiologic factors that cause the obstruction of the upper airway.^{3,6,10,11,17,31}

Therefore, the aim of the present article is to assess if any changes occurred in the upper airway of the patient who presented transverse alteration

of the upper arch and indication for rapid maxillary expansion.

RAPID MAXILLARY EXPANSION

Rapid maxillary expansion device

The device used for rapid maxillary expansion was a tooth-tissue supported device.⁷ The device was made of acrylic resin with an 11-mm expansion screw centered in the middle of the appliance. Orthodontic bands were used on the first premolars and on the first upper permanent molars.

Installation and activation of the rapid maxillary expansion device

A 12 year and 2 month old female Caucasian patient was referred to the orthodontic clinic with a view to improving her smile and the positioning of her teeth. The clinical exam showed that the patient presented Angle Class I malocclusion, anterior crossbite, atresic maxilla, lower and upper anterior dental crowding with lack of space for the left and right lateral upper incisors and the right upper canine tooth. At this first consultation, the patient reported suffering from mouth breathing, thus, she was referred to the otorhinolaryngologist.

In the first phase of the treatment a Haas-type rapid maxillary expansion device was designed. On the day of installation, the patient's parents received the due recommendations in relation both to oral hygiene and the procedures for the device activation. However, the activation was only initiated on the next day.

Regarding oral hygiene, it was explained to the patient that she should always perform her oral hygiene after meals, brushing the teeth and the device. While brushing, a 20 ml plastic syringe with water shall be used to perform the removal of food debris that may remain between the palate and the device. In relation to the activation of the device, the patient's parent or guardian was called and requested to sit beside the patient in order to receive the necessary orientations and to

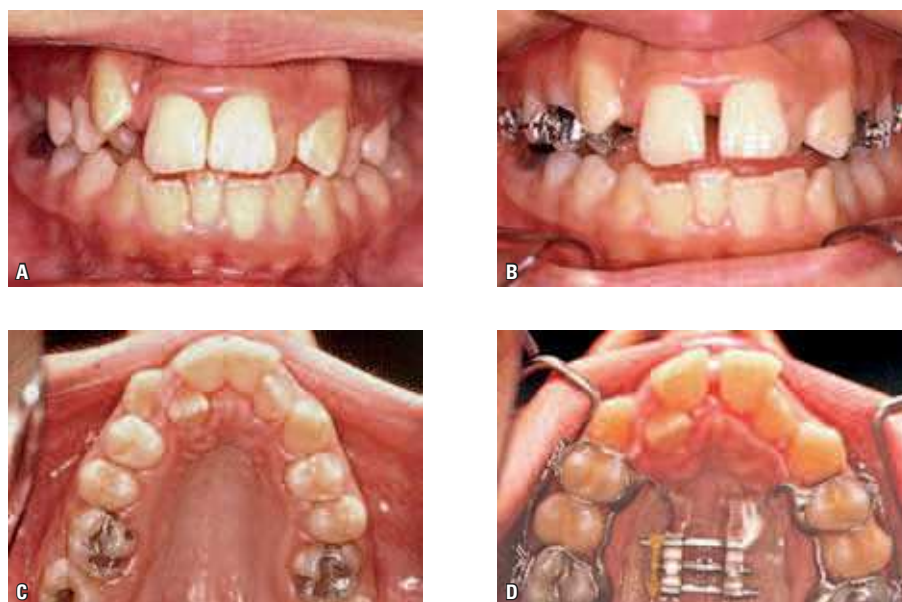

FIGURE 1 - Intraoral photos: **A)** Frontal, severe upper anterior crowding with lack of space for the left and right upper lateral incisors and the right upper canine tooth; **B)** frontal with opening of the diastema between the upper central incisors; **C)** upper occlusal showing the reduction of the upper arch transverse distance due to maxillary atresia and upper lateral incisors with lingual inclination; and **D)** upper occlusal after the opening of the midpalatal suture.

observe how the activation of the expansion device should be carried out. First, it was explained that the procedure should be performed by tying the screw activation key to a piece of dental floss that should be tied to one of the fingers of the person who will perform the activation. This procedure is necessary in order to avoid the accidental swallowing of the key. The father was instructed that for the activation of the device the key shall be activated from the anterior to posterior, being two quarter turns in the morning and two quarter turns in the evening, totalizing a full turn of the screw per day. After the initial explanation, the activation of the screw was performed, and then the patient's father was requested to perform the same procedure, in order to observe if he would not have any doubts while performing the activation at home. After all the doubts had been clarified, the patient was dismissed from the clinic.

Recall appointments were scheduled every three days for periodical control of the expansion and to verify if the activation was being performed properly.

NASOFIBROSCOPY

Nasofibroscopy exam

Type of device

The following devices were used to perform the patient's nasofibroscopy: 1) a Xenon Nova 20131520 Karl Storz Endoskope light source; 2) a microcamera Watec WAT-202B Color Camera; 3) two types of 0-degree wide-angled telescopes—(a) a 3 mm Machida EN6500, when there was no obstruction or the nasal cavities obstruction was mild or moderate and (b) a 2 mm Karl Storz 7208A when the nasal cavities obstruction was severe; 4) a Toshiba CM 1300 K television; 5) a Toshiba M 447 VCR; 6) Sony T-120 EDC videotape cassettes.

Examination

Before starting the examination, it was verified if the patient had a cold, because in that case, the exam would have to be postponed to another date, when the patient is presenting normal health conditions.

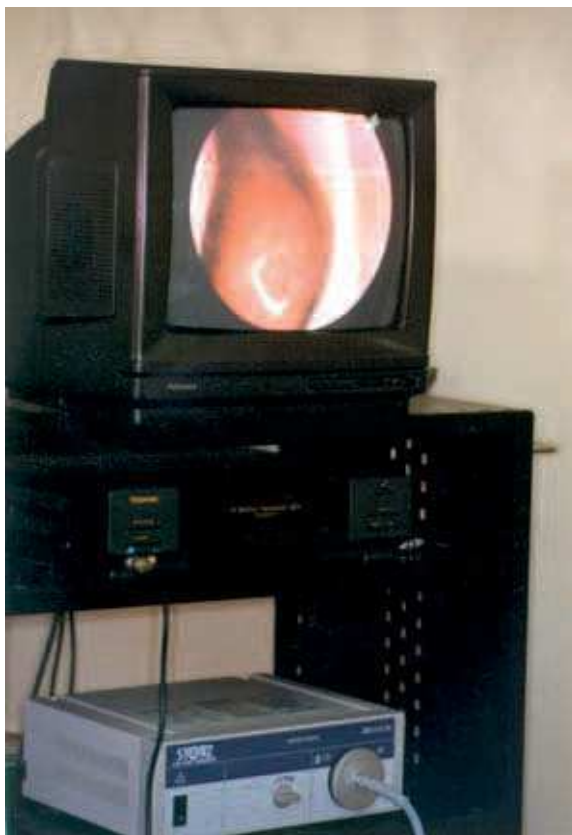

FIGURE 2 - Equipment used to perform the nasofibroscopy exam.




FIGURE 3 - 0-degree wide-angle telescopes.



FIGURE 4 - Karl Storz (Xenon Nova) light source and Watec color microcamera.

The procedure was fully explained to the patient, who was instructed to sit comfortably in a chair in front of the television.

The examination was initiated by the oral cavity, where the otorhinolaryngologist, using a telescope, verified the shapes of the arch and the palate, if there was overbite or overjet, the size of the uvula, the presence or absence of the palatine tonsils. And if they were present, if they were normal-sized or hypertrophic. If they were not within the normal range, it was verified if the hypertrophy was mild, moderate or severe. After the completion of the oral cavity examination, the nasal cavities examination was initiated.

The nasal cavities examination was initiated by the right nostril; the doctor, using a telescope, observed the nasal morphology, if the nasal valve was open or closed, if the nasal septum was within the normality or if there was septum deviation, if the lower and median nasal turbinates were normal or hypertrophied and, finally, the presence or absence of the pharyngeal tonsil. If it were present, it should be verified if its size was normal or altered. If it was not within the normal range, it was verified if the hypertrophy was mild, moderate or severe. Then the left nasal cavity examination was carried out, just as previously described.

When the 3 mm telescope was not able to perform the exam completely, due to nasal conchae hypertrophy, septum deviation or spur, it was replaced by a 2 mm telescope in order to conclude it.

The examination was recorded on a Sony T-120 EDC videotape cassette.



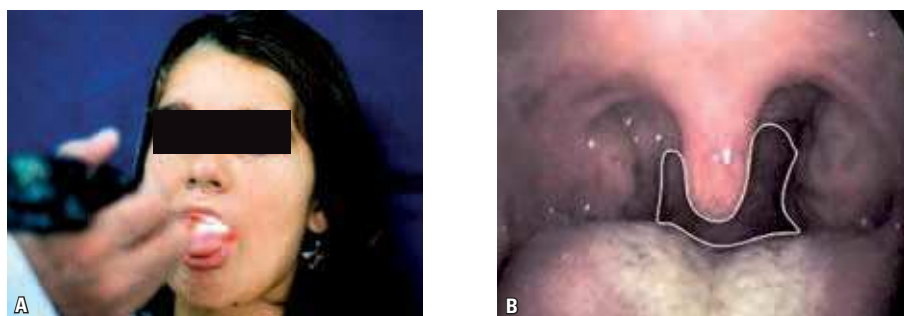


FIGURE 5 - **A)** Buccal cavity nasofibroscopy examination. **B)** Examination performed with 0-degree telescope, showing the buccopharyngeal gap.

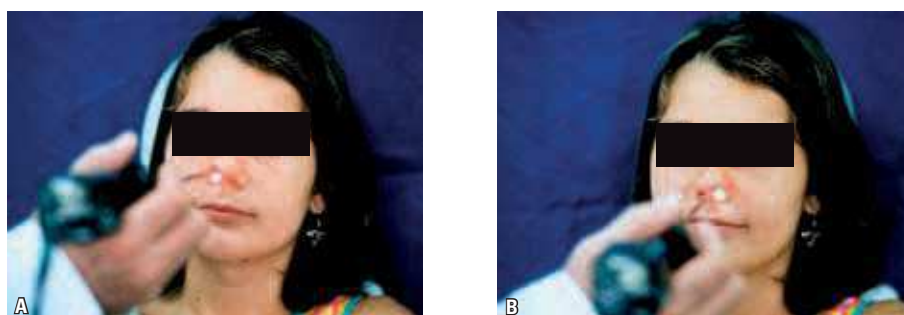

FIGURE 6 - Nasofibroscopy Examination. **A)** Right nasal cavity exam and **B)** left nasal cavity exam.

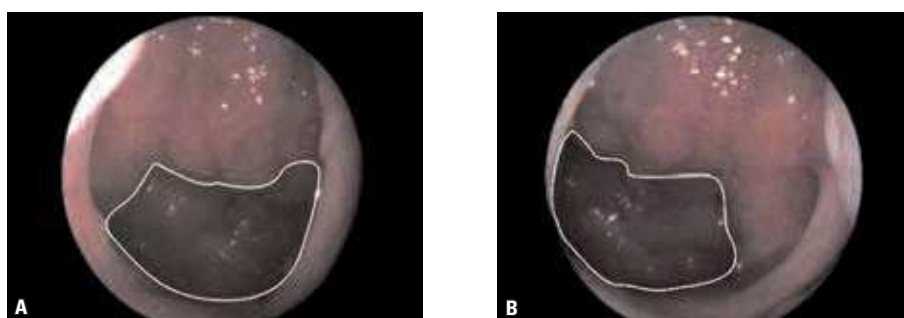


FIGURE 7 - **A)** View of the right nasal cavity of the nasopharyngeal gap and **B)** View of the left nasal cavity of the nasopharyngeal gap.

Method for calculating the percentage of buccopharyngeal and nasopharyngeal gaps

In order to calculate the percentage of the buccopharyngeal and nasopharyngeal total spaces and gaps before and after the rapid maxillary expansion (RME) using the Haas-type device, the nasofibroscopy exam was previously performed, generating images that were recorded on

Sony T-120 EDC videotape cassettes. The conversion of these videos to DVD was carried out through the software Xilisoft Video Converter 2.1.46 build 520B, with the following video codec specifications: Mpeg2 video and 640 X 480 pixels video resolution. Thus, the buccopharynx and nasopharynx's images were analyzed through the software Windows Movie Maker,

part of Windows XP Professional SP2. For the analysis of the nasofibroscopy exam, the three better images of both the buccopharynx and nasopharynx were frozen within a 3 second interval and saved in a small file in order to, posteriorly, calculate the percentage of buccopharyngeal and nasopharyngeal total spaces and gaps visualized through the left and right nasal cavities, using the software UTHSCSA developed in the "Department of Dental Diagnostic Science at the University of Texas Health Science Center". A 1000 dpi Microsoft notebook optical mouse 3000 was used to accurately delimit the buccopharyngeal and nasopharyngeal total spaces and gaps.

Thus, the average of values obtained from the three images of the buccopharynx and nasopharynx visualized through the left and right nasal cavities was considered to obtain the study variables. Then, after obtaining the palatine tonsils and the buccopharyngeal total areas, the gap was calculated by the difference between these two areas. Likewise, after obtaining the nasopharyngeal total area viewed through the right and left nasal cavities and the pharyngeal tonsillar area, the gap was calculated by the difference between these two areas.

FINAL COMMENTS

After the rapid maxillary expansion (RME), an increase of the buccopharyngeal and nasopharyngeal gaps viewed through the left and right nasal cavities was observed.

Therefore, an increase of the buccopharyn-

geal and nasopharyngeal airways^{11,16,17} as well as a reduction in the nasal resistance were demonstrated after the rapid maxillary expansion procedure, event previously reported in existing publications.^{17,18} However, we must be aware that this orthopedic procedure, despite the benefit of the nasal resistance reduction and consequent increase in the nasal patency, should not be performed for the sole purpose of providing an improvement in the nasal function in patients with breathing difficulties, but only when it is associated to a correct indication for rapid maxillary expansion.^{29,30}

Thus, one of the purposes of this study is to emphasize the fact that the expansion device, used for rapid maxillary expansion (RME), besides correcting uni or bilateral posterior cross-bites—its main function—, also contributes to the nasal resistance reduction and the nasal conductance increase. Another relevant aspect to be mentioned is the fact that through the nasofibroscopy examination it is possible to diagnose the etiologic factors that cause the obstruction and reduction of the nasorespiratory function.

However, this work was developed in a context of orthodontist-otorhinolaryngologist interdisciplinary collaboration, whereas the respiratory changes and their consequences represent a common interest in the craniofacial development. However, it is important to mention that the otorhinolaryngologist is the most capable and qualified professional to diagnose and treat respiratory disorders.

REFERENCES

1. Angell EH. Treatment of irregularity of the permanent or adult teeth. Part I. *Dent Cosmos*. 1980 May;1(10):540-4.
2. Ceylan I, Oktay H. A study on the pharyngeal size in different skeletal patterns. *Am J Orthod Dentofacial Orthop*. 1995 Jul;108(1):69-75.
3. Chami FAI. Avaliação nasofibrocópica e radiológica de pacientes com hiperplasia da amígdala faríngea. *Rev Bras Med*. 1988 jul-ago;5(4):118-25.
4. Coccarro PJ, Coccarro PJ Jr. Dental development and the pharyngeal lymphoid tissue. *Otolaryngol Clin North Am*. 1987 May;20(2):241-57.
5. Diamond O. Tonsils and adenoids: why the dilemma? *Am J Orthod*. 1980 Nov;78(5):495-503.
6. Ianni Filho D, Raveli DB, Raveli RB, Loffredo LCM, Gandini LG Jr. A comparison of nasopharyngeal endoscopy and lateral cephalometric radiography in the diagnosis of nasopharyngeal airway obstruction. *Am J Orthod Dentofacial Orthod*. 2001 Oct;120(4):348-52.
7. Haas AJ. Rapid expansion of the maxillary dental arch and nasal cavity by opening the midpalatal suture. *Angle Orthod*. 1961 Apr;31(2):73-90.
8. Haas AJ. The treatment of maxillary deficiency by opening the midpalatal suture. *Angle Orthod*. 1965 Jul;35(3):200-17.
9. Handelman CS, Osborne G. Growth of the nasopharynx and adenoid development from one to eighteen years. *Angle Orthod*. 1976 Jul;46(3):243-58.
10. Jorge EP. Estudo das características funcionais, morfológicas e craniofaciais de pacientes com má oclusão de Classe II divisão 1ª de Angle, com predomínio da respiração bucal [dissertação] Araraquara (SP): Universidade Estadual Paulista; 2000.
11. Jorge EP. Avaliação da resistência nasal total e do espaço livre bucofaringeano e nasofaringeano em pacientes com má oclusão de classe II divisão 1ª de Angle, submetidos ao tratamento ortopédico com bionator de Balters [tese] Araraquara(SP): Universidade Estadual Paulista; 2006.
12. McNamara JA Jr. Influence of respiratory pattern on craniofacial growth. *Angle Orthod*. 1981 Oct;51(4):269-300.
13. McNamara JA Jr, Baccetti T, Franchi L, Herberger TA. Rapid maxillary expansion followed by fixed appliances: a long-term evaluation of changes in arch dimensions. *Angle Orthod*. 2003 Aug;73(4):344-53.
14. Melsen B, Attina L, Santuari M, Attina A. Relationships between swallowing pattern, mode of respiration, and development of malocclusion. *Angle Orthod*. 1987 Apr;57(2):113-20.
15. Oulis CJ, Vadiakas GP, Eknomides J, Dratsa J. The effect of hypertrophic adenoids and tonsils on the development of posterior crossbite and oral habits. *J Clin Pediatr Dent*. 1994 Spring; 18(3):197-201.
16. Ozbek MM, Memikoglu UT, Gogen H, Lowe AA, Baspinar E. Oropharyngeal airway dimensions and functional-orthopedic treatment in skeletal class II cases. *Angle Orthod*. 1998 Aug;68(4):327-36.

17. Paiva JB. Estudo rinomanométrico e nasofibroendoscópico da cavidade nasal de pacientes submetidos à expansão rápida da maxila [tese]: Faculdade de Odontologia da Universidade de São Paulo; 1999.
18. Rizzato SMD. Avaliação do efeito da expansão rápida da maxila na resistência nasal por rinomanometria anterior ativa em crianças [tese]. Pontifícia Universidade Católica do Rio Grande do Sul (RS); 1998.
19. Rubin RM. Mode of respiration and facial growth. *Am J Orthod*. 1980 Nov;78(5):504-10.
20. Saadia AM. Airway obstruction and facial form: a review. *J Pedod*. 1981 Spring;5(3):222-39.
21. Sandickçiolu M, Serpil H. Skeletal and dental changes after maxillary expansion in the mixed dentition. *Am J Orthod Dentofacial Orthop*. 1997 Mar;111(3):321-7.
22. Santos-Pinto A, Paulin RF, Melo ACM, Martins LP. A influência da redução do espaço nasofaríngeo na morfologia facial de pré-adolescentes. *Rev Dental Press Ortod Ortop Facial*. 2004 maio-jun; 9(3):19-26.
23. Silva Filho OG, Montes LAP, Torelly LF. Rapid maxillary expansion in the deciduous and mixed dentition evaluated through posteroanterior cephalometric analysis. *Am J Orthod Dentofacial Orthop*. 1995 Mar;107(3):268-75.
24. Smith RM, Gonzalez C. The relationship between nasal obstruction and craniofacial growth. *Pediatr Clin North Am*. 1989 Dec;36(6):1423-34.
25. Sousa JBR, Anselmo-Lima WT, Valera FCP, Gallego AJ, Matsumoto MAN. Cephalometric assessment of the mandibular growth pattern in mouth-breathing children. *Int J Pediatr Otorhinolaryngol*. 2005 Mar;69(3):311-7.
26. Subtelny JD. Effect of diseases of tonsils and adenoids on dentofacial morphology. *Ann Otol Rhinol Laryngol*. 1975 Mar-Apr;84(2):50-4.
27. Subtelny JD. Oral respiration: facial maldevelopment and corrective dentofacial orthopedics. *Angle Orthod*. 1980 Jul;50(3):147-64.
28. Warren DW. A quantitative technique for assessing nasal airway impairment. *Am J Orthod*. 1984 Oct;86(4):306-14.
29. Wertz RA. Changes in nasal airflow incident to rapid maxillary expansion. *Angle Orthod*. 1968 Jan;38(1):1-11.
30. Wertz RA. Skeletal and dental changes accompanying rapid midpalatal suture opening. *Am J Orthod*. 1970 Jul;58(1):41-66.
31. Wormald PJ, Prescott CAJ. Adenoids: comparison of radiological assessment methods with clinical and endoscopic findings. *J Laryngol Otolaryngol*. 1992 Apr;106(4):342-4.
32. Lagraverre MO, Major PW, Flores-Mir C. Long-term dental arch changes after rapid maxillary expansion treatment: A systematic review. *Angle Orthod*. 2005 Mar;75(2):155-61.
33. Behlfelt K, Linder-Aronson S, Neander P. Posture of the head, the hyoid bone, and the tongue in children with and without enlarged tonsils. *Eur J Orthod*. 1990 Nov;12(4):458-67.

Submitted: December 2008
Revised and accepted: June 2009

Contact address

Edmilsson Pedro Jorge
Rua Francisco Rocha nº 1750, sala 604 – Champagnat
CEP: 80.730-390 – Curitiba / PR
E-mail: edmilssonjorge@yahoo.com.br