

An interview with Jason Cope

- Graduated in Biology, Southern Methodist University, Dallas, Texas.
- Graduated in Dentistry, Baylor College of Dentistry, Dallas, Texas.
- Graduated in Orthodontics, Baylor College of Dentistry, Dallas, Texas.
- Graduated in Craniofacial Biology, TAMUS – Baylor College of Dentistry, Dallas, Texas.
- Diplomate, American Board of Orthodontists.
- Full Member, Edward H. Angle Society of Orthodontists, Southwest Component.
- Fellow, American College of Dentists.
- Adjunct Clinical Assistant Professor, Department of Orthodontics, TAMUSHSC – Baylor College of Dentistry, Dallas, Texas - 1997 to 2009.
- Adjunct Assistant Professor, Department of Oral & Maxillofacial Surgery and Pharmacology, TAMUSHSC – Baylor College of Dentistry, Dallas, Texas - 2005 to 2009.
- Adjunct Associate Professor, Department of Graduate Orthodontics, St. Louis University, St. Louis, Missouri.
- Editor, OrthoTADs: The Clinical Guide and Atlas, 2007 Under Dog Media, LP, www.UnderDogMedia.us.
- Editor, www.CopestheticCE.com.



It was with great pleasure that I accepted the invitation to coordinate the interview with Dr. Cope, whom I admire greatly, especially because of the excellent clinical and scientific work he develops. He obtained great highlight on the international scene for his brilliant performance with the use of orthodontic miniscrews. Recently, in the last Congress of the Brazilian Association of Orthodontists, he presented a well attended course on the subject.

Dr. Jason B. Cope was born in Dallas (USA), first son of Dr. Donald D. Cope, an orthodontist in love with the profession, which exerted a strong influence on his career. He was introduced to the intricacies of orthodontics, when he was just a teenager with 13 years old, because he usually read, with great interest, the American Journal of Orthodontics, journal subscribed by his father. Perhaps because of this he decided to study dentistry, graduating in 1995. He completed his postgraduate studies in orthodontics in 1997 and was invited to join the faculty of the same institution as assistant clinical professor. Simultaneously, for another two years, he did a post-doctoral fellow in craniofacial biology. In his young career, Dr. Cope has published several articles in leading international journals, 35 book chapters and an important treatise on distraction osteogenesis, plus an excellent book on temporary anchorage devices (OrthoTADs, The Clinical Guide and Atlas), published in 2007. He was also honored with several awards for his research on bone biology, including the Award of Special Merit Thomas M. Graber, awarded by the American Association of Orthodontics. Natural born researcher, developed the IMTEC orthodontic implant and some other products designed to orthodontics, having won a patent, along with three others still pending.

He has a clinical private practice in Dallas, and sees patients three days a week. On other days, he is divided between presenting conferences, publishing, travelling and inventing. He is currently developing a website, in which he intends to offer lectures given by him, case reports and technical videos. His dedication to orthodontics is evident. In 2002, with the goal of proving the clinical excellence of his work, he underwent the examination of the American Board of Orthodontics, when it then became a graduate. In 2004, he presented a scientific paper to become a member of the Edward H. Angle Society of Orthodontists, and in 2005, he was awarded a prize by the Baylor College of Dentistry Alumni Association. All this makes Dr. Cope more than worthy of great success. We shall know more of the details of this excellent professional work through this interview that we tried to edit with great care and affection. We hope everyone enjoys the reading.

Marcos Alan Vieira Bittencourt

1) Do you consider the temporary anchorage devices (TADs) the new paradigm in orthodontics? Why?

Carlos Alberto Estevanell Tavares

I believe TADs are one of several new paradigms in orthodontics. Others include soft tissue lasers and Cone-Beam Computed Tomography (CBCT). Although I use all three clinically, I think TADs are the most important because they benefit a larger number of patients. For example, CBCT is beneficial for impacted canines and several other less common situations. Soft tissue lasers are great for uncovering teeth, gingivectomies, frenectomies, and the like. But, these are all procedures that can be performed by a periodontist. Our limitations with controlling anchorage, however, are significant and cannot be referred to another person to handle. There are several cases in which TADs are the only way to ideally control anchorage: A) protraction of posterior teeth to eliminate the need for restoring congenitally missing teeth (Fig 1); B) preprosthetic tooth movement in mutilated dentitions; C) intrusion of supererupted teeth; D) distalization of full step Class II or Class III malocclusions; and E) skeletal open bites in patients unable or unwilling to undergo surgical treatment.

2) Which methods do you use to assure a safe placement of the TADs?

Carlos Alberto Estevanell Tavares

Several methods have been advocated to pro-

vide safety for TAD placement. One is to use radiographic templates and guides. There are several limitations with this technique. First, the Buccal Object Rule must be used, which predicates multiple radiographs and wasted clinical time. Moreover, few orthodontists have the ability to take periapical radiographs. Finally, it is completely inaccurate, and only accounts for the insertion point and not the final location of the TAD. This technique does not improve the safety of TADs for patients.

The second is to use infiltration of local anesthetic. This is advocated by those who don't want patients to feel anything. Although, it would be nice for patients to feel nothing, the limitation with this technique is that it profoundly anesthetizes the soft tissue, periodontal ligament (PDL), and pulp, which then completely eliminates the ability for the patient to give feedback if they do feel something.

The third option is to use topical anesthetic only. I developed the first topical anesthetic only protocol back in 2004. To explain, I saw great resistance of orthodontists to place miniscrews due to the "surgical" appearance of the procedure and need for local anesthetic injections. It became readily apparent that in order to motivate orthodontists to engage the process, the technique would have to be relatively fast, simple, and "nonsurgical". Therefore, I developed an alternative technique to avoid local anesthetic injections.

Much like extracting a tooth, the placement of a miniscrew implant (MSI) involves two po-

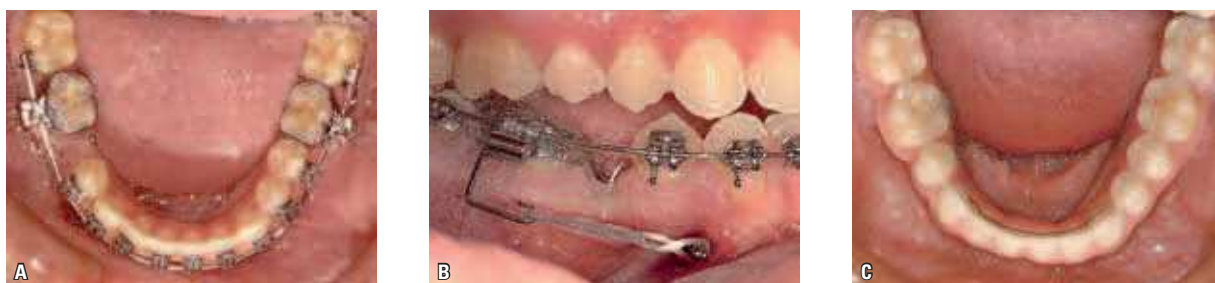

FIGURE 1 - Protraction of posterior teeth to eliminate the need for restoring congenitally missing teeth. **A)** Mandibular occlusal at TAD placement; **B)** Buccal at TAD placement; **C)** Mandibular occlusal at posttreatment.

tential sensations felt by patients – pressure and pain. Pressure is felt by patients because bone is viscoelastic and responds to internal pressure (either via tooth removal or miniscrew insertion) by expanding. This expansion causes fluid flow through the bony canaliculi, which patients perceive as pressure. Pain is felt if the sensory, or afferent, nerves are triggered. For bone, the internal anatomy is not innervated, only the external surface is innervated. The nerve supply comes from the periosteum, which is richly innervated by sensory periosteal nerves. This is why breaking a bone is painful, i.e., tearing of the periosteal membrane. The gingiva, mucosa, teeth, and PDL receive sensory (afferent) innervation from the Trigeminal Nerve, which when activated, stimulates pain. Considering the foregoing, if the soft tissues and periosteum can be anesthetized without anesthetizing the tooth root and PDL, then a patient can be completely pain-free, while at the same time being sensate and able to detect the proximity of the miniscrew during insertion, but before contact is ever made with the tooth root. It is important to recall that bony expansion during miniscrew insertion will cause patients to experience pressure. Therefore, it is incumbent upon the clinician to make sure the patient understands the difference between pressure and pain.

Using this biologic rationale, I began to develop an atraumatic, topical anesthetic miniscrew placement protocol in 2004 with Oraqix (Dentsply Pharmaceutical, York, PA), a high strength periodontal topical anesthetic. After the success of the initial clinical trials, we formally introduced this as the Cope Placement Protocol™ in 2005. A year later, I switched to a more potent high strength topical anesthetic, DepBlu (Steven's Pharmacy, Costa Mesa, CA), which provides profound soft tissue and periosteal anesthesia with limited anesthetic effect on tooth roots and PDL. There are several benefits: the procedure is much simpler because local infiltration by

injections is unnecessary and there is little risk of anesthetizing the tooth root, so the potential of hitting the tooth root is almost impossible.

In about 15% of cases, the soft tissue is thicker than about 2 mm so I will use the Madajet (MADA International, Carlstadt, NJ) needle free pneumatic syringe. Importantly, this still anesthetizes only the soft tissues and periosteum.

3) Even using computed-tomography to evaluate the interradicular space to prevent root damage during treatment, what do you do when you detect contact between miniscrews and roots, or it does not happen at all? José Nelson Mucha

Using the above Cope Placement Protocol™, it is almost impossible to hit a tooth. And, although I have a CBCT machine, I believe that the routine use of CBCT for TAD placement is unnecessary. A panoramic radiograph is all that is routinely necessary.

4) Some papers describe advantages in installing miniscrews tipped in relation to cortical bone. The most cited advantages are improvement of the contact surface with the cortical bone and reduction of the risk of root damage. Why do you suggest the use of a perpendicular position in your placement protocol? Carlo Marassi/Marcos Alan Vieira Bittencourt

The “angled” concept is usually advanced by clinicians using small diameter MSIs – 1.2-1.5 mm in diameter. The rationale for angling an MSI is threefold: A) it places the apex of the MSI between the apices of the roots where there is usually more bone; B) it places the head of the MSI closer to the keratinized tissue; and C) it increases the surface area of the MSI in contact with bone (bone-implant contact).

Although these sound logical, I disagree with them. From a biomechanical standpoint, TADs are designed to control anchorage, and therefore

should usually be placed at the center of resistance, which is not at the apices of the teeth. TADs should be placed where they are needed, not at some irrational location based on fear of hitting a tooth root. Clinically, I have not seen an increase of soft tissue irritation or infection when the MSI head is in alveolar mucosa. Lastly, small diameter MSIs have less bone-implant contact, which increased their chance to fail.

My MSI is 1.8 mm in diameter, which automatically gives it greater bone-implant contact without the need to angle it. To calculate the surface area of the implant component in cortical bone, the following formula is used: $(2) \times (\pi) \times (\text{radius}) \times (\text{height})$. Therefore, a 1.2 mm, 1.5 mm, and 1.8 mm MSI would have the following surface areas assuming they were all placed at the same depth in 1.5 mm thick cortical bone:

- » 1.2 mm = 5.65 mm² surface area;
- » 1.5 mm = 7.07 mm² surface area, or 125% of the 1.2 mm MSI;
- » 1.8 mm = 8.48 mm² surface area, or 150% of the 1.2 mm MSI.

Finally, are dental implants angled? No, because they have their greatest strength when loaded parallel and perpendicular to their long axes, and not oblique to their long axes. Therefore, I believe that MSIs should be placed perpendicular to the bone surface.

5) Do you usually apply distalization mechanics in dentoalveolar Class II patients? If so, are there any criteria that differentiate the choice between an adolescent and an adult? José Nelson Mucha/Marcos Janson

Yes, I distalize in Class II cases. I don't see a big difference between adolescents and adults in this respect. The criteria that I usually use are: What does the face look like? If the mandible is retrognathic and the patient desires facial change, then I will use a Forsus appliance (3M Unitek, Monrovia, CA) on an adolescent or mandibular advancement on an adult.

On the other hand, if the maxillary dentition is protrusive and the mandible is normal, then I will either distalize the upper or extract premolars. I base this decision on the severity of the Class II and the overjet, how much alveolar bone is distal to the upper second molars, and the estimated treatment duration. The larger the overjet and less posterior alveolar bone, then more I will tend to extract. It usually also takes longer to distalize a full step Class II than to retract anterior teeth after extraction, so I will have the patient and/or parents give feedback on the decision as long as it would not lead to deleterious treatment results.

6) How do you proceed in cases where the entire maxillary dentition must be distalized? Carlo Marassi/Carlos Alberto Estevanell Tavares

I have done this several ways: A) placed MSIs in the posterior palate to pull everything back; B) placed MSIs in the anterior palate to push everything back; C) placed MSIs in the posterior maxilla on the facial to pull everything back; and D) placed MSIs in the anterior maxilla on the facial to push everything back. I have found that regardless of whether the MSI is on the facial or palatal, it is most beneficial to place the force on the facial, because it locates the line of force facial to the center of resistance and helps with Class II to Class I molar rotation.

To this point, I have had good success with two specific techniques. The first is to place the MSI between the upper lateral incisor and canine and attach a Forsus appliance (3M Unitek, Monrovia, CA) from the MSI to the upper first molar to distalize the molar, then allow retraction of the canines to Class I, followed by retraction of the anterior teeth after MSI removal (Fig 2). The second is to place the MSI in the palate about the level of the first premolar and about 2-3 mm parasagittally (due to the unfused midpalatal suture in growing patients). Then I attach a prefabricated

transpalatal arch (TPA) from the MSI to the first premolars or canines and use open coil spring on the facial to distalize the molars. Once the molars are Class I, I attach the same TPA from the molars to the MSI to retract that anterior teeth. This is usually better because it only requires one MSI and uses traditional mechanics (Fig 3).

7) When distalizing the mandibular dentition with miniscrews, the most important consideration is its position. How do you determine the exact placement site? José Nelson Mucha

For these cases, I place the MSI in the retromolar area. This region is relatively horizontal with good bone. I have used the external oblique ridge, however, in this location, the cheek usually folds over the head of the MSI and becomes traumatized by the upper buccal cusps in maximum intercuspation or lateral excursive movements.

Another benefit of the retromolar area is that the MSI can be centered buccolingually there and forces attached from the MSI to both the buccal and lingual of the teeth so that the teeth feel a pure posterior force. If desired, the force can be attached only the buccal or lingual of the teeth, which would provide great control if narrowing or expansion were desirable, respectively. Rotation control is also possible with this location (Fig 4).

8) Open bites in adult patients are always a challenge. Do you usually work with posterior intrusion in these cases? How do you select the patients that fit better in this approach? Marcos Janson

I have been using TADs for openbite closure in adults since 2003. For skeletal openbites, the literature suggests that closing an openbite by extruding the anterior teeth with anterior box elastics and/or indiscriminately leveling the occlusal plane

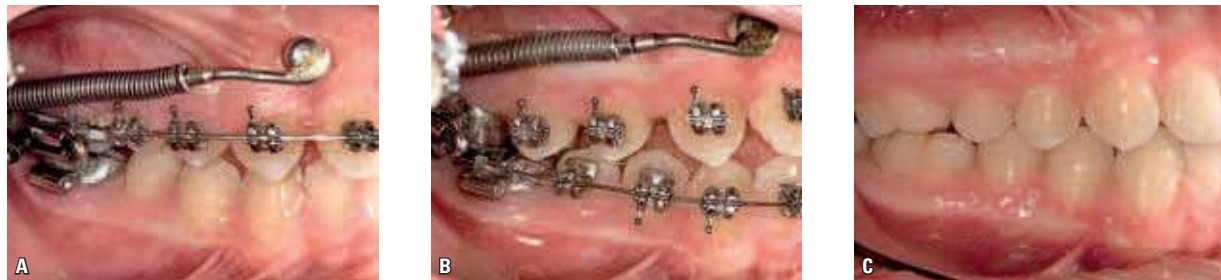

FIGURE 2 - Distalization of maxillary teeth using TAD-Forsus combination. **A)** Buccal at TAD placement; **B)** Buccal after molar distalization; **C)** Buccal at posttreatment.

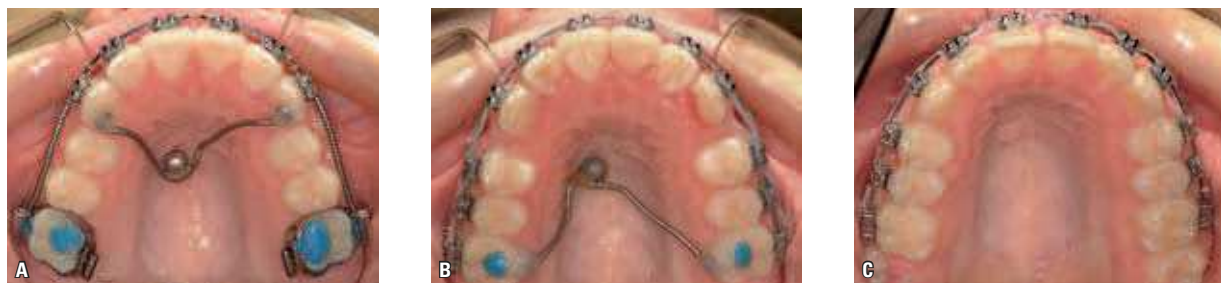

FIGURE 3 - Distalization of maxillary teeth using TAD-TPA combination. **A)** Maxillary occlusal at TAD placement; **B)** Maxillary occlusal after molar distalization; **C)** Maxillary occlusal after anterior retraction and TAD removal.

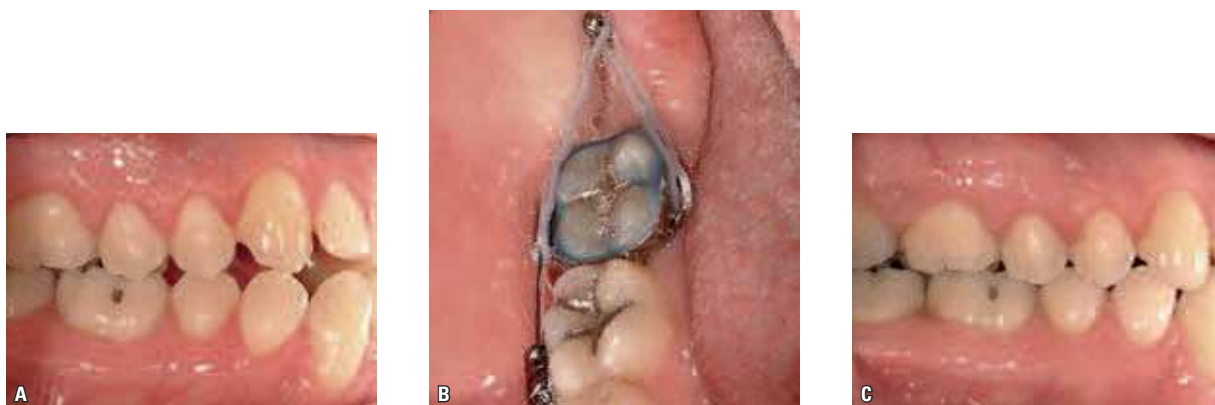


FIGURE 4 - Distalization of mandibular teeth using retromolar MSIs. **A)** Buccal at pretreatment; **B)** Mandibular occlusal at TAD placement; **C)** Buccal at posttreatment.

increases the tendency for incisors to relapse or display root resorption.

Understanding this, I have designed my mechanics to avoid anterior extrusion and maximize posterior intrusion. I start with an initial round NiTi archwire with a step in the archwire at the step in the occlusal plane, which is usually between either the lateral incisor and canine or canine and first premolar. This prevents extrusion of the anterior teeth. Next I work up to a full size rectangular archwire, also with a step in it. Then I take a panoramic radiograph and reposition any non-ideally placed brackets. Next, I section the archwire at the step, so that the anterior teeth are no longer tied to the posterior teeth. I place an MSI as deep in the palate horizontally between the first and second molars with an expanded TPA (the TPA is expanded about 3 mm per side to counter the narrowing effect of intrusion from the palatal side only). The force is applied from the MSI to the TPA to deliver a pure intrusive force to the upper posterior. The upper anteriors do not move. The palate is the ideal location in this situation

because there is better soft tissue apically. Also, the force is palatal to the center of resistance. This helps to seat the lingual cusps, which are usually hanging down in open bite cases (Fig 5).

To date, I have had no problem closing any adult openbite. I have patients 3-4 years in retention and show no relapse.

9) How much do you believe it is possible to intrude a tooth using miniscrews, considering the shortening of the clinical crown?

Carlos Alberto Estevanell Tavares

I don't think there is a limit to how much a tooth can be intruded. I believe there is a distinction, however, on the underlying etiology of the extruded tooth. If it is a supererupted tooth, then biologically there is no reason to believe that intrusion to its pre-extruded position should be difficult. I have intruded supererupted molars as much as 7 mm (Fig 6).

I also have a case with a gummy smile and vertical maxillary excess in which the entire maxilla was intruded about 5 mm. The main criteria is based more on diagnosis and treatment planning than actually intruding the teeth (Fig 7).

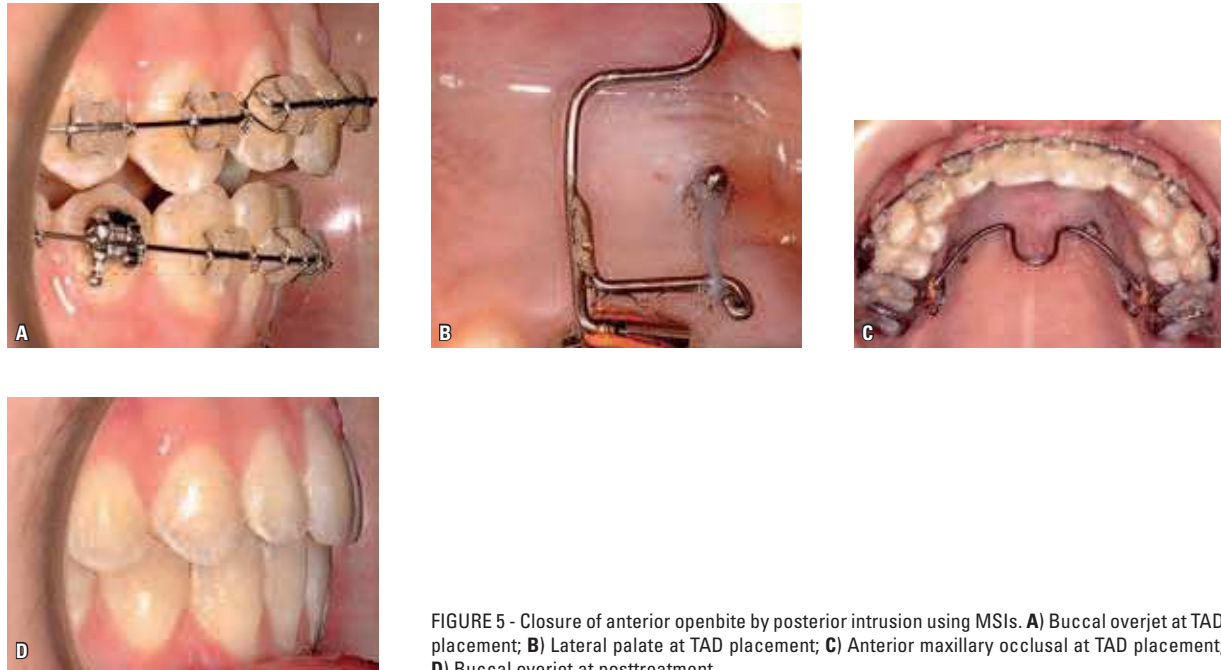


FIGURE 5 - Closure of anterior openbite by posterior intrusion using MSIs. **A)** Buccal overjet at TAD placement; **B)** Lateral palate at TAD placement; **C)** Anterior maxillary occlusal at TAD placement; **D)** Buccal overjet at posttreatment.

10) What is your experience in using mini-screws as anchorage to rapid maxillary expansion? Carlo Marassi

I have used MSIs to correct unilateral crossbites using unilateral palatal expanders. In both cases, I placed two MSIs in the palate on the normal side and fixed the expander from the MSIs to the teeth on the crossbite side. Expansion proceeded normally with significant crossbite correction on the affected side (Fig 8).

11) In what situations do you use elastics instead of NiTi coil springs associated to miniscrews? Carlos Alberto Estevanell Tavares

On all cases, I used power chain initially. The force level is no more than 50-75 g. The literature indicates that 70-80% of all failures occur within

the first 8-12 weeks of MSI placement and loading. I believe this occurs for several reasons. First, the placement protocol is paramount. I think the MSI should be placed drill-free (without a pilot hole), and very slowly/carefully without any wobble, which leads to over enlargement of the implant hole. Second, the initial loading force should be light, not heavy. The first 6-8 weeks, to me, are for stabilizing the MSI and not to move teeth. Therefore, I use elastic force for the first 6-8 weeks, and then move to a coil spring force thereafter as I increase the force level. However, my total force range is usually not more than 100-250 g. The only location I routinely use elastic force for the entire tooth movement is in the anterior region. This is because coil springs tend to irritate the lips in this area.

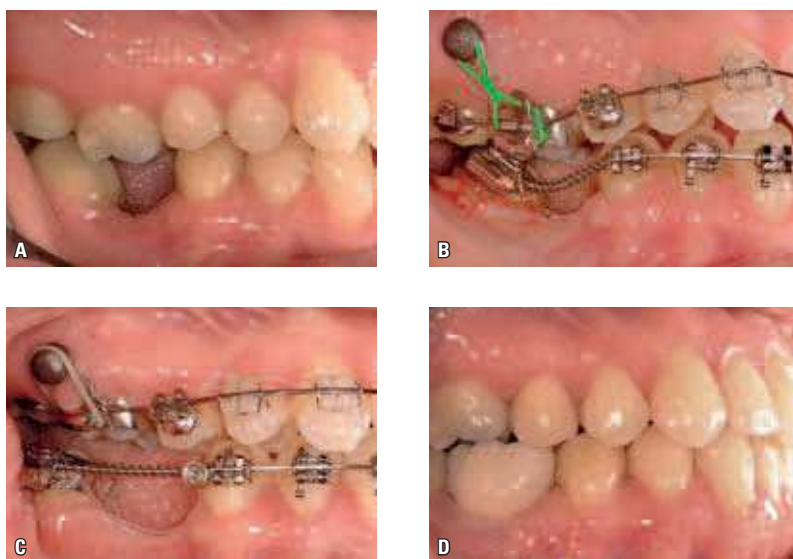


FIGURE 6 - Intrusion of supererupted molars using MSIs. **A)** Buccal at pretreatment; **B)** Buccal at TAD placement; **C)** Buccal at TAD removal; **D)** Buccal at posttreatment.

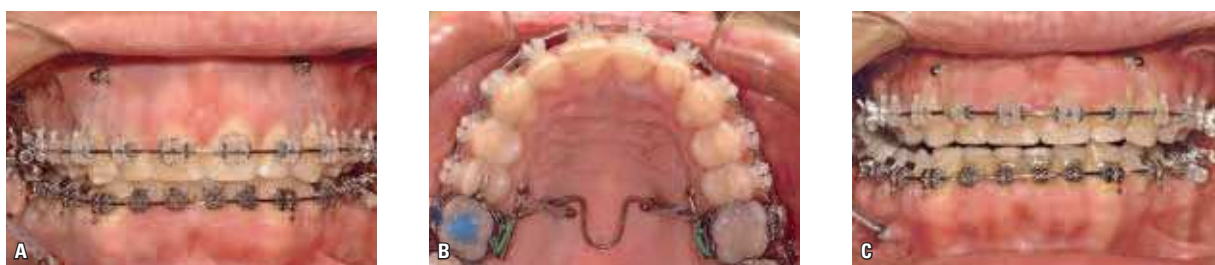

FIGURE 7 - Intrusion of maxillary arch for gummy smile correction using 4 MSIs. **A)** Anterior at TAD placement; **B)** Maxillary occlusal at TAD placement; **C)** Anterior at TAD removal. Note intrusion relative to MSIs.

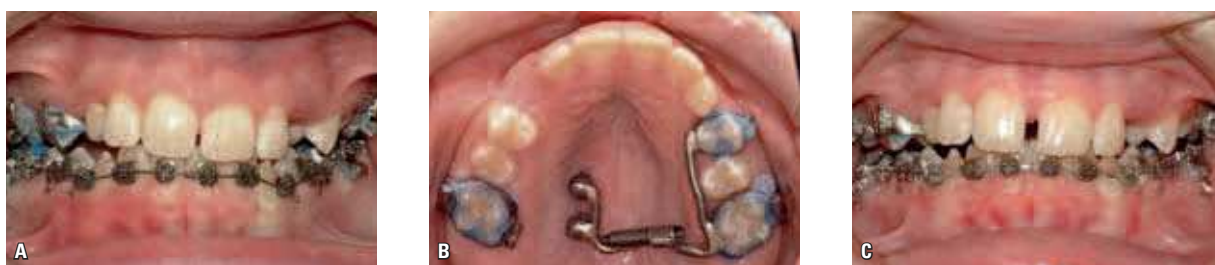

FIGURE 8 - Unilateral palatal expansion using MSIs. **A)** Anterior at TAD placement; **B)** Maxillary occlusal at TAD placement; **C)** Anterior after crossbite correction.

12) Scientific evidences have shown that cortical bone is the main point of failure. Does this mean that miniscrews can be shorter? Maria Tereza Scardua

I agree that the cortical bone, compared to cancellous bone, is more important. My own clinical research indicates a higher success rate with 6 mm, as opposed to 8 mm and 10 mm MSIs. I don't however think we can use MSIs shorter than about 6 mm. The extra length is not needed for bone, but rather for the increased soft tissue thickness in certain regions. For example, I use the 10 mm in the retromolar area and in the lateral palatal wall, where the soft tissue thickness averages 4 mm.

13) Do you follow a protocol to adjust the force you apply at the miniscrew in accordance to each different clinical situation?

Marcos Alan Vieira Bittencourt

I determine my force level primarily based on the number of teeth that I will attach to the MSI. In general I try to stay at a level so that each individual tooth has a force of no more than about 50-75 g applied to it.

14) Publications have shown controversy regarding the increase in success rate of miniscrews with surface treatment. What is your experience with surface treated miniscrews? Carlo Marassi/Maria Tereza Scardua

I have not used any MSI with surface treatment. The rationale with surface treatment—whether additive (surface coating with hydroxyapatite) or subtractive (sandblasting with aluminum oxide)—is to roughen the surface, thereby increasing the chance of osseointegration. I do not see this as a significant benefit, because we eventually want to be able to remove the MSIs. Osseointegrated MSIs are significantly harder to remove than non-integrated MSIs, often requiring the MSI to be trephined out of the bone. Moreover, my total success rate is at 90%. I don't see the potential

increase of several percentage points by using surface treated MSIs neither a significant enough benefit to justify the additional surgical procedure to remove an integrated MSI.

15) What is your clinical procedure in case of miniscrew mobility? Carlo Marassi

As I mentioned, my failure rate is relatively low. So I do not see this situation often. If a MSI has a subtle mobility, meaning I can push on it and see that it has a subtle "give" to it, I will leave it in. In almost all of these cases, I have used the MSI to complete tooth movement as originally intended. If, on the other hand, the MSI is mobile enough that I could remove it with my fingers, then I will remove it. If I still need to use a MSI for anchorage, I will either replace it in another location, or if that is not an option, I will leave the MSI out for 8-10 weeks until the bone has filled in the hole substantially, then replace the MSI in its previous position.

16) You developed an orthodontic implant for Unitek (Unitek Temporary Anchorage Device System). What are the main differences between it and the other miniscrews?

Marcos Alan Vieira Bittencourt

The main benefit of the Unitek Temporary Anchorage Device System (3M Unitek, Monrovia, CA) is that there is only one diameter and three lengths (Fig 9A). We chose a 1.8 mm diameter because it provides greater strength and has been shown to be much more resistance to fracture than smaller diameter implants. Contrary to popular opinion, our 1.8 mm MSI does not have a greater risk of hitting tooth roots. Actually, because of its unique hybrid design, our 1.8 mm MSI has less chance of hitting tooth roots than most 1.5 mm diameter MSIs (Fig 9B).

To explain, the Unitek TAD has a conical component and a cylindrical component. The conical component begins at the apex at 0.35 mm in diameter and gradually increases to the full


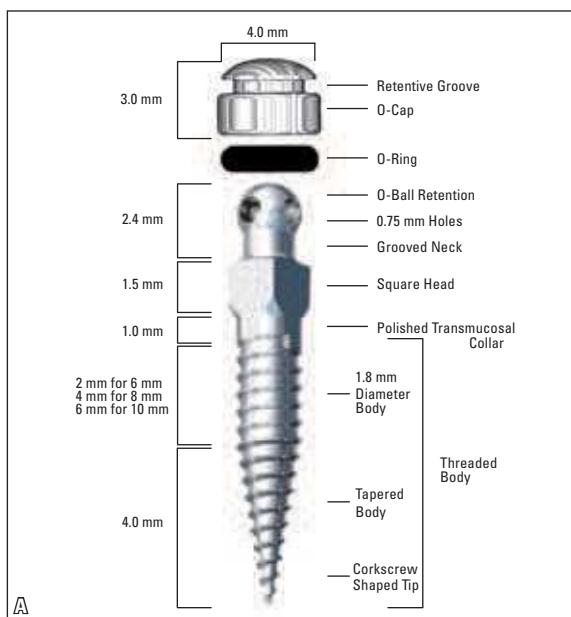


FIGURE 9 - An Unitek TAD. **A)** Major design features; **B)** Comparison of Unitek TAD (silver) and KLS TAD (gold).

1.8 mm cylindrical diameter 4 mm up from the apex. This is the part that makes the MSI sharp and capable of perforating the cortex. This is also the component that resides within the cancellous bone between the tooth roots—so there is less chance of hitting tooth roots. The cylindrical component is designed to reside within the cortical bone, thereby increasing the surface area and bone-implant contact. Therefore, it has the best of both worlds—a smaller diameter between tooth roots, and a larger diameter in cortical bone where there is no risk of hitting tooth roots.

17) Do you have any experience in using miniscrews as provisional teeth in cases of congenital absence, in growing patients, who have to wait for osseointegrated implant? If so, what is the bone response around it? Does it maintain horizontal thickness and allow vertical growth? Marcos Janson

Yes, I have a case where I have used a MSI as a temporary lateral. She has had the temporary implant for 5 years now and the implant has not submerged, the horizontal and vertical bone levels look better than they did initially (Fig 10).

Obviously, we need to look at this on a larger scale with prospective clinical trials, but the initial results are promising. For those interested in this case, I have it full documented on my continuing education website, www.CopestheticCE.com,

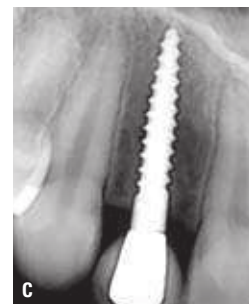
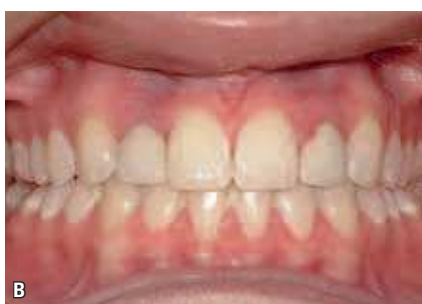
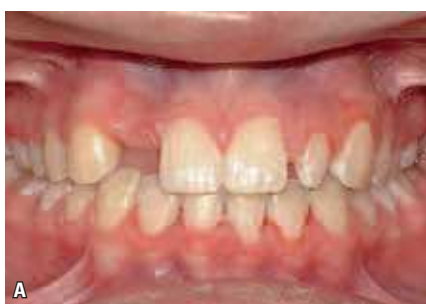FIGURE 10 - Temporary lateral incisor replacement. **A)** Anterior at TAD placement. **B)** Anterior at 5 year retention. **C)** Periapal radiograph at 5 year retention.

where I have listed the protocol and products necessary for temporary restoration of a congenitally missing lateral incisor. In addition, much of the information covered in the interview can be

found in greater detail on the website.

All photos were reprinted with permission from www.CopestheticCE.com.

Carlos Alberto Estevanell Tavares

- PhD and MSc in Orthodontics, UFRJ.
- Teacher of the Specialization Course in Orthodontics, ABO-RS.
- Director of the Brazilian Board of Orthodontics and Dentofacial Orthopedics.

Marcos Janson

- MSc and Specialist in Orthodontics, Bauru-USP.
- Author of the book entitled "Adult Orthodontics and Interdisciplinary Treatment", Dental Press Publishing.

Carlo Marassi

- MSc in Orthodontics, Center for Dental Research - Campinas.
- Specialist in Orthodontics, Bauru-USP.
- Coordinator of the Specialization Course in Orthodontics, Fluminense School of Education.
- Scientific Director of the Straight-Wire Group of Rio de Janeiro.
- Vice-President of the Society of Orthodontics of the State of Rio de Janeiro.

Maria Tereza Scardua

- MSc in TMD and OFP, UNIFESP.
- Specialist in Orthodontics, Bauru-USP.
- Postgraduate Health Based on Scientific Evidence, Syrian-Lebanese Hospital (SP).
- Diplomate, Brazilian Board of Orthodontics and Dentofacial Orthopedics.

José Nelson Mucha

- PhD and MSc in Orthodontics, UFRJ.
- Professor of Orthodontics, UFF (Niterói, RJ).
- Ex-President of the Brazilian Board of Orthodontics and Dentofacial Orthopedics.

Marcos Alan Vieira Bittencourt

- PhD and MSc in Orthodontics, UFRJ.
- Radiology Specialist, UFBA.
- Associate Professor of Orthodontics, UFBA.
- Coordinator of the Specialization Course in Orthodontics, UFBA.
- Diplomate, Brazilian Board of Orthodontics and Dentofacial Orthopedics.

Contact address

Jason Cope
7015 Snider Plaza Suite 200
Dallas TX 75205
E-mail: info@CopestheticCE.com