

# Cephalometric evaluation of skeletal alterations induced by Herbst appliance during mixed dentition

Luana Paz Sampaio<sup>1</sup>, Dirceu Barnabé Raveli<sup>2</sup>, Ary dos Santos-Pinto<sup>2</sup>,  
Denise Rocha Goes Landázuri<sup>3</sup>, Taísa Boamorte Raveli<sup>4</sup>

**Objective:** The present prospective clinical study was designed in order to evaluate horizontal and vertical skeletal alterations induced by the use of Herbst appliance in individuals with Class II, division 1 malocclusion during mixed dentition stage.

**Methods:** The sampling consisted of 15 pre-pubertal individuals (12 boys and 3 girls; initial age 9 years and 6 months), who were treated with Herbst appliance for a period of 7 months. The effects of the treatment were compared to a group of 15 individuals with Class II, division 1 malocclusion (8 boys and 7 girls, initial age averaged 9 years and 1 month), orthodontically untreated, who were followed up for a period of 12 months. Statistical analysis was performed with Student's t-test with significance level at 5%.

**Results:** It was showed that the treatment with Herbst appliance in mixed dentition stage has restricted maxilla growth. Mandibular and palatal planes have not undergone significant alteration; however, anterior and posterior facial heights have increased significantly. Facial convexity and maxillomandibular relationship were altered positively. Mandible has positioned significantly forward and its effective length increased 2.5 times more than the increase observed in control group.

**Conclusion:** It was possible to conclude that Herbst appliance was able to provide satisfactory results in individuals during mixed dentition stage.

**Keywords:** Herbst appliance. Class II malocclusion. Early treatment.

<sup>1</sup> MSc and PhD in Orthodontics, Faculty of Dentistry of Araraquara-UNESP. Assistant Professor of Specialization in Orthodontics, GESTO/FAMOSP-Araraquara.

<sup>2</sup> Associate Professor of Orthodontics, Faculty of Dentistry of Araraquara-UNESP.

<sup>3</sup> MSc and PhD student, Faculty of Dentistry of Araraquara-UNESP.

<sup>4</sup> MSc in Orthodontics, Faculty of Dentistry of Araraquara-UNESP.

**How to cite this article:** Sampaio LP, Raveli DB, Santos-Pinto A, Landázuri DRG, Raveli TB. Cephalometric evaluation of skeletal alterations induced by Herbst appliance during mixed dentition. *Dental Press J Orthod*. 2012 Mar-Apr;17(2):140-50.

**Submitted:** August 25, 2008 - **Revised and accepted:** March 09, 2009

» The authors report no commercial, proprietary, or financial interest in the products or companies described in this article.

» Patients displayed in this article previously approved the use of their facial and intraoral photographs.

**Contact address:** Luana Paz Sampaio  
Av. Portugal, 887 – Centro – CEP: 14801-075 – Araraquara/SP – Brazil  
E-mail: lusampaz@hotmail.com

## INTRODUCTION

Among the proposed treatment methods for the Class II malocclusion which are intended to stimulate the growth of mandible, Herbst appliance has its prominence. Initially developed in 1905 by the German Emil Herbst, it was popularized by Hans Pancherz in the end of the 70's.<sup>13</sup> This appliance is characterized by presenting a bilateral telescopic mechanism that keeps the mandible anteriorly positioned on continuous basis during the rest, and also all mandibular functions.<sup>25</sup>

With respect to the ideal time for beginning the treatment of Class II malocclusion, the literature highlights the moment near the peak of growth, at the beginning of the permanent dentition stage. The optimization of the results might be related to the magnitude of the orthopedic response and to the long-term stability of changes induced, being this factor conditioned to the degree of intercuspation obtained after treatment.<sup>5,6,14,16</sup> These studies have shown that the orthopedic effect is more significant, overcoming dental compensation, when appliance is installed at the time of the peak of height growth. However, we can see that in the literature there are diversified opinions in terms of treatment time of mandibular deficiency with the Herbst appliance. The use of this appliance in young permanent dentition, at the time of circumpubertal facial growth has been suggested by some authors.<sup>15</sup> In case of severe Class II malocclusions, the Herbst appliance has been recommended<sup>28,29</sup> yet in deciduous dentition stage. Other authors<sup>8,22</sup> have used this appliance even after adolescence.

However, the severe Class II malocclusions are considered a concern factor for orthodontists due to the numerous esthetic and psychological problems that may be caused to the child, besides increasing the risk of fractures in the teeth, specially of maxillary central incisors.<sup>25</sup> The main advantage of the early treatment in class II malocclusions due to mandibular deficiency is the consequent psychosocial relief of the patient and parents. Moreover, it reduces the risk of trauma in maxillary incisors and achieves a class I relationship in early age.<sup>25</sup> The disadvantage would be the prolonged follow up. Despite the active stage of treatment be quick, ranging from 6 to 12 months, it is necessary the use of removable functional appliances

as retainers until the end of the growth period, in order to minimize the potential relapse.<sup>25</sup>

During the past 20 years, many studies have been conducted to assess the effects of Herbst appliance over craniofacial skeleton, during the Class II treatment. However, only a few studies have evaluated the effects of Herbst appliance in mixed dentition stage.<sup>1,3,28,29</sup> The vast majority of researches investigated the effects of treatment in permanent dentition. For these reasons, this prospective clinical study aimed to measure the horizontal and vertical skeletal effects induced by Herbst appliance in the early treatment of Angle Class II malocclusion.

## MATERIAL AND METHODS

### Characterization of the sample

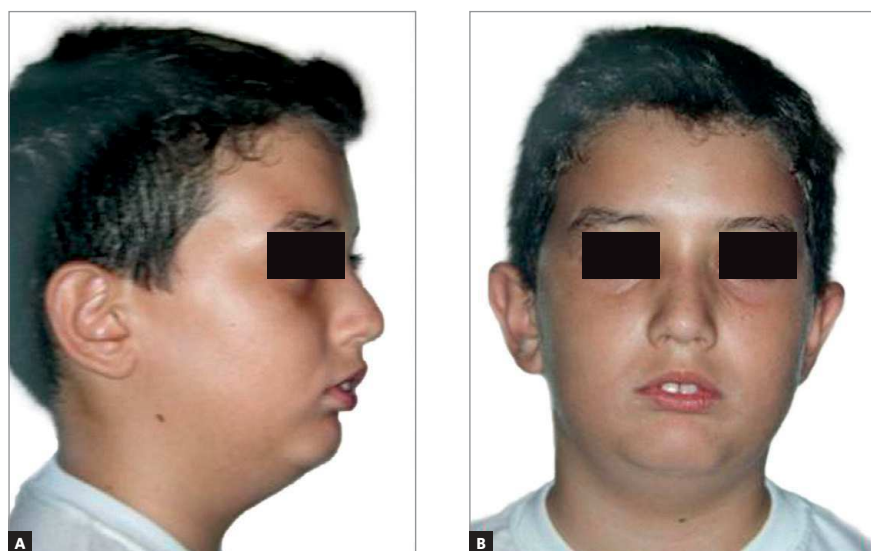
The treated group was composed of 15 Caucasian children (12 boys and 3 girls), ranging in age from 8 to 10 years (average initial age of 9.4 years and standard deviation of 0.64; average final age of 10.1 years and standard deviation of 0.64). Individuals were selected based on the following criteria: Class II facial pattern, associated with mandibular retrusion; Class II division 1 malocclusion; permanent maxillary and mandibular central and lateral incisors erupted or in eruption; mixed dentition; absence of severe crowding in the lower arch and the absence of transverse problems. Facial morphological pattern was determined by the Facial Height Ratio of Jarabak. In this study, 60% of individuals presented mesofacial pattern, 33.33% brachyfacial pattern and 6.66% dolichofacial pattern. This study has been approved by the Ethics Committee in Research (protocol 73/04).

To determine the Class II facial pattern and the Class II malocclusion, both face and occlusion were clinically analyzed. In this way, there was a certain subjectivity, because measurable data obtained from facial radiographs were not used. In facial analysis were observed some characteristics that helped to determine the Class II facial pattern, like morphological evaluation of the nasolabial angle (straight, obtuse and acute) and length of mentocervical line. In this way, individuals who have a convex profile, straight nasolabial angle or slightly acute and short mentocervical line, were classified as Class II facial pattern (Figs 1A and 1B). The Class II division 1 malocclusion was determined by the sagittal position of permanent

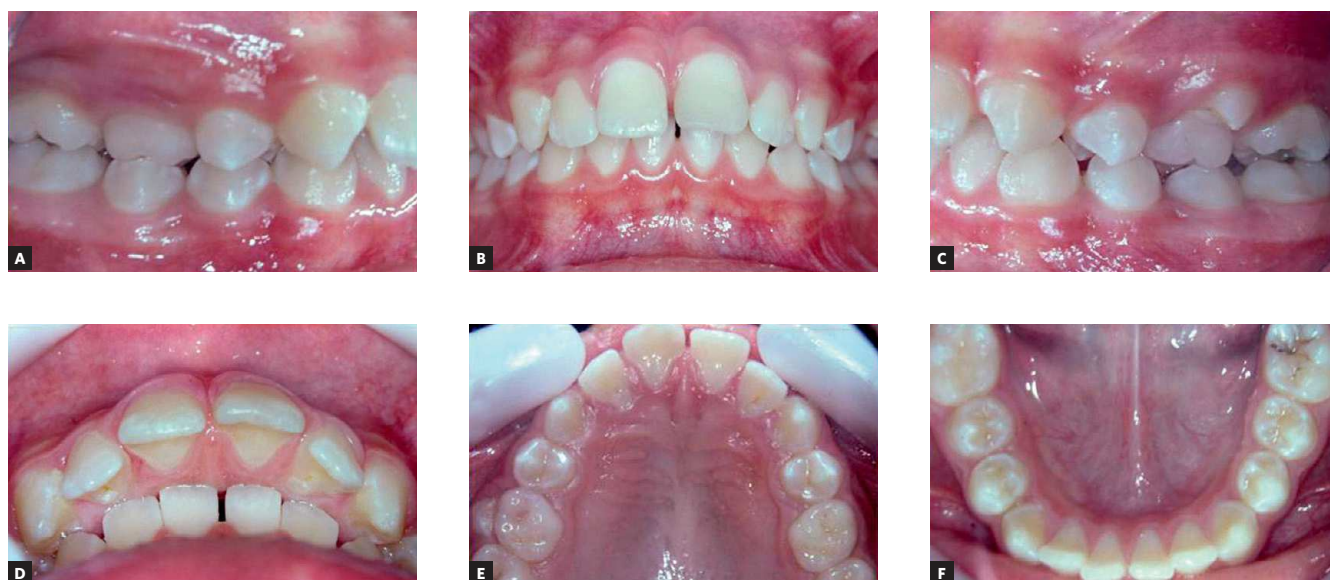molars and permanent or deciduous canines, and by the overjet. Individuals with molar and canines in Class II, equal to or higher than the half of a cusp, and overjet equal to or greater than 4 mm, were included in the sample (Fig 2).

Patients were treated with modified Herbst appliance (Fig 3), where permanent maxillary first molars were banded and united to each other by a transpalatal bar, welded to bands with a 2 mm distance from palate<sup>7</sup> (Fig 4A). For mandibular anchorage was used

a Nance modified lingual arch, constructed with 1.2 mm steel wire welded to permanent mandibular first molars bands. A cantilever with extension up to the region of deciduous or permanent canines was welded in the buccal surface of the mandibular first molars bands. The link between the cantilever and the lingual arch was made in the region of canines and deciduous first molars or permanent canines and first premolars, using a 0.9 mm wire in order to avoid occlusal interferences<sup>18</sup> (Fig 4B).

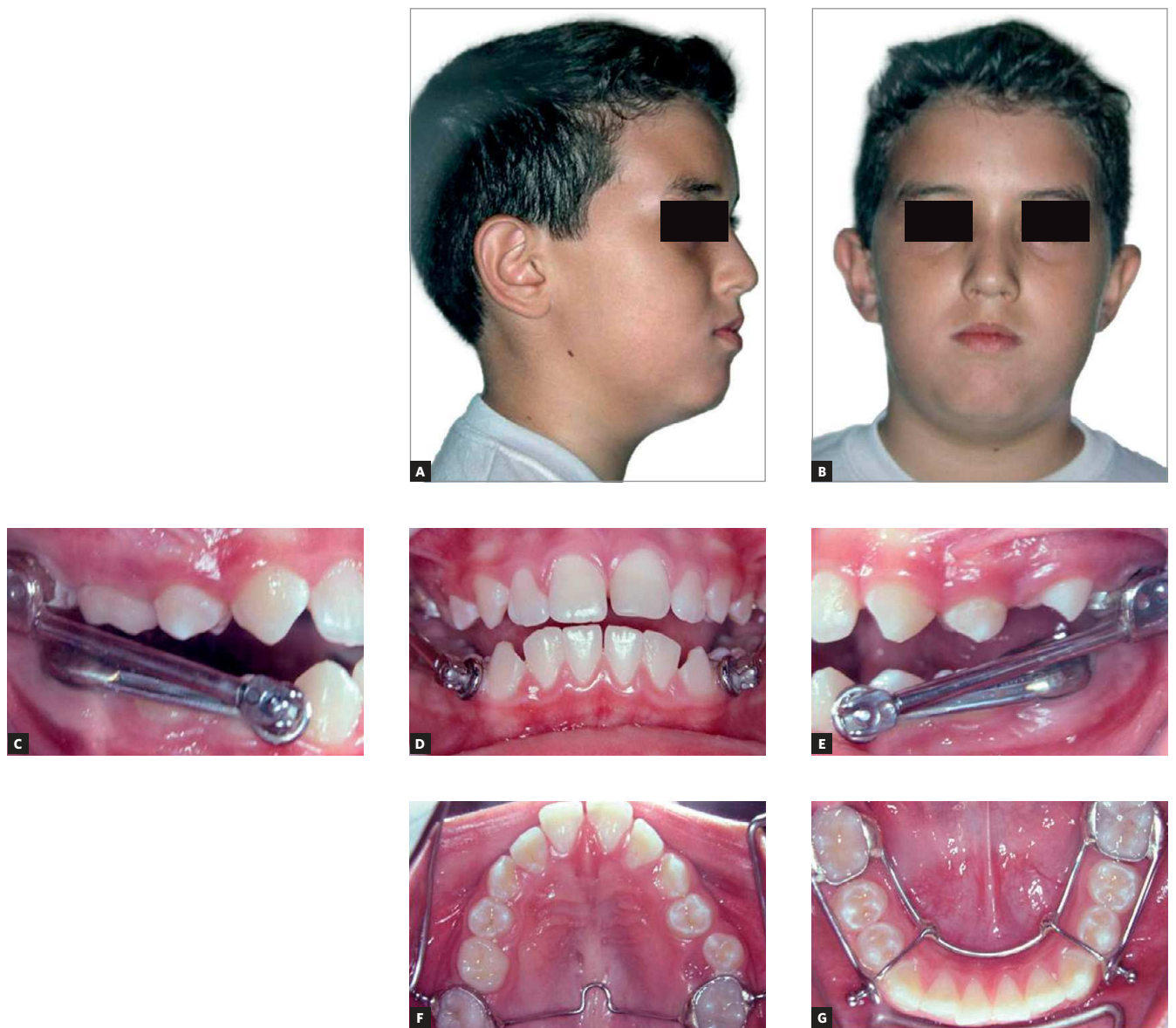


**Figure 1** - Initial extraoral photographs: **A)** profile, **B)** frontal.

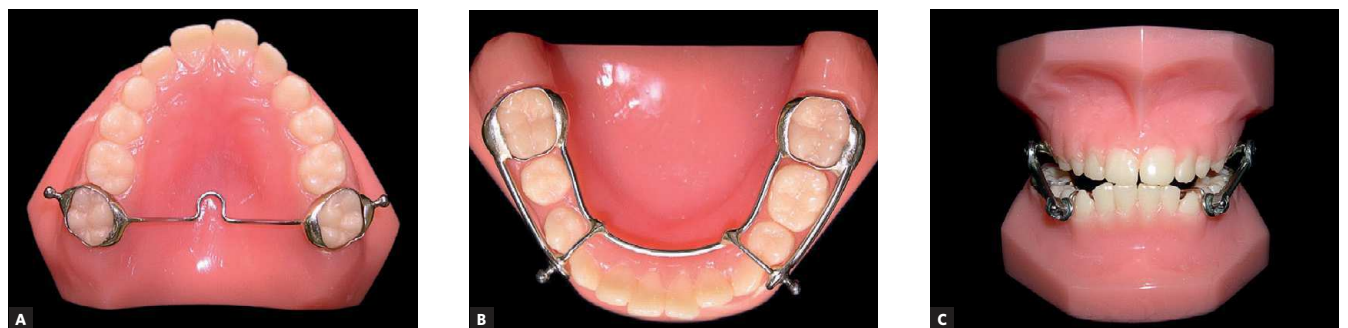


**Figure 2** - Initial intraoral photographs: **A)** right side; **B)** frontal; **C)** left side; **D)** overjet; **E)** upper occlusal; **F)** lower occlusal.





**Figure 3** - Extraoral photographs of the patient with the Herbst appliance installed: **A)** profile, **B)** frontal. Intraoral photographs of the Herbst appliance installed: **C)** right side, **D)** frontal, **E)** left side. Occlusal photographs of the anchorage system used: **F)** upper, **G)** lower.

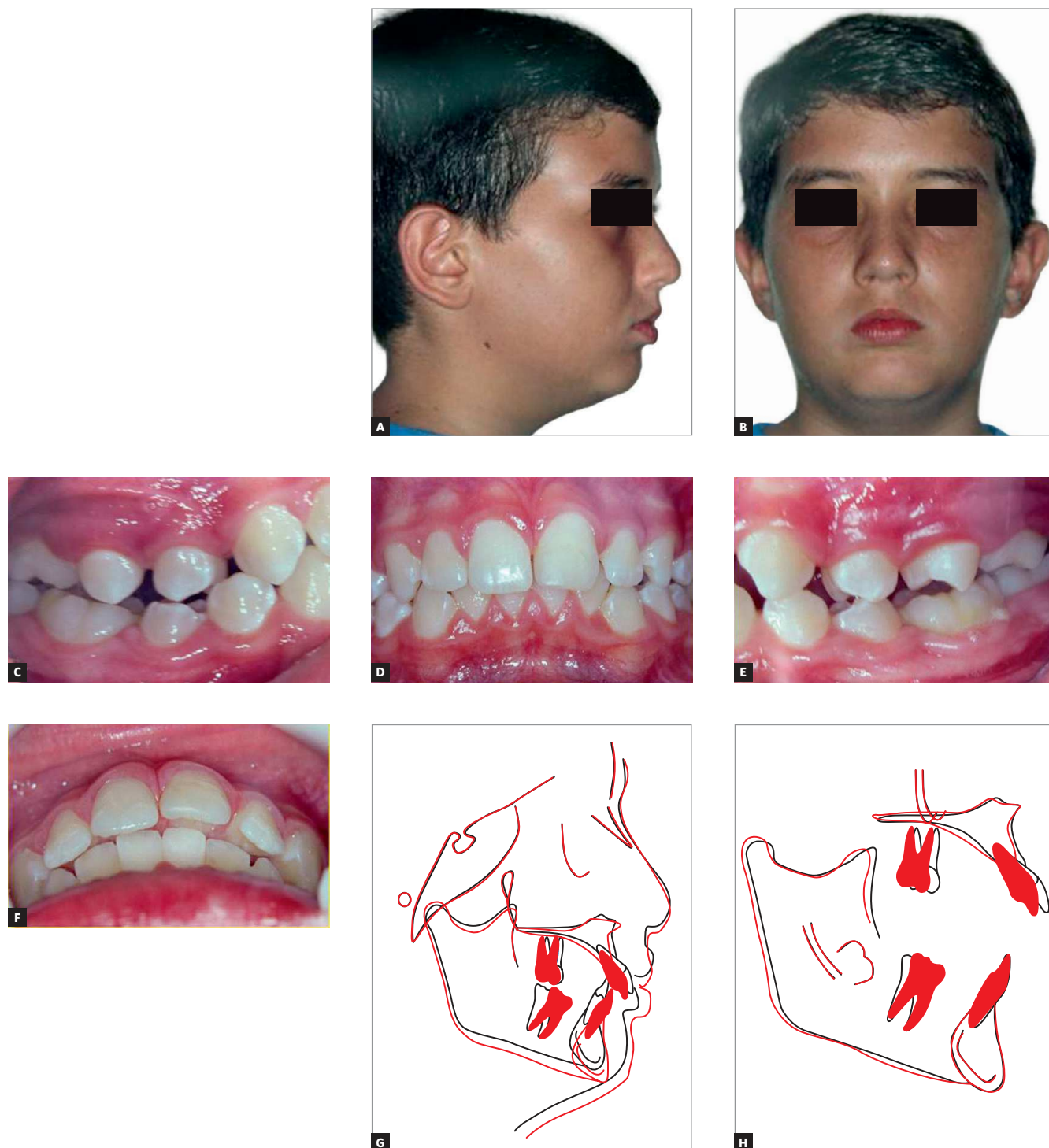


**Figure 4** - **A)** Upper anchorage; **B)** Lower anchorage; **C)** Single mandibular advancement.

The anterior projection of the mandible with the Herbst appliance, was performed according to Pancherz,<sup>14</sup> i.e., single mandibular advancement until the incisors were in an end-to-end relationship (Fig 4C). The appliance was used for a period of 7 months (Fig 5). At the end of the active stage of treatment it was

verified that the centric occlusion was coinciding with the maximal intercuspation in all patients.

The control group, selected from the files of Burlington Growth Centre, located at the University of Toronto, Canada, involved 15 children (7 girls and 8 boys). The criteria for selection of the control group



**Figure 5** - Final extraoral photographs: **A)** profile, **B)** frontal. Final intraoral photographs: **C)** right side, **D)** frontal, **E)** left side, **F)** overjet. Cephalometric tracings superimpositions: **G)** total, **H)** partial superimpositions of the maxilla and mandible.

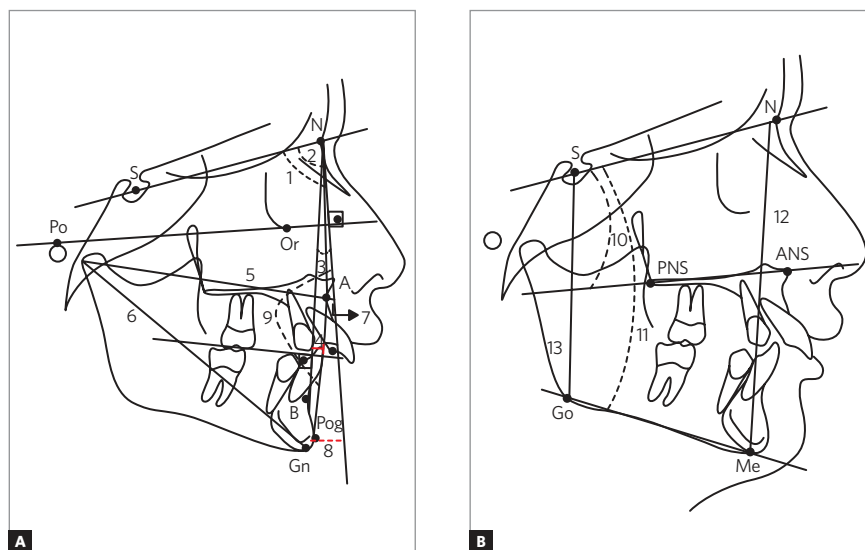
were: Class II facial pattern, associated with mandibular retrusion; Class II division 1 malocclusion; erupted permanent maxillary and mandibular central incisors; mixed dentition and absence of previous orthodontic treatment. The mean initial age of the control group was 9 years and 1 month (standard deviation 0.09) and the mean final age was 10 years (standard deviation 0.05). In relation to facial morphological standard of the control group, 73% of individuals presented mesofacial pattern, 20% brachyfacial pattern and 7% dolichofacial.

The skeletal age of both groups was verified through radiographs in lateral standard, determining skeletal maturation stage using cervical vertebrae.<sup>10</sup> The determination of bone age was performed by the same operator blind to the patient status, which reduces the effect of subjectivity of this evaluation. Individuals in this study were located in the stages 1 and 2 of maturation, i.e., before the peak of pubertal growth.<sup>2,12</sup>

Two profile radiographs in maximal habitual intercuspation were obtained for each individual in the experimental group, named  $T_1$ , at the beginning of treatment and  $T_2$ , 7 months after the treatment. The X-rays were carried out using an X-ray machine (Rotograph Plus, model MR05, regulated to 85 Kvp and 10

mA and exposure time of 0.5 seconds). For the control group were obtained two profile radiographs in maximal intercuspation, named:  $T_1$ , at 9 years of age and  $T_2$ , at 10 years of age. The radiographs were obtained with equipment of brand Keleket<sup>TM</sup> set to 120 Kpv, 25 mA and exposure time of 0.3 seconds.

Although these radiographs were obtained by different X-ray machines, the correction of image magnification was not conducted. The magnification of the image, i.e., the percentage of magnification on the experimental sample was 10%, representing a magnification of 0,1000 cm (1,000mm)<sup>23</sup>. In the control group, the percentage of magnification reported was of 9.84%, according to the records of Burlington Growth Centre.<sup>17</sup> The magnification percentage difference between samples would be 0.16%, what would not affect the comparison of variables obtained from radiographs taken in the different X-ray machines. This difference in magnification would correspond to a difference in magnification between X-rays of 0.0016 cm (0.016 mm). All radiographs were traced manually by a single operator. The points were typed into Numonics AccuGrid digitizer and evaluated by means of Dentofacial Planner Plus 2.01 computer software to obtain the cephalometric measurements (Fig 6).



**Figure 6 - A)** Horizontal skeletal measurements: 1= SNA; 2= SNB; 3= ANB; 4= AO-BO; 5= Co-A; 6=Co-Gn; 7= A-Nperp; 8= Pog-Nperp; 9= NAPog. **B)** Vertical skeletal measurements: 10= SN.PalP; 11= SN.GoMe; 12= S-Go; 13= N-Me; 14= SGo/NMe.



## RESULTS

To assess the possible occurrence of measurement errors, all tracings were typed again and measured by the same operator, with a range of 2 weeks between the first and second evaluation. It was used intraclass correlation coefficient (ICC) to evaluate the error of method (reproducibility). The results indicated that the measurement process was highly accurate because the expected value of the ICC was, at least, 0.983 and for most variables the ICC was above 0.99.

To compare the measurement changes, with and without treatment, it was necessary to eliminate the time difference effect between measurements made in the experimental and control group. To do so, measurement changes were annualized.

To assess the data, the following statistical tests have been conducted:

a) Student's t-test for the average equality of two independent populations – to examine the hypothesis that the average of each measurement of control group is equal to the experimental group at the beginning of treatment (Table 1).

b) Student's t-test for average equality of two populations with independent samples – to examine the hypothesis that the mean changes observed in a cephalometric measurements between times 1 and 2 are equal in the control group and the experimental group (Table 2).

The assessment of equivalence between control and experimental groups, regarding the measurements of interest at the beginning of the study, (Table 1) showed that there is little cephalometric difference before treatment between groups, with only 3 of 14 variables showing statistically significant differences.

## DISCUSSION

### a) Sagittal skeletal changes

After the one-year assessment period of the treated group, we noticed that the maxillary growth-related variables (SNA and A-Nperp) presented a decrease of 1.3°/year and 1.2 mm/year, respectively, which was not statistically significant. When comparing these changes with those observed in the control group, that was just 0.21°/year and 0.26 mm/year, it can be stated that the Herbst appliance presented a tendency to restrict the anterior growth of maxilla. These data are in accordance with other studies in

the literature<sup>13,15,18,27,30</sup>, since they have shown that the Herbst appliance provides a limited skeletal effect on the maxillary complex. However, when one considers the variable Co-A, we noted that there was a significant growth constraint of 2.23 mm/year in maxillary growth, while in the group without treatment there was a tendency to increase the effective length of the maxilla. This result confirms the fact that there was a restriction of the maxillary growth. Another study<sup>29</sup> reported that the maxilla was affected by the treatment with the Herbst appliance associated with the extraoral appliance, since the position of the point A was changed in the posterior direction about 1.5 mm in individuals with mixed dentition. Similarly, other authors<sup>3</sup> concluded that early treatment with Herbst appliance restricted the anterior sagittal displacement of point A about 1.2 mm.

Even considering the probable skeletal changes, SNB, Pog-Nperp and Co-NG measurements were assessed, to identify the effect of the appliance in the mandibular bone. While the control group showed a decrease on SNB angle (0.06°/year), the experimental group showed a statistically significant increase of 1.8°/year, which indicated that the use of this orthopedic appliance intensified the effect of the forward displacement of the mandible in relation to the base of the skull. When assessing the measurement Pog-Nperp, we found a significant reduction in the degree of retrusion of pogonion to the Nperp line of 3.01 mm/year. Meanwhile, the control group showed a reduction of only 0.21 mm/year. With respect to the effective length of the maxilla (Co-NG) it was noticed that both experimental and control groups showed a significant increase of this measure. Nevertheless, the experimental group (4 mm/year) showed an increase 2.5 times greater than the control group (1.57 mm/year). Thus, in our study of Herbst appliance was able to induce an additional mandibular growth. These results confirm the findings found in the literature<sup>4,9,11,13,14,15,18,26,27,28,30</sup> with regard to immediate mandibular skeletal effects induced by Herbst appliance.

One of the questions of this study was the possible interference of the Herbst appliance in the mandibular growth potential of individuals in early stages of occlusion development, i.e., does the amount of increase in mandibular length is similar to that of those individuals treated with the Herbst appliance

**Table 1** - Mean and standard deviations in the experimental and control groups and mean differences between measurements before treatment, and Student's t-test for the difference between measures.

Measure	Experimental group		Control group		Mean of differences	p
	Mean	sd	Mean	sd		
SNA	82.38	3.30	79.90	2.98	2.47	0.040
A-Nperp	-0.63	3.08	-2.89	2.75	2.26	0.043
SN.PalP	6.10	2.42	8.32	2.53	-2.22	0.020
Co-A	88.87	4.71	87.23	3.40	1.64	0.284
SNB	76.69	2.79	75.27	1.94	1.43	0.115
Pog-Nperp	-10.88	5.94	-12.38	3.68	1.49	0.415
SN.GoMe	33.61	3.61	34.80	3.53	-1.19	0.369
Co-Gn	104.88	5.12	104.84	3.53	0.04	0.982
ANB	5.68	2.19	4.65	1.70	1.03	0.163
AO-BO	3.06	1.79	1.92	2.51	1.14	0.165
NAPog	169.85	5.71	171.92	4.11	-2.07	0.265
S-Go/N-Me	64.32	2.52	64.23	2.32	0.09	0.923
N-Me	109.85	7.97	105.36	4.56	4.49	0.071
S-Go	70.60	5.08	67.67	3.35	2.93	0.072

**Table 2** - Means and results of Student's t-test of equality of means in the Experimental group and control group, each of the variables under study.

Measure	Means		p
	Experimental group	Control group	
SNA	-1.30	-0.21	0.182
A-Nperp	-1.20	-0.26	0.217
SN.PalP	0.59	-0.27	0.222
Co-A	-2.23	0.93	0.002
SNB	1.80	-0.06	0.002
Pog-Nperp	3.01	-0.21	0.012
SN.GoMe	0.16	-0.05	0.791
Co-Gn	4.10	1.57	0.008
ANB	-3.09	-0.17	0.000
AO-BO	-4.60	0.16	0.000
NAPog	6.03	0.34	0.000
S-Go/N-Me	0.76	-0.15	0.221
N-Me	4.11	1.70	0.001
S-Go	3.53	0.92	0.001

at the adolescence period? Significant short term increases in the length of the mandible have been reported in adolescents in approximately 2.2 mm<sup>13,14</sup> and 3.4 mm.<sup>30</sup> The literature has shown favorable and clinically significant mandibular growth in individuals treated with the Herbst appliance, who started the treatment in stages 3 and 4 of skeletal maturation of cervical vertebrae, i.e., at the peak of

pubertal growth.<sup>5</sup> According to the analysis of skeletal maturation using cervical vertebrae in our study, all patients started treatment before the outbreak of pubertal growth. Thus, it is worth mentioning that the magnitude of skeletal mandibular effects in our study was similar to that found in individuals treated around the peak of pubertal growth, when one might expect a more significative orthopedic effect.<sup>8,9,15,16,19</sup>



Due to the restriction of maxillary growth and the effect of mandibular growth stimulus, we observed a significant reduction in maxillomandibular relationship (ANB:  $3.09^\circ$ /year; AO-BO: 4.6mm/year). When the results of the evaluated groups were compared, we noticed that the experimental group presented a similar alteration to the control group, however in a larger magnitude, what denotes a positive effect of use of this device in terms of improving sagittal maxillomandibular relationship. Croft et al<sup>3</sup> when comparing the ANB angle change in mixed dentition patients treated with Herbst appliance and others monitored without treatment, they obtained a reduction of maxillomandibular relationship of  $1.4^\circ$  greater than the experimental and control group. Reduction in ANB angle of  $3.26^\circ$  and of  $1.3^\circ$  in 12 months of treatment with the Herbst appliance has been described in the literature.<sup>9,18</sup>

When evaluating the behavior of facial skeletal convexity, it was identified an increase in the NAPog angle of  $6.03^\circ$ /year, leading to a decrease in the facial convexity. The changes observed in the experimental group were similar to the control group, nevertheless, on a larger scale. Our result is in agreement with other studies<sup>3,18</sup> that observed a reduction of 4.23 and  $2.2^\circ$  in this angle in a sample treated with Herbst appliance.

Thus, according to the results of our study, there was a significant improvement in the sagittal relation between apical bases. The reduction of about 4.6 mm in the maxillomandibular relationship (AO-BO) can be explained by the significant restriction of 1.2 mm in the maxillary growth (A-Nperp) and by the anterior displacement of 3.01 mm of Pogonion (Pog-Nperp). This fact is confirmed when assessing the ANB angle, that showed a decrease of  $3.09^\circ$ , represented by maxillary growth inhibition (SNA:  $-1.3^\circ$ ) and by the anterior displacement of the mandible (SNB:  $1.8^\circ$ ).

## b) Vertical Skeletal Changes

The influence of functional or fixed appliances in the vertical relation of the bone bases is a controversial subject in literature.<sup>3,9,18,20,21,28</sup> In cases of hyperdivergent growth pattern patients, functional appliances are not recommended because these appliances can cause a subsequent clockwise mandibular rotation<sup>20</sup> and, consequently, may worsen the facial esthetics. On the other hand in patients with mesofacial growth pattern, the mandibular plane

angle, on average, does not seem to be affected with the Herbst appliance.<sup>1,3,9,11,18,19,28,30</sup> However, some authors found no significant differences regarding the magnitude of vertical skeletal changes in hypodivergents and hyperdivergents patients treated with the Herbst appliance<sup>21,24,30</sup>.

Our study showed a significant increase in the anterior (N-Me: 4.11 mm/year) and in posterior facial height (S-Go: 3.53 mm/year). The changes observed in the experimental group were similar to the control group, however, in a larger magnitude. Increase of facial height as a result of treatment with the Herbst appliance was found on some researches.<sup>9,28</sup> However, a study<sup>1</sup> related the absence of significant changes in anterior and inferior facial height in individuals treated with Herbst appliance. It is interesting to observe that despite the increased facial height in our study that is favorable to the esthetic of the patient, the mandibular plane angle (SN.Go.Me) did not change significantly in the treated ( $0.16^\circ$ /year) and in the untreated group. These data are in accordance with the findings of literature.<sup>1,3,4,9,11,18,19,26,28,30</sup> The results of this study showed that the use of the Herbst appliance did not change the pattern of rotation of mandibular plane.

In relation to the palatal plane, our results showed that the treated group did not show a significant increase ( $0.59^\circ$ /year) of this plane from the base of the skull. The change observed in the experimental group was not similar to the control group. This variable in the control group also presented a significant change. Our results are consistent with other papers<sup>1,5,6,13,19</sup> that also did not observe changes in palatal plane in patients treated with the Herbst appliance.

According to the results of vertical skeletal changes in our study, we could verify that the mandibular plane presented a similar behavior to the palatal plane, that is, a tendency toward maintenance of initial values, in a comparable way to the control group. As for anterior and posterior facial heights, our study showed that there was a significant increase in the use of this appliance, indicating a harmony in the increase of vertical dimensions. These data suggest that the use of Herbst appliance in patients with excessive facial height should be performed with caution, since this appliance might increase even more the facial height. In this way, when a professional uses the Herbst appliance in patients with increased facial height, it would

be wise to use an anchorage structure with occlusal coverage in order to obtain a better control of the vertical growth of bone bases.<sup>5,9,24,27,30</sup>

The results of this study showed that the Herbst appliance was able to satisfactorily treat Class II malocclusion in pre-puberty subjects. However, it is worth to notice that the choice of the ideal time to begin the treatment of Class II it is still a critical point in orthodontic planning. Therefore, the advantages and disadvantages of early treatment should be carefully considered before starting treatment. In case of early treatment, it is worth to notice the importance of the prolonged monitoring these patients to mitigate the potential for relapse.<sup>3,25,29</sup> Thus, this makes necessary the use of functional removable appliances as retainer until the end of the growth stage,<sup>3,25,29</sup>

with the goal of keeping the orthopedic correction and lead the tooth eruption during the transition from mixed to permanent dentition.

## CONCLUSION

Skeletal effects produced by Herbst appliance at the stage of mixed dentition in this study were:

- Restriction of maxillary growth.
- Greater anterior position and increase of the mandibular length.
- Positive change in relation to facial convexity and the maxillomandibular relationship.
- No significant change in mandibular and palatal plane.
- Significant increase in anterior and posterior facial height.

## REFERENCES

- Almeida MR, Henriques JFC, Almeida RR, Ursi W, McNamara JA Jr. Short-term treatment effects produced by the Herbst appliance in the mixed dentition. *Angle Orthod*. 2005;75(\$):540-7.
- Baccetti T, Franchi L, McNamara JA Jr. The cervical vertebral maturation (CVM) method for the assessment of optimal treatment timing in dentofacial orthopedics. *Semin Orthod*. 2005;11:119-29.
- Croft R, Buschang P, Meyer R. A Cephalometric and tomographic evaluation of Herbst treatment in the mixed dentition. *Am J Orthod Dentofacial Orthop*. 1999;116(4):435-43.
- Flores-Mir C, Ayeh A, Goswami A, Charkhandeh S. Skeletal and dental changes in class II division 1 malocclusions treated with splint-type herbst appliance. A systematic review. *Angle Orthod*. 2007;77:376-81.
- Franchi L, Baccetti T, McNamara JA Jr. Treatment and post treatment effects of acrylic splint Herbst appliance therapy. *Am J Orthod Dentofacial Orthop*. 1999;115(4):429-38.
- Hägg U, Du X, Rabie ABM. Initial and late treatment effects of headgear-Herbst appliance with mandibular step-by-step advancement. *Am J Orthod Dentofacial Orthop*. 2002;122:477-85.
- Howe RP. The bonded Herbst appliance. *J Clin Orthod*. 1982;16(10):663-7.
- Konik M, Pancherz H, Hansen K. The mechanics of Class II corrections in late Herbst treatment. *Am J Orthod Dentofacial Orthop*. 1997;112(1):87-91.
- Lai M, McNamara JA Jr. A evaluation of two-phase treatment with the Herbst appliance and preadjusted edgewise therapy. *Semin Orthod*. 1998;4(1):46-58.
- Lamparski DG. Skeletal age assessment utilizing cervical vertebrae [Thesis]. Pittsburgh (PA): University of Pittsburg; 1972.
- McNamara JA Jr, Howe R, Dischinger TG. A comparison of the herbst and Fränkel appliances in the treatment of class II malocclusion. *Am J Orthod Dentofacial Orthop*. 1990;98(2):134-44.
- O'Reilly MT, Yanniello GJ. Mandibular growth changes and maturation of cervical vertebrae: a longitudinal cephalometric study. *Angle Orthod*. 1988;58(2):179-84.
- Pancherz H. Treatment of Class II malocclusions by jumping the bite with the Herbst appliance. *Am J Orthod*. 1979;76(4):423-42.
- Pancherz H. The mechanism of Class II correction in Herbst appliance treatment. *Am J Orthod Dentofacial Orthop*. 1982;82(2):104-13.
- Pancherz H, Hägg U. Dentofacial orthopedics in relation to somatic maturation. An analysis of 70 consecutive cases treated with the Herbst appliance. *Am J Orthod*. 1985;88(4):273-87.
- Pancherz H, Hansen K. Occlusal changes during and after Herbst treatment: a cephalometric investigation. *Eur J Orthod*. 1986;8(4):215-28.
- Popovich F, Thompson GW. Craniofacial templates for orthodontic case analysis. In: Clark JW. Clinical dentistry. Philadelphia: Harper & Row; 1983. p. 1-24.
- Rego MVNN. Estudo cefalométrico das alterações esqueléticas, dentárias e tegumentares induzidas pelo aparelho Herbst no tratamento da má oclusão Classe II, 1ª divisão de Angle [dissertação]. Porto Alegre (RS): Pontifícia Universidade Católica; 2003.
- Ruf S, Pancherz H. Herbst/multibracket appliance treatment of Class II division 1 malocclusions in early and late adulthood. A prospective cephalometric study of consecutively treated subjects. *Eur J Orthod*. 2006;28:352-60.
- Ruf S, Pancherz H. The effect of Herbst appliance treatment on the mandibular plane angle: a Cephalometric roentgenographic study. *Am J Orthod Dentofacial Orthop*. 1996;110:225-9.
- Ruf S, Pancherz H. The mechanism of Class II correction during Herbst therapy in relation to the vertical jaw base relationship. A Cephalometric roentgenographic study. *Angle Orthod*. 1997;67(4):271-6.
- Ruf S, Pancherz H. When in the ideal period for Herbst therapy: early or late. *Semin Orthod*. 2003;9(1):47-56.
- Sakima PRT. Efeitos dos erros de projeção sobre as grandezas cefalométricas das análises de Steiner e McNamara [dissertação]. Araraquara (SP): Universidade Estadual de São Paulo; 2001.
- Schiavoni R, Grenga V, Macri V. Treatment of Class II high angle malocclusions with the herbst appliance. A cephalometric investigation. *Am J Orthod Dentofacial Orthop*. 1992;102(5):393-409.
- Silva Filho OG. Aparelho de Herbst - Variação para uso na dentadura mista. *Rev Dental Press Ortod Ortop Facial*. 2000;5(5):58-67.
- Ursi W, McNamara JA Jr, Martins DR. Alteração clínica da face em crescimento: uma comparação cefalométrica entre os aparelhos extrabucal cervical, Fränkel e Herbst, no tratamento das classes II. *Rev Dental Press Ortod Ortop Facial*. 1999;4(5):77-108.
- Valant JR, Sinclair P. Treatment effects of the Herbst appliance. *Am J Orthod Dentofacial Orthop*. 1989;95(2):138-47.
- Wieslander L. Intensive treatment of severe Class II malocclusion with a headgear-Herbst appliance in the early mixed dentition. *Am J Orthod Dentofacial Orthop*. 1984;86(1):1-13.
- Wieslander L. Long-term effects of treatment with the headgear-appliance in the early mixed dentition. *Am J Orthod Dentofacial Orthop*. 1993;104(4):319-29.
- Windmiller EC. The acrylic-splint Herbst appliance: a cephalometric evaluation. *Am J Orthod Dentofacial Orthop*. 1993;104(4):73-84.