Matheus Melo Pithon*

NiTi ESTHETIC ORTHODONTIC WIRES HAVE THE SAME PHYSICAL PROPERTIES OF CONVENTIONAL WIRES

Many options are available on the market of esthetic orthodontic appliances, among which lingual appliances, aligners and ceramic brackets are highlighted. The latter are the most popular due to following the same principle of buccally positioned metallic brackets; however, patients wearing them are frustrated when they find out the orthodontic wire inserted into the slot is a metallic one. With a view to solving such an issue, the industry of orthodontic material developed esthetic orthodontic wires. They are presented in pre-contoured archwire shape and coated with enamel-like color material which aims at disguising the wire. Nevertheless, some doubt is cast on whether this type of archwire is effective. With a view to proving the effectiveness of esthetic orthodontic wires, American researchers conducted a study[1] to compare the physical properties of NiTi conventional and coated wires. They concluded that some coated esthetic archwires had the same physical properties of NiTi conventional ones. Despite such conclusion, further development is necessary, given the lack of esthetic wires that can be bended while preserving esthetics.

DENTAL PULP OF REIMPLANTED TEETH WITH INCOMPLETE RHIZOGENESIS REGENERATES

Dental avulsion resulting from trauma certainly is the most traumatic event a tooth might go through. Whenever it occurs, all efforts must be taken so as to reimplant the tooth as soon as possible. Most of times, reimplantation must be followed by endodontic treatment in order to avoid infection of the periodontium. However, some authors highlight there is no need in going through this stage when reimplantation involves a case of teeth with incomplete rhizogenesis. In this context, the following question arises: Up to which point does dental pulp of teeth with incomplete rhizogenesis regenerate? With a view to answering this question, Norwegian researchers conducted a clinical trial[2] in which 70 premolars were extracted and immediately reimplanted. The teeth were radiographically assessed within 24 weeks and histologically assessed afterwards. The authors concluded that immature dental pulp can regenerate itself as well as produce tertiary dentin after reimplantation. The authors highlight that tertiary dentin and root resorptions, which are histologically seen, cannot be identified by radiographic examination.

LOCAL APPLICATION OF ZOLEDRONATE INCREASES ORTHODONTIC MINI-IMPLANT STABILITY

Orthodontic mini-implants have become worldwide popular since they were first developed. This is not only due to their effectiveness in acting as anchorage agents, but also for having a small size, low cost and being easy to handle by the orthodontist. Despite these far-reaching and well-known positive points, mini-implants still have some percentage of stability loss after placement. Stability loss provides the patient with discomfort and delays treatment time. Minimizing or

Submitted: August 05, 2014 - **Revised and accepted**: August 19, 2014

*Professor, Department of Orthodontics, State University of Southwest Bahia (UESB).

How to cite this article: Pithon MM. Orthodontics highlights. Dental Press J Orthod. 2014 Sept-Oct;19(5):16-8.

Contact address: Matheus Melo Pithon
Av. Otávio Santos, 395 – Sala 705 – Vitória da Conquista/BA – Brazil
CEP: 45020-750 E-mail: matheuspithon@gmail.com

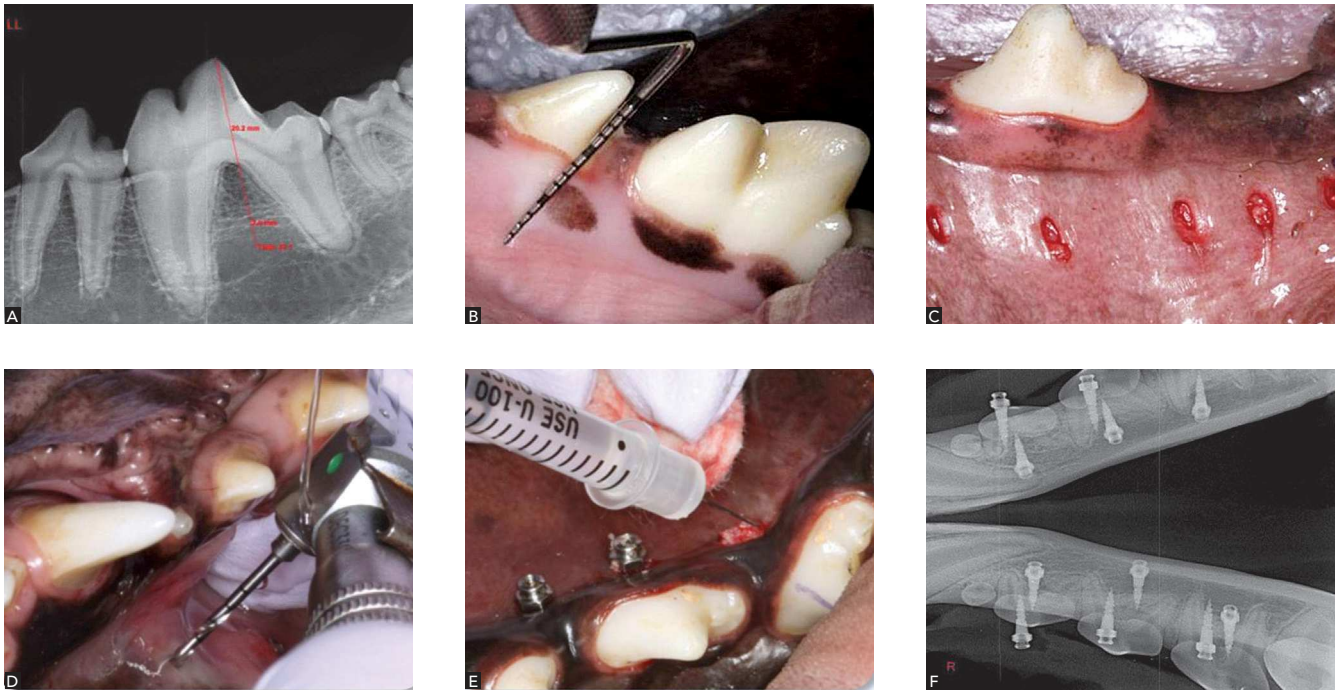

Figure 1 - **A**) Initial radiographic evaluation; **B**) Clinical evaluation at mini-implant placement site; **C**) Removal of gingival tissue at mini-implant placement site; **D**) Perforation of bone tissue with drill under refrigeration with saline solution; **E**) Zoledronate injection; **F**) Radiographic examination after mini-implant placement. Source: Cuairan et al,[3] 2014.

eliminating mini-implants stability loss would strongly favor clinical practice. With a view to solving such an issue, Costa-Rican, American and Brazilian researchers conducted an experimental study[3] in which mini-implants were placed in dogs, followed by local application of zoledronate to investigate its effectiveness in increasing mini-implant stability (Fig 1).The authors yielded promising results, as mini-implants receiving the medication had increased stability in comparison to control. Despite finding promising effects with regard to mini-implant stability, the researchers highlight the medication should not be clinically used before further clinical research is carried out to prove or disprove how safe zoledronate is.

MINI-HYRAX EXPANDER: THE BEST OPTION FOR ANTERIOR EXPANSION IN CLEFT PATIENTS

Cleft lip and palate is the most prevalent craniofacial anomaly affecting an expressive number of people around the world. Treatment involves a multidisciplinary team in which orthodontists play a starring role. Whenever orthodontic correction is considered for cleft lip/palate patients, maxillary expansion is always present, given that maxillary growth is compromised in these cases. Furthermore, cleft lip/palate patients have a peculiarity: greater anterior maxillary constriction in comparison to posterior. In these cases, the use of an expander is rendered necessary so as to potentiate anterior opening. In this context, the following question arises: What is the best expander appliance for such clinical cases? With a view to answering this question, Brazilian researchers conducted a clinical trial[4] to assess dental and skeletal effects of three different expanders: Hyrax, fan-type and inverted mini-hyrax (Fig 2).Their results revealed that hyrax expander is best for anterior and posterior opening, whereas inverted mini-hyrax should be the expander of choice for anterior opening without significant posterior changes.

Figure 2 - Rapid maxillary expansion appliances assessed: **A**) Hyrax; **B**) Fan-type; **C**) Inverted mini-hyrax. Source: Figueiredo et al.[4]

INCORPORATION OF ANTIBACTERIAL MONOMER INTO ORTHODONTIC CEMENT GRANTS THE LATTER WITH GOOD ANTIBACTERIAL POWER

Direct bonding of orthodontic accessories to enamel surface has certainly been one of the biggest steps Orthodontics has ever taken. This procedure enhanced orthodontic appliance mounting which once used orthodontic rings, thereby making Orthodontics popular. Despite such advantages, orthodontic accessories bonded to enamel surface hinder dental hygiene and might lead to tooth caries. There has been a lot of discussion about oral hygiene products with antimicrobial agents; however, developing a product that does not require patient's compliance would make the entire process more predictable to the orthodontist. In this context, American researchers[5] incorporated an antibacterial monomer to orthodontic cement and assessed not only the antibacterial activity of this new product, but also its physical properties after incorporation. The authors concluded that the new cement had strong antimicrobial activity expressed by significant reduction in metabolic activity and production of lactic acid as well as colony forming units, without damaging the material physical properties.

REFERENCES

1. Washington B, Evans CA, Viana G, Bedran-Russo A, Megremis S. Contemporary esthetic nickel-titanium wires: do they deliver the same forces? Angle Orthod. 2014 Jun 5. [Epub ahead of print].
2. Fiane JE, Breivik M, Vandevska-Radunovic V. A histomorphometric and radiographic study of replanted human premolars. Eur J Orthod. 2013 Dec 19. [Epub ahead of print].
3. Cuairan C, Campbell PM, Kontogiorgos E, Taylor RW, Melo AC, Buschang PH. Local application of zoledronate enhances miniscrew implant stability in dogs. Am J Orthod Dentofacial Orthop. 2014;145(6):737-49.
4. Figueiredo DS, Bartolomeo FU, Romualdo CR, Palomo JM, Horta MC, Andrade I Jr, et al. Dentoskeletal effects of 3 maxillary expanders in patients with clefts: a cone-beam computed tomography study. Am J Orthod Dentofacial Orthop. 2014;146(1):73-81.
5. Melo MA, Wu J, Weir MD, Xu HH. Novel antibacterial orthodontic cement containing quaternary ammonium monomer dimethylaminododecyl methacrylate. J Dent. 2014;42(9):1193-1201.