



An interview with

Benedict Wilmes

- » Oral Surgery training, Department of Maxillofacial Surgery, University of Muenster, Germany.
- » Post-graduated in Orthodontics and Dentofacial Orthopedics, University of Duesseldorf, Germany.
- » Professor, Department of Orthodontics, University of Duesseldorf, Germany.
- » Visiting Associate Professor, University of Alabama at Birmingham, USA.
- » First prize awarded of the German Orthodontic Society in 2007 and the First Prize of the European Orthodontic Society in 2009.
- » Reviewer of numerous journals and has held more than 250 lectures and courses in 50 different countries all over the world.

DOI: <http://dx.doi.org/10.1590/2177-6709.21.6.026-033.int>

It is a great pleasure to bring to the readers of Dental Press Journal of Orthodontics some of the clinical and scientific knowledge from this great German orthodontist: Prof. Dr. Benedict Wilmes. Dr. Wilmes was raised in Soest, a small village with 50,000 inhabitants in the middle of Germany. He attended Dental School in Muenster, a nice university city near Netherlands. He first received a post-graduate degree in Oral Surgery at the Department of Maxillofacial Surgery at University of Muenster, and subsequently he did a post-graduation in Orthodontics and Dentofacial Orthopedics at the University of Duesseldorf. Dr. Wilmes has published more than 100 articles and textbook chapters. His primary interest is in the area of non-compliant and invisible orthodontic treatment strategies (TADs, lingual Orthodontics and aligners). His favorite hobbies are sports and philosophy. He even was a professional basketball player for the 1st and 2nd divisions in Germany. Lastly, I would like to disclose my gratitude to the DPJO for the opportunity of this interview, to the professors who contributed with the questions, and especially to Dr. Wilmes, who shared his experience and let us know a little more about his brilliant work. *Vielen Dank!*

Guilherme Thiesen – interview coordinator

How to cite this section: Wilmes B. An interview with Benedict Wilmes. Dental Press J Orthod. 2016 Nov-Dec;21(6):26-33.

DOI: <http://dx.doi.org/10.1590/2177-6709.21.6.026-033.int>

Submitted: September 01, 2016 - **Revised and accepted:** September 13, 2016

What are the advantages of the mechanics for upper-molar intrusion you have developed (Mousetrap Mechanics) compared with other conventional mechanics for molar intrusion? Is there a limitation for intrusion? If simultaneous intrusion of the first and second upper molars is needed, what variations in appliance design and/or force system do you use?

Marcus Vinicius Neiva Nunes do Rego

The mostly used insertion site of miniscrews is in the alveolar process. However, there are a number of disadvantages related to the insertion into the interradicular area of the upper molars:

» There is often insufficient space on the buccal aspect to insert a miniscrew safely between tooth roots.¹⁻³

» The periodontal structures may be damaged if the miniscrew contacts the surface of a tooth root and the risk of failure of the miniscrew will be higher.^{4,5}

» The reduced interraderic area on the buccal alveolar process of the upper molars limits the placement of miniscrews to those with a small diameter.⁶ However, small diameters are associated with a higher risk of fracture⁷ and failure.⁸⁻¹⁰

» Intrusive movement may be stopped and the root surface may be damaged when a molar is moved directly against a mini-implant during intrusion.^{11,12}

» There is risk of penetration of the maxillary sinus when a miniscrew is inserted into the posterior area of the upper alveolar process.¹³

To minimise insertion risks, a prudent strategy is the placement of miniscrews safely away from the roots and the teeth to be moved. The anterior palate provides for a suitable alternative insertion site where miniscrews with larger dimensions and higher stability^{14,15} may be placed in a region with a high bone quality, thin overlying soft tissue and negligible risk of causing interference with nearby teeth.¹⁶

To conclude: every strategy has pros and cons. Advantages of the Mousetrap are a safe insertion site for the Temporary Anchorage Devices (TADs) and a constant and predictable level and direction of forces (Figs 1 and 2). Disadvantage might be the bigger dimension of the appliance.

I don't know if there is a limit of intrusion, we have intruded some molars around 4-5 mm. However, the risk of root resorption and the soft tissue excess after a distinctive intrusion have to be considered.

If more than one tooth in a quadrant is to be intruded, teeth can be coupled before intrusion. As an alternative, a two stage intrusion can be performed: 1) Intrusion of one molar; 2) Levelling and intrusion of adjacent teeth. Both strategies are possible.

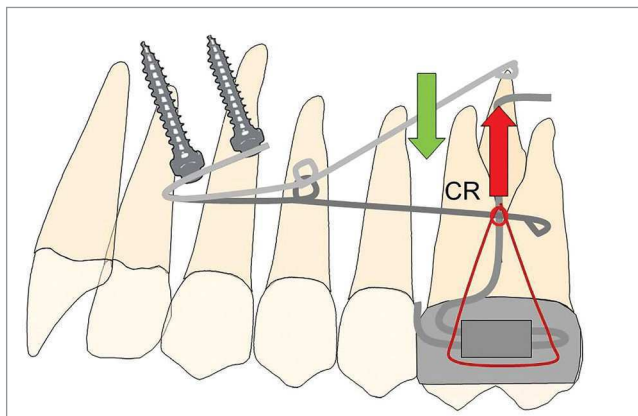


Figure 1 - "Mousetrap" mechanics for upper molar intrusion using TADs in the anterior palate. If the molars should be just intruded, the line of force must pass through the estimated center of resistance (CR).

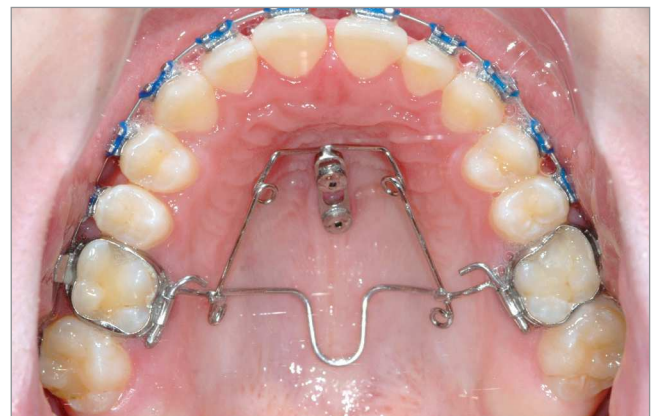

Figure 2 - "Mousetrap" mechanics for upper molar intrusion using TADs in the anterior palate in an open bite case.

Since your TADs anchored distalizer for Class II correction (named Beneslider) applies forces on the palatal surfaces of the molars, and a common characteristic of Class II malocclusions is a mesial rotation of the molars, how do you usually control this aspect? **Guilherme Thiesen**

From my point of view, there are three key points to avoid molar tipping and rotation during distalization: 1) a safe source of anchorage; 2) a rigid guiding wire (1.1 mm in the Beneslider) and 3) a rigid coupling with the molars to be distalized. However, we see sometimes a little bit of rotation due to the little play using the molar sheath and the conventional Benetube (Fig 3). A more rigid coupling from the Beneslider to the molars is obtained in the bonded Benetube (acc. to Dr. Banach, Fig 4).

You usually demonstrate in your lectures some different designs of molar mesialization appliances

(T-wire, Mesialsliders, etc.). What are the clinical differences between them? I mean, when do you indicate one or another? **Ki Beom Kim**

If the central incisors are in the correct position (midline, torque and angulation is correct), a T-wire¹⁷ (Fig 5) can be bonded to the lingual surfaces of the central incisors to apply an indirect anchorage with the goal of avoiding lingual tipping of the central incisors during space closure.¹⁷⁻¹⁹ As an alternative to the T-wire (indirect anchorage), the Mesialslider^{17,18} (Fig 6) as a direct anchorage device can be used. The use of the T-wire leads to a very easy mechanics, but the Mesialslider has some advantages: 1) Since the incisors are not fixed, a midline deviation and incorrect dental torque can be adjusted at the same time. 2) Brackets are not needed during the use of the Mesialslider (and Beneslider), what makes this phase of the treatment much more comfortable for the patient.

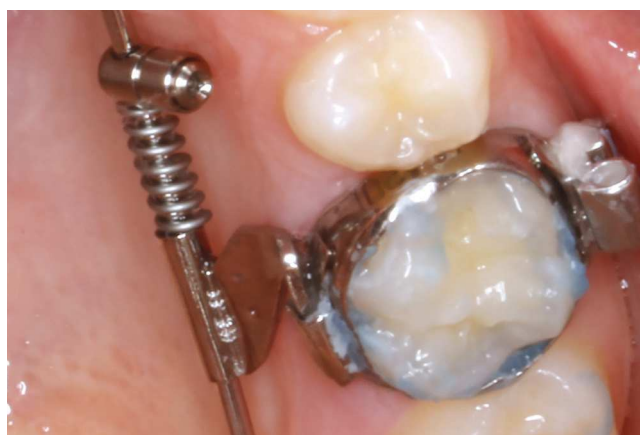
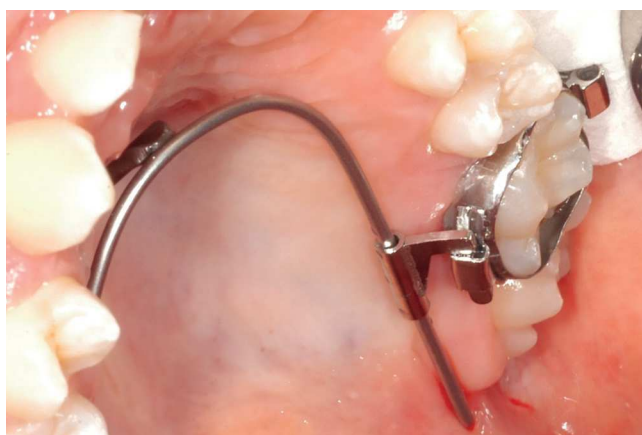
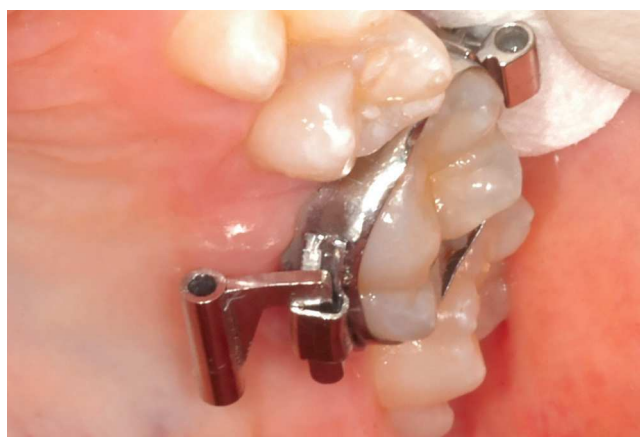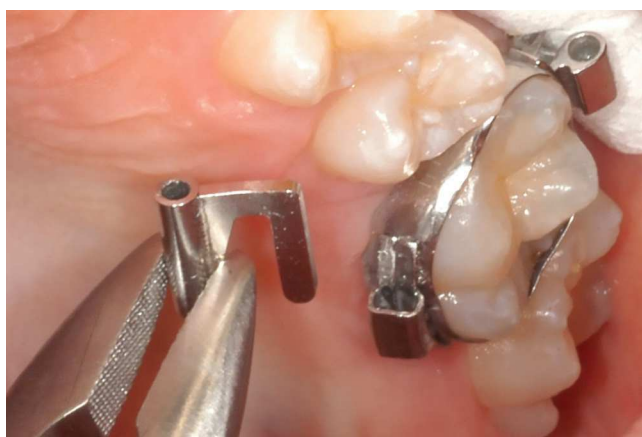Figure 3 - Chairside adaptation of a Beneslider appliance. Due to prefabricated parts, impression and laboratory procedure are not needed.

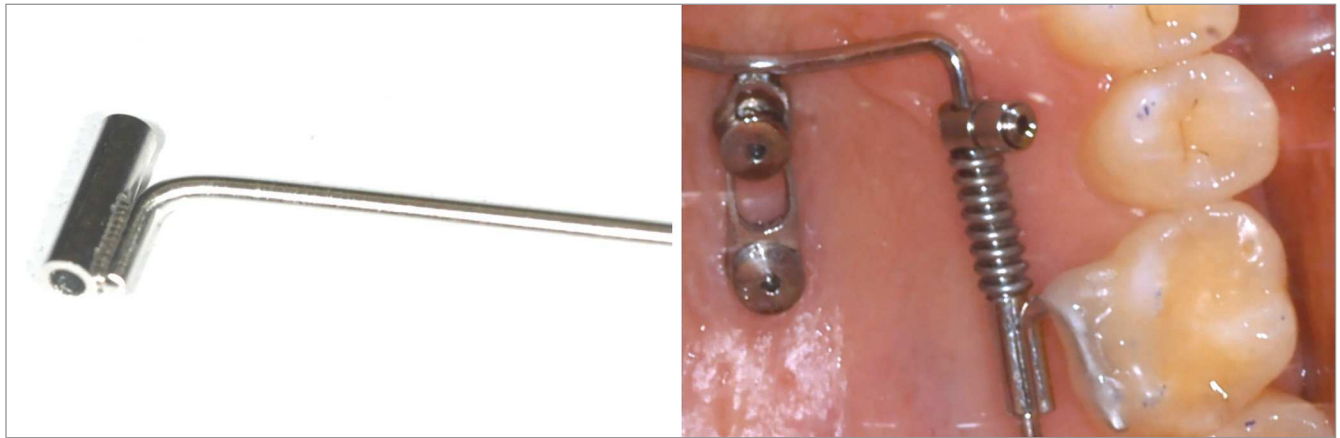

Figure 4 - If bands are not used, a Benetube according to Dr. Banach may be used.

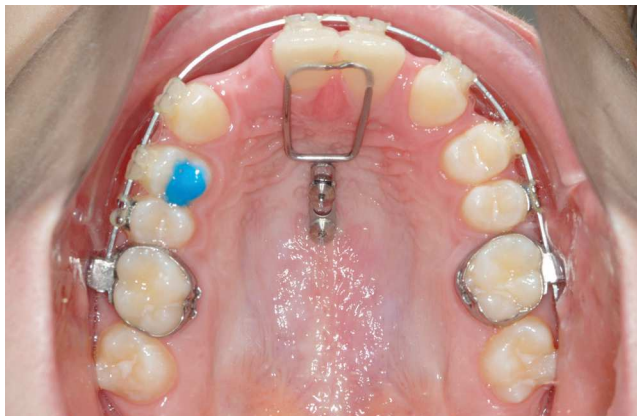

Figure 5 - T-wire for indirect anchorage of the anterior dentition. Space closure to the mesial was conducted.

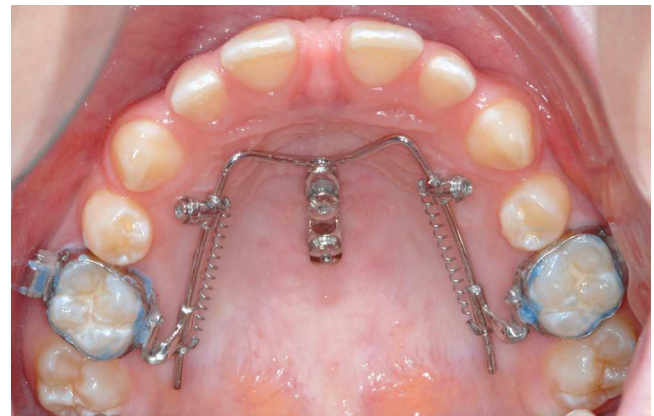


Figure 6 - Mesialslider for mesialization of the upper molars (direct anchorage).

On the AAO meeting held in Orlando in 2016, you demonstrated a lot of cases in which you combined the Beneslider system with Invisalign treatment after that. Can you describe it better how to manage that? How can we use these appliances for anchorage after achieving the desired distalization of the molars? Guilherme Thiesen

In the US and in Europe, the use of aligners be-

came very popular over the last decade. At the University of Düsseldorf, we are following this two-step strategy: 1) Moving the upper molars (and premolars) with (Bene-) or Mesialsliders and 2) Taking an impression and finishing the case with aligners.²⁰ I think this is a great option for esthetic and non-compliant Orthodontics. In phase 2, we leave the Beneslider in place for anchorage purposes (Fig 7).

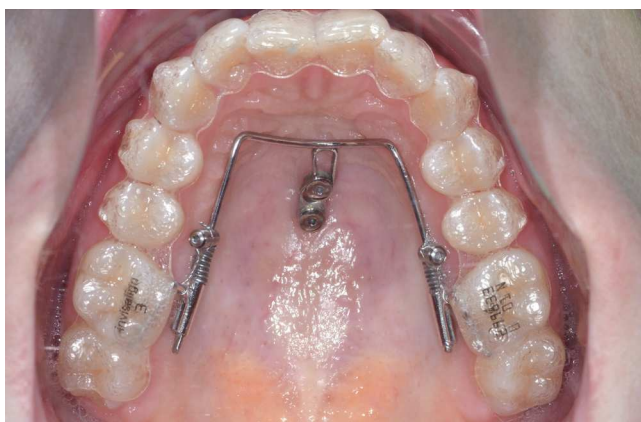


Figure 7 - Combination of the Beneslider and aligner: After distalization with the Beneslider, aligners are used for finishing of the case. The Beneslider might stay in place passively for molar anchorage.

Nowadays, what are the biggest challenges you face when treating a malocclusion with aligners? Which are your criteria for Invisalign indication? Do you overcorrect some movements?

Guilherme Thiesen

I think that bodily sagittal movements and vertical movements are very difficult with aligners. Thus, we can broaden the treatment opportunities by adding TAD borne sliders for bodily movements or the "Mousetrap" for molar intrusion in the upper arch. If there is a difficult treatment task in the lower arch, I am still choosing fixed appliances.

Most of the miniscrews for your mechanics are placed in the anterior palatal region. Some of them are inserted right at the midpalatal suture. Do you have any concerns about placing miniscrews into the suture especially in adolescent patients?

Ki Beom Kim

The clinician has to differentiate between a median and paramedian pattern of location of miniscrews. There is no difference in regards to the continued retention and stability of miniscrews between median and paramedian insertion, even among children and adolescents.^{21,22} The possibility of growth impairment due to the location of implants within the midpalatal suture was investigated by Asscherickx et al,²³ who inserted two dental implants (Straumann palatal implant) in the suture of Beagle dogs and discussed a transversal growth inhibition of the maxilla. However, in this study, only one control animal was available and only one parameter was found to be different.²⁴ Secondly, the transferability of findings from this study to miniscrews is

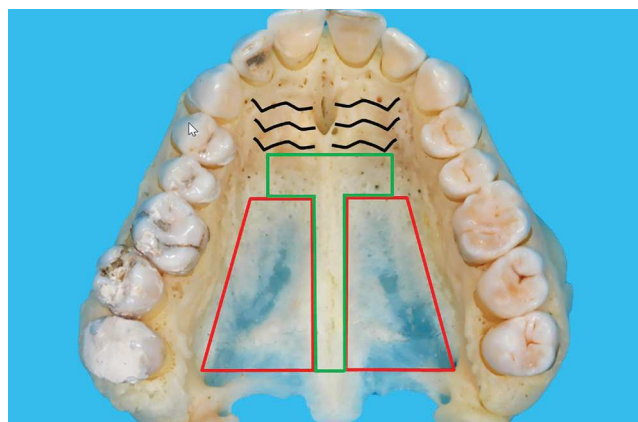


Figure 8 - The T-Zone (green) is indicating the recommended insertion site for palatal TADs. In the posterior-lateral area (red) the available bone is very thin.

questionable, due to the greater diameter and the surface roughness of the dental implants. Clinical observations at our Institution have not revealed a tendency of impaired transversal growth of the maxilla. As such, the clinically relevant impairment of maxillary growth due to a median inserted miniscrew seems unlikely. Contrastingly, a median insertion is considered to be advantageous due to the profound reduction in risk of injury to the roots of the upper incisor teeth, during the insertion procedure.

Therefore, what are the most important details related to TADs insertion on the anterior palate?

Jorge Faber

Very easy: Stay in the T-Zone posterior from the rugae (green area, Fig 8). Avoid the posterior lateral area, due to lack of bone (red area, Fig 8).

A study you published in 2015²⁵, in which you compared the classic maxillary protraction protocol with another protocol using the Hybrid Hyrax appliance (anchored on TADs placed in the palate), showed less forward movement of the maxilla and improvement of maxillomandibular relationship, if we compare your results with the findings reported by Hugo De Clerk's miniplate approach. What is the reason for this difference?

Marcus Vinicius Neiva Nunes do Rego

Mostly, it doesn't make sense to compare these values from different studies. Maybe there are many reasons for bias due to the different choice of patients in the different institutions etc. We need RCTs in the future to be able to compare these treatment approaches.

Clinically, we tried to be as less invasive as possible. That was the reason to use the Hybrid Hyrax with just two miniscrews instead of two miniplates for pure skeletal protraction of the maxilla without dental side effects (extrusion and mesial migration of the molars, Figs 9 and 10).

The Mentoplate is an innovative method for Class III treatment in growing patients. What are the main advantages of this technique in comparison to Hugo De Clerk's miniplate approach?

Jorge Faber

First of all, I really admire Hugo De Clerk's work. From my point of view, he had many outstanding ideas and he is for sure one of my role-models. However, I think there are several advantages of the Men-

toplate and Hybrid Hyrax (Figs 11-13) compared to the Bollard miniplates.

First of all, the Bollard miniplates cannot be inserted before the lower canines are erupted (around 12 or 13 years old). As a consequence, the patient is, according to many studies (eg. from Lorenzo Franchi²⁶), beyond the best age for an orthopedic Class III treatment. The Mentoplate can be inserted very early, our favorite age is around 8-9 years old.

Secondly, we are missing the "RPE-effect" and the "Alt-RAMEC-effect" with stimulation of midface sutures for bigger maxillary protraction. We know that this stimulation results in more protraction of the maxilla.²⁶

Thirdly, the palatal TADs are less invasive and more stable than upper miniplates since the failure rate of the palatal TADs is almost zero.²⁷

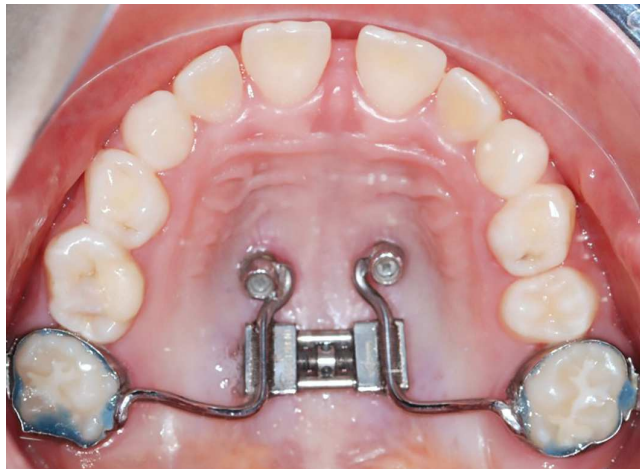

Figure 9 - Hybrid Hyrax with two TADs in the anterior palate for rapid maxillary expansion and early Class III treatment.

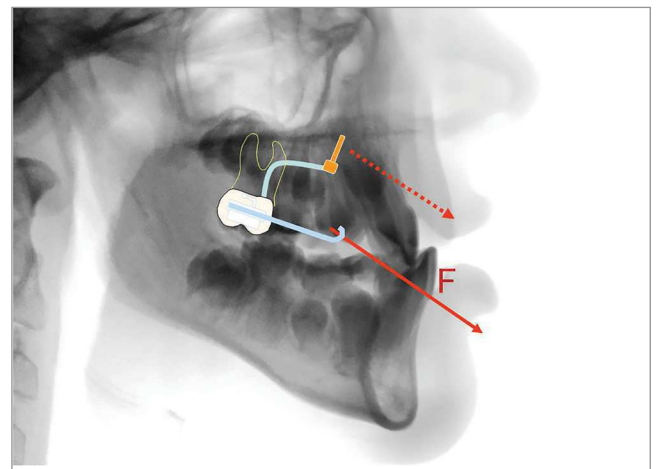


Figure 10 - Principle of the Hybrid Hyrax facemask combination: The force is transferred to bony structures, minimizing dental side effects.

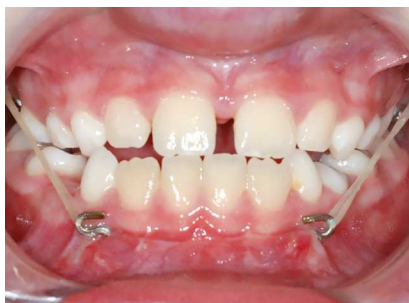

Figure 11 - TAD borne early Class III treatment: Intraoral elastics are attached to the Mentoplate and to the bands of the Hybrid Hyrax.

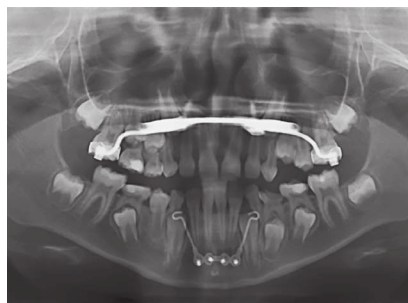


Figure 12 - The Mentoplate is inserted in the mental area, with an outstanding bone quality. Insertion is possible at the best age for orthopedic treatment (before puberty, 8-10 years of age).

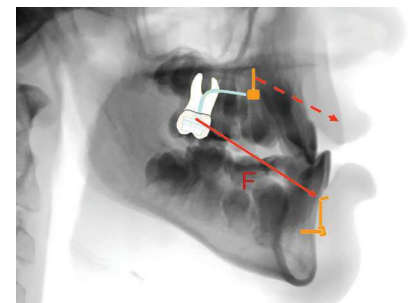


Figure 13 - Principle of the Hybrid Hyrax-Mentoplate combination: The force is transferred to bony structures minimizing dental side effects. Hence, an extraoral device could be avoided.

In the treatment of Class III malocclusion with skeletal anchorage, do you believe that a rapid maxillary expansion prior to traction is needed even when there is no transverse discrepancy?

Marcus Vinicius Neiva Nunes do Rego

RME is not needed, but it improves the skeletal effects of the Class III therapy, especially using Alt-RAMEC (see previous question).

In some parts of the world, such as in Brazil, parents tend to refuse procedures under general anesthesia. At the same time, in growing Class III patients, miniplates are very often placed under general anesthesia. How well do European parents accept this anesthetic protocol, and what is your point of view about the surgical risks and benefits of miniplate treatment in growing Class III patients? **Jorge Faber**

I think, there is not a big difference between parents around the world. All parents want to do the best for their children. Of course, we have to talk about risks and benefits for all our treatments and let the parents and patients make the final decision. The risks of miniplates are very low if they are placed away from roots and nerves. This may be another advantage of the Mentoplate, it is inserted in a very safe area, away from the roots.

There are many case reports using the miniscrews in the buccal shelf or retromolar region to distalize the entire mandibular dentition to correct Class III malocclusions. What is your opinion about this type of mechanics? Do you have any suggestions for Class III malocclusion with true prognathic mandible besides using miniscrews or miniplates in the mandibular anterior area and infrazygomatic area? **Ki Beom Kim**

I don't think that there are so many indications for lower distalization, especially in Europe and the US. There is always the risk that there is no space distally, and therefore the distalization of the lower dentition will be a difficult task.

Guilherme Thiesen

- » Post-doctoral Fellow in Orthodontics, Center for Advanced Dental Education, Saint Louis University, Saint Louis, MO, USA.
- » DDS, MSc and PhD in Orthodontics and Dentofacial Orthopedics (UFSC, PUCRS and ULBRA).
- » Diplomate, Brazilian Board of Orthodontics and Dentofacial Orthopedics.
- » Professor of Orthodontics, UNISUL, Santa Catarina, Brazil.

Marcus Vinicius Neiva Nunes do Rego

- » DDS, MSc and PhD in Orthodontics and Dentofacial Orthopedics (UFPI, PUCRS and SLMandic).
- » Professor of Orthodontics, UNINOVAFAPI, Piauí, Brazil.
- » Professor of the Postgraduate Orthodontic Program, UFPI, Piauí, Brazil.
- » President of the Brazilian Association of Orthodontics, section Piauí (ABOR/PI).

Jorge Faber

- » Editor-in-chief, Journal of the World Federation of Orthodontists.
- » Adjunct Professor of Orthodontics, University of Brasilia, Brazil.
- » Former editor-in-chief, Dental Press Journal of Orthodontics.
- » Board Certified, Brazilian Board of Orthodontics and Dentofacial Orthopedics.
- » WFO fellow.
- » Member of the *Associação Brasileira de Ortodontia* (ABOR).

Ki Beom Kim

- » Associate Professor, Department of Orthodontics, Center for Advanced Dental Education, Saint Louis University, Saint Louis, MO, USA.
- » DDS, MSD, PhD (Dankook University, South Korea and Vanderbilt University, Nashville, TN, USA).
- » Diplomate, American Board of Orthodontics.
- » Diplomate, American Board of Orofacial Pain.

REFERENCES

- Ludwig B, Glasl B, Kinzinger GS, Lietz T, Lisson JA. Anatomical guidelines for miniscrew insertion: Vestibular interradicular sites. *J Clin Orthod*. 2011 Mar;45(3):165-73.
- Poggio PM, Incorvati C, Velo S, Carano A. "Safe zones": a guide for miniscrew positioning in the maxillary and mandibular arch. *Angle Orthod*. 2006 Mar;76(2):191-7.
- Kim SH, Yoon HG, Choi YS, Hwang EH, Kook YA, Nelson G. Evaluation of interdental space of the maxillary posterior area for orthodontic mini-implants with cone-beam computed tomography. *Am J Orthod Dentofacial Orthop*. 2009 May;135(5):635-41.
- Miyawaki S, Koyama I, Inoue M, Mishima K, Sugahara T, Takano-Yamamoto T. Factors associated with the stability of titanium screws placed in the posterior region for orthodontic anchorage. *Am J Orthod Dentofacial Orthop*. 2003 Oct;124(4):373-8.
- Chen YH, Chang HH, Chen YJ, Lee D, Chiang HH, Yao CC. Root contact during insertion of miniscrews for orthodontic anchorage increases the failure rate: An animal study. *Clin Oral Implants Res*. 2008 Jan;19(1):99-106.
- Pan F, Kau CH, Zhou H, Souccar N. The anatomical evaluation of the dental arches using cone beam computed tomography - an investigation of the availability of bone for placement of mini-screws. *Head Face Med*. 2013 Apr 20;9:13.
- Wilmes B, Panayotidis A, Drescher D. Fracture resistance of orthodontic mini-implants: a biomechanical in vitro study. *Eur J Orthod*. 2011 Aug;33(4):396-401.
- Fritz U, Ehmer A, Diedrich P. Clinical suitability of titanium microscrews for orthodontic anchorage-preliminary experiences. *J Orofac Orthop*. 2004 Sept;65(5):410-8.
- Wiechmann D, Meyer U, Büchter A. Success rate of mini- and micro-implants used for orthodontic anchorage: a prospective clinical study. *Clin Oral Implants Res*. 2007 Apr;18(2):263-7.
- Tsaousidis G, Bauss O. Influence of insertion site on the failure rates of orthodontic miniscrews. *J Orofac Orthop*. 2008 Sept;69(5):349-56.
- Kadioglu O, Büyükyilmaz T, Zachrisson BU, Maino BG. Contact damage to root surfaces of premolars touching miniscrews during orthodontic treatment. *Am J Orthod Dentofacial Orthop*. 2008 Sept;134(3):353-60.
- Maino BG, Weiland F, Attanasi A, Zachrisson BU, Büyükyilmaz T. Root damage and repair after contact with miniscrews. *J Clin Orthod*. 2007 Dec;41(12):762-6; quiz 750.
- Gracco A, Tracey S, Baciliero U. Miniscrew insertion and the maxillary sinus: an endoscopic evaluation. *J Clin Orthod*. 2010 July;44(7):439-43.
- Wilmes B, Ottenstreuer S, Su YY, Drescher D. Impact of implant design on primary stability of orthodontic mini-implants. *J Orofac Orthop*. 2008 Jan;69(1):42-50.
- Wilmes B, Drescher D. Impact of bone quality, implant type, and implantation site preparation on insertion torques of mini-implants used for orthodontic anchorage. *Int J Oral Maxillofac Surg*. 2011 July;40(7):697-703.
- Ludwig B, Glasl B, Bowman SJ, Wilmes B, Kinzinger GS, Lisson JA. Anatomical guidelines for miniscrew insertion: palatal sites. *J Clin Orthod*. 2011 Aug;45(8):433-41; quiz 467.
- Wilmes B, Drescher D. A miniscrew system with interchangeable abutments. *J Clin Orthod*. 2008 Oct;42(10):574-80; quiz 595.
- Wilmes B, Drescher D, Nienkemper M. A miniplate system for improved stability of skeletal anchorage. *J Clin Orthod*. 2009 Aug;43(8):494-501.
- Baumgaertel S. Maxillary molar movement with a new treatment auxiliary and palatal miniscrew anchorage. *J Clin Orthod*. 2008 Oct;42(10):587-9; quiz 596.
- Wilmes B, Nienkemper M, Ludwig B, Kau CH, Pauls A, Drescher D. Esthetic Class II treatment with the Benesider and aligners. *J Clin Orthod*. 2012 July;46(7):390-8; quiz 437.
- Nienkemper M, Pauls A, Ludwig B, Drescher D. Stability of paramedian inserted palatal mini-implants at the initial healing period: a controlled clinical study. *Clin Oral Implants Res*. 2015 Aug;26(8):870-5.
- Nienkemper M, Wilmes B, Pauls A, Drescher D. Mini-implant stability at the initial healing period: a clinical pilot study. *Angle Orthod*. 2014 Jan;84(1):127-33.
- Asscherickx K, Hanssens JL, Wehrbein H, Sabzevar MM. Orthodontic anchorage implants inserted in the median palatal suture and normal transverse maxillary growth in growing dogs: a biometric and radiographic study. *Angle Orthod*. 2005 Sept;75(5):826-31.
- Borsos G, Rudzki-Janson I, Stockmann P, Schlegel KA, Végh A. Immediate loading of palatal implants in still-growing patients: a prospective, comparative, clinical pilot study. *J Orofac Orthop*. 2008 July;69(4):297-308.
- Ngan P, Wilmes B, Drescher D, Martin C, Weaver B, Gunel E. Comparison of two maxillary protraction protocols: tooth-borne versus bone-anchored protraction facemask treatment. *Prog Orthod*. 2015 Aug;16(26).
- Masucci C, Franchi L, Giuntini V, Defraia E. Short-term effects of a modified Alt-RAMEC protocol for early treatment of Class III malocclusion: a controlled study. *Orthod Craniofac Res*. 2014 Nov;17(4):259-69.
- Karagiolidou A, Ludwig B, Pazera P, Gkantidis N, Pandis N, Katsaros C. Survival of palatal miniscrews used for orthodontic appliance anchorage: a retrospective cohort study. *Am J Orthod Dentofacial Orthop*. 2013 June;143(6):767-72.