



# Do premolar extractions necessarily result in a flat face? No, when properly indicated

Susiane Allgayer<sup>1</sup>, Maurício Barbieri Mezomo<sup>2</sup>

DOI: <https://doi.org/10.1590/2177-6709.23.5.082-092.bbo>

The esthetic benefits are among the main goals of orthodontic treatment; therefore, tooth extractions have been avoided as a protocol for orthodontic treatment because they may impair the facial profile. The present article discusses aspects as the magnitude and response of soft tissue profile due to changes in incisor positioning, and the effect of different sequences of premolar extraction. One case report illustrates the subject, with favorable and stable esthetic and occlusal outcomes five years after orthodontic treatment with extraction of second premolars.

**Keywords:** Tooth extraction. Premolars. Orthodontics, corrective. Esthetics.

## INTRODUCTION

In recent years, there has been a noticeable increase in awareness and interest in facial esthetics.<sup>1,2</sup> The esthetic benefits are among the main goals of orthodontic treatment,<sup>3</sup> and clinicians are often asked about possible changes in the profile caused by the treatment.<sup>4</sup> The fact that dental extractions may cause a flat face<sup>4-7</sup> due to excessive incisor retraction has discouraged the orthodontists to adopt this treatment protocol. However, extractions can benefit the profile when properly indicated.<sup>8-13</sup>

Treating patients without extraction simply not to remove teeth or to simplify the treatment is not justified, because it may impair the result and stability of orthodontic treatment. The ideal approach is to apply the correct extraction protocol for each type of malocclusion.<sup>6</sup> In other words, although non-extraction treatment has become popular, many orthodontic patients have some shortage of space or crowding requiring extractions for a favorable treatment outcome.<sup>10,14</sup>

There is general agreement that orthodontic treatment can influence the facial profile, but there is still disagreement

» The author reports no commercial, proprietary or financial interest in the products or companies described in this article.

**How to cite:** Allgayer S, Mezomo MB. Do premolar extractions necessarily result in a flat face? No, when properly indicated. *Dental Press J Orthod*. 2018 Sept-Oct;23(5):82-92. DOI: <https://doi.org/10.1590/2177-6709.23.5.082-092.bbo>

» Patients displayed in this article previously approved the use of their facial and intraoral photographs.

**Submitted:** June 01, 2018 - **Revised and accepted:** August 28, 2018

**Contact address:** Susiane Allgayer  
E-mail: [susianeallgayer@gmail.com](mailto:susianeallgayer@gmail.com)

<sup>1</sup>Professor of Orthodontics at Associação Brasileira de Odontologia – Seção Rio Grande do Sul (Porto Alegre/RS, Brazil).

<sup>2</sup>Professor of Orthodontics at Centro Universitário Franciscano, Faculdade de Odontologia, (Santa Maria/RS, Brazil).

on the magnitude of soft tissue response as a consequence of changes in tooth position and alveolar process. Moreover, there are contradictory opinions about the facial profile changes when different sequences of premolar extractions are analyzed.<sup>8,11,15-21</sup> Some investigators<sup>22-24</sup> suggest more studies to define the effects of the different premolar extraction sequences, as well as to quantify the cumulative effect of aging after this treatment approach on the facial profile.<sup>10</sup>

Therefore, this paper discusses aspects as the magnitude and response of the soft tissue profile as a consequence of changes in incisor positioning, and the effect of different sequences of premolar extraction. One case report illustrates the subject, with favorable and stable esthetic and occlusal outcomes 5 years after orthodontic treatment with extraction of second premolars.

## CASE REPORT

A female patient, aged 27 years and 4 months, had the chief complaint about the “esthetic appearance of her teeth”. She reported to be ashamed of smiling because of the high and rotated maxillary canines. The facial photographs showed proportional facial thirds and straight facial profile with a concave lower facial third. A deficient and asymmetric smile was evident due to the malposition of the maxillary canines. The intraoral photographs evidenced complete Class II molar and canine relationships, 4-mm overjet, 3-mm overbite, and negative tooth-size discrepancy of 5 mm in the maxillary arch and 8.5 mm in the mandibular arch, besides 2-mm deviation of the maxillary midline to the right side. The patient also exhibited crossbite

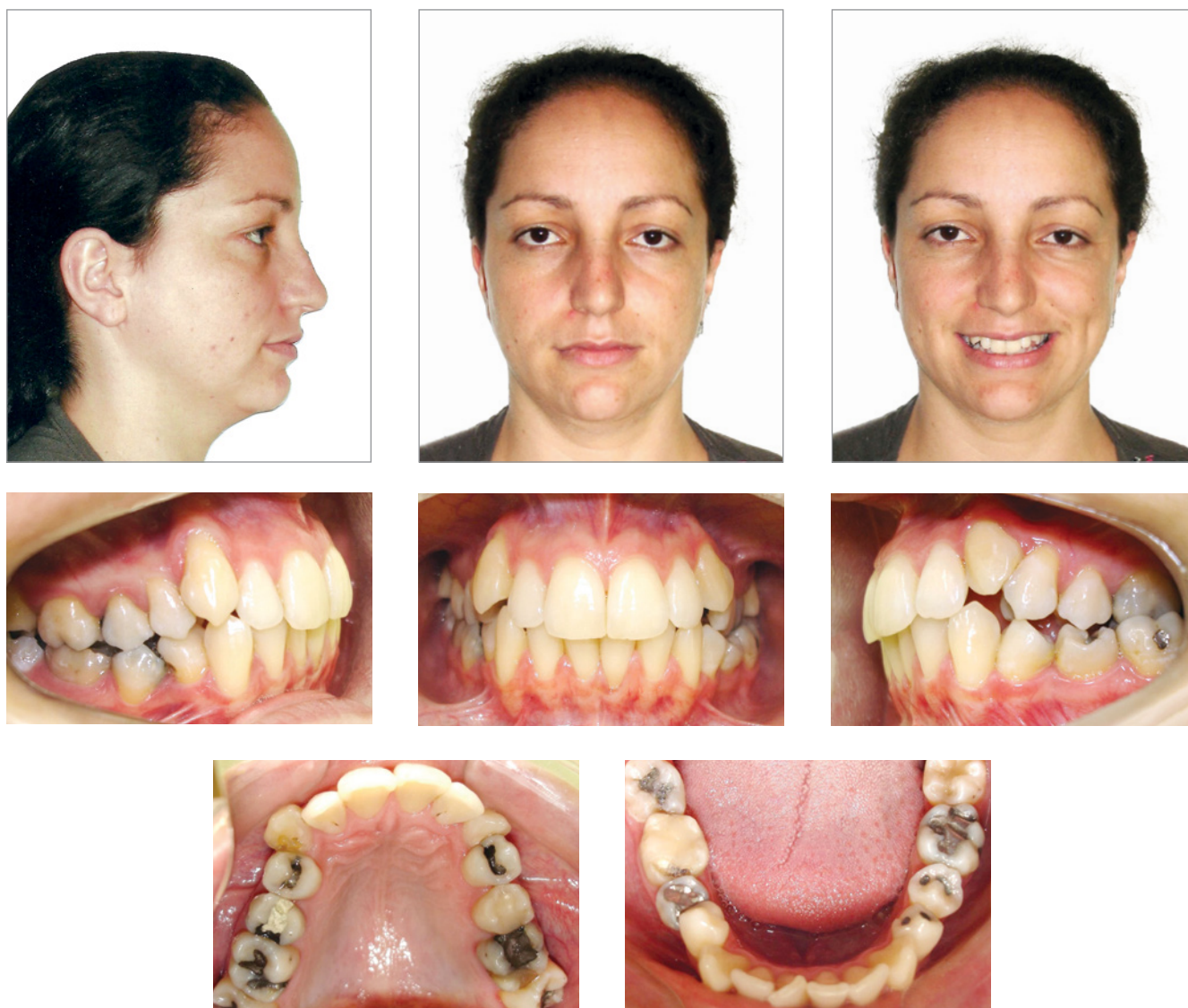

Figure 1 - Pretreatment facial and intraoral photographs.

on the left side (Fig 1). The panoramic radiograph exhibited all teeth except for the third molars. Also, there was significant horizontal bone loss for the age at the premolar region; endodontic treatment of tooth 46 and impairment of dental health due to large restorations in several teeth (Fig 2).

Cephalometric analysis revealed skeletal Class I relationship ( $ANB=1^\circ$ ). Considering occlusal plane angle values

( $SN.Ocl=33^\circ$ ), mandibular plane ( $SN.GoGn=42^\circ$ ) and Y axis ( $Y-axis=62^\circ$ ), a hyperdivergent skeletal pattern prevailed. The maxillary incisors were buccally tipped and protruded ( $1-NA=9\text{ mm}$  and  $1.NA=26^\circ$ ) and the mandibular incisors were well positioned ( $1-NB=6\text{ mm}$  and  $1.NB=25^\circ$ ,  $IMPA=90^\circ$ ). The upper lip was retruded in 4 mm and the lower, in 2 mm in relation to the S line (Fig 3 and Table 1).

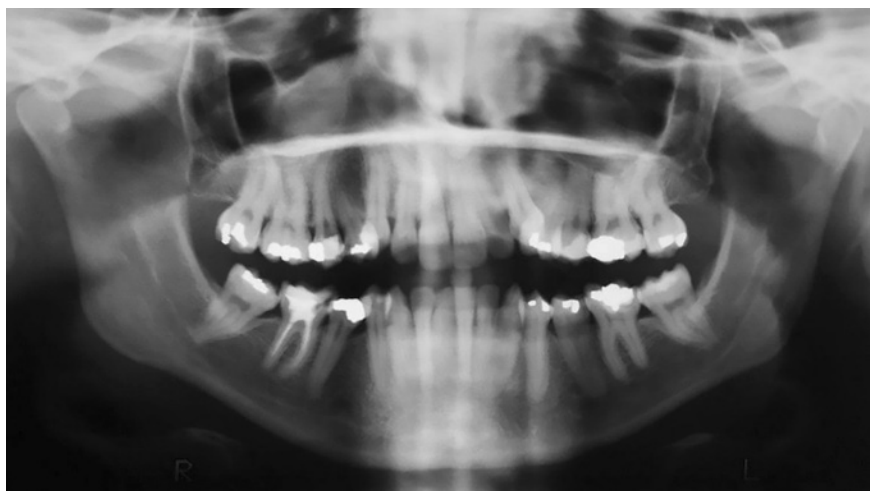

Figure 2 - Initial panoramic radiograph.

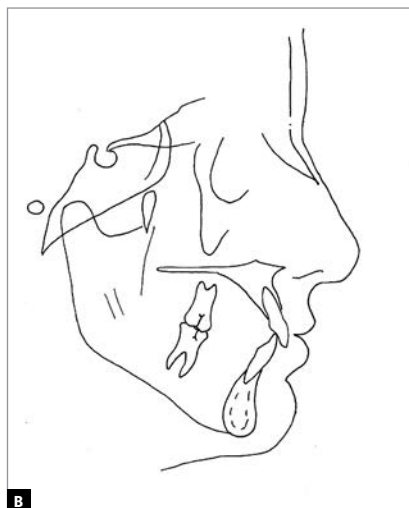
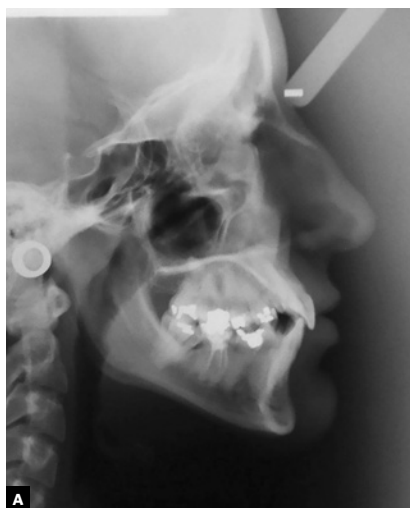

Figure 3 - Initial lateral cephalogram (A) and tracing (B).

## TREATMENT PLAN AND APPLIED MECHANICS

The treatment objectives were to obtain normal occlusion, adequate overjet and overbite, correct the crowding and axial inclinations of maxillary anterior teeth, thus improving function, facial esthetics and smile characteristics. The treatment options were: extractions of four first premolars, extractions of maxillary first premolars and mandibular second premolars, extractions of the four second premolars, or the utilization of temporary anchorage devices to distalize the mandibular posterior teeth.

It was decided to extract the second premolars to avoid incisor retraction and undesirable change in the facial profile.

Initially, Edgewise brackets with 0.022×0.028-in slot were placed on the molars and first premolars (3M Unitek, Monrovia, CA) and a Nance button for anchorage. An archwire with “teardrop loops”<sup>25,26</sup> was placed in the edentulous space and also on the mesial surface of the first premolars in both arches, to retract

these teeth to the extraction spaces (Fig 4). Following, brackets were bonded on the canines, which were retracted with Tweed multiloop archwire.<sup>25,26</sup> After that, brackets were bonded on the incisors for alignment and leveling with 0.0175-in coaxial archwire and 0.014-in to 0.020-in stainless steel archwires. The mechanics for incisor retraction was applied with a 0.019×0.025-in “vertical closing loops archwire” with 6-mm vertical loops for final incisor retraction, which was completed in 8 months (Fig 5). Mounting was performed in a Bio-Art semi-adjustable articulator (Bio-Art Equipamentos Odontológicos Ltda, São Carlos/SP, Brasil), to check the interdigitation, intercuspation on the palatal aspect and protrusion and lateral guidances. The rebonding of some brackets was guided by the panoramic radiograph, as well as maxillary re-leveling, followed by 0.019×0.025-in stainless steel archwires with ideal torques. Posterior vertical intermaxillary elastics were applied for intercuspation and finalization. The total treatment time was 36 months.

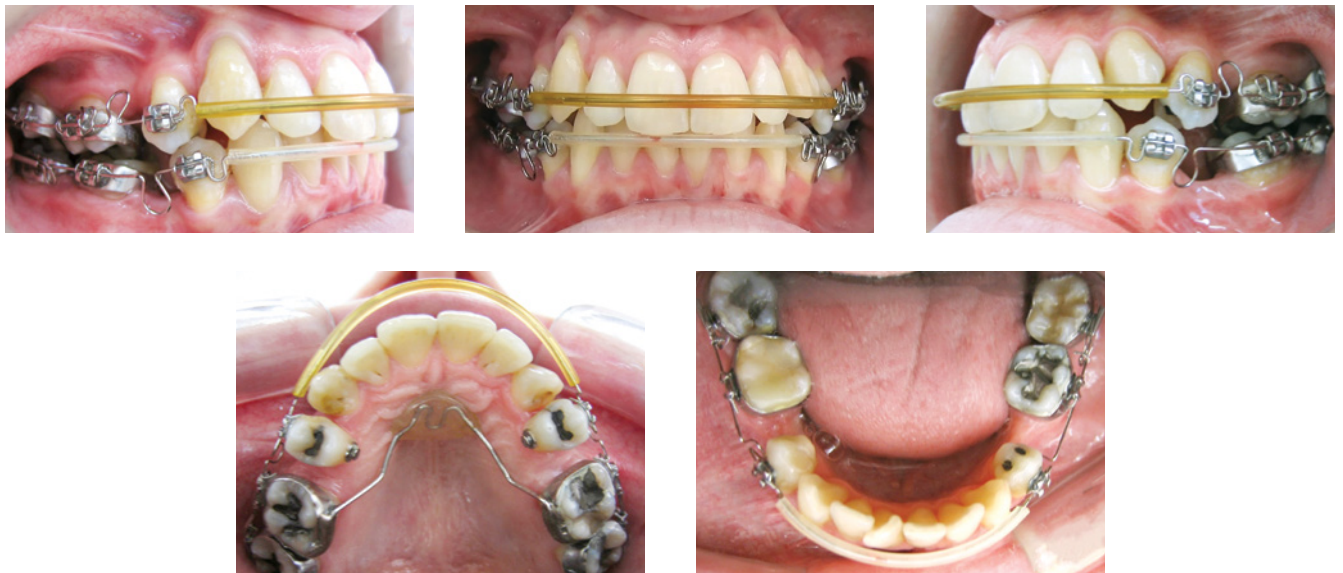

Figure 4 - Intermediate intraoral photographs with Tweed teardrop loops archwire.



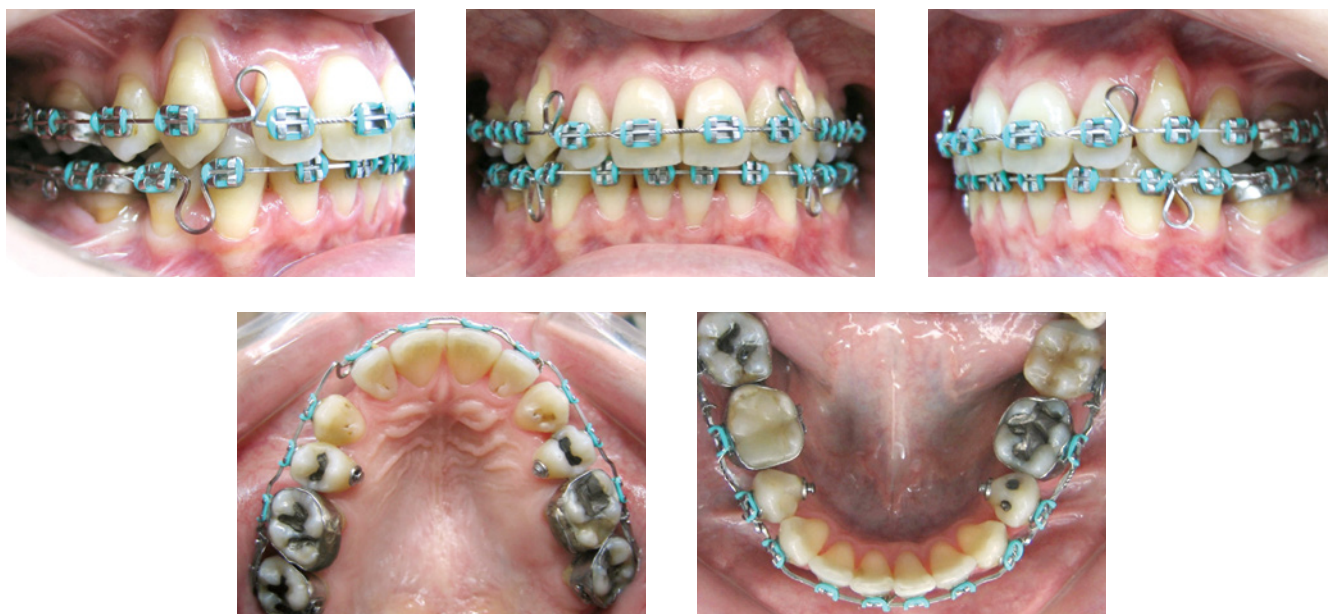

Figure 5 - Intermediate intraoral photographs with retraction archwire.

## OBTAINED RESULTS

The posttreatment photographs confirmed that the extraction of premolars did not impair the profile. The adequate alignment and torque of anterior teeth provided support to the upper lip, enhancing the esthetics of the profile. The adequacy of tooth-size discrepancy and alignment filled the buccal corridor, providing greater amplitude, youth and attractiveness to the smile (Fig. 6).

Analysis of the intraoral aspect evidenced Class I occlusion with ideal overjet and overbite, correction of crowding, coincident dental and facial midlines and solid interdigitation between the dental arches, including the second molars.

Adequate arch shapes were achieved, with teeth well positioned in the dental arches and maintenance of intercanine distance in the mandibular arch. The treatment also provided functional occlusion and good periodontal health, despite the gingival recessions. The determining factors of equipotent simultaneous bilateral contacts and immediate disocclusion in mandibular movements were established (Fig 6). The panoramic radiograph evidenced good root parallelism and integrity of dental roots (Fig 7).

The posttreatment cephalogram and superimpositions illustrate the changes achieved by treatment, evidencing slight changes in the nose and pogonion. The relationship between the lips and the Steiner's S line remained unchanged, without damage to the pro-

file (Upper lip to S Line = - 4 mm, Lower lip to S Line = - 2 mm). Also, the convexity angle increased 1°, despite the extractions. The applied mechanics did not yield undesirable mandibular rotation or mandibular plane opening (Fig 8 and Table 1).

The maxillary first molars were upright, remaining in the original position. There was uprighting of maxillary incisors and correction of torques, maintaining satisfactory inclination. The mild extrusion enhanced the exposure of maxillary teeth at rest and during smiling. The remodeling of point A, which was advanced in 1 mm, enhanced the support to the upper lip without flattening the profile (Fig 9A). There was marked mesial movement of mandibular first molars combined with more anterior mandibular positioning, which contributed to correct the molar relationship to Class I. The intrusion of mandibular incisor corrected the moderate overbite, which is compatible with extrusion of the maxillary incisor. The IMPA had slight variation from 90° to 92°, indicating that the incisor remained well-positioned in relation to the mandibular plane (Fig 9B and Table 1).

The follow-up 5 years after completion of the active treatment stage revealed stable outcomes, accommodation of teeth allowing better occlusal relationship, and closure of small diastemata that were still present upon appliance removal. Also, the gingival recessions have remained stable (Fig 10).

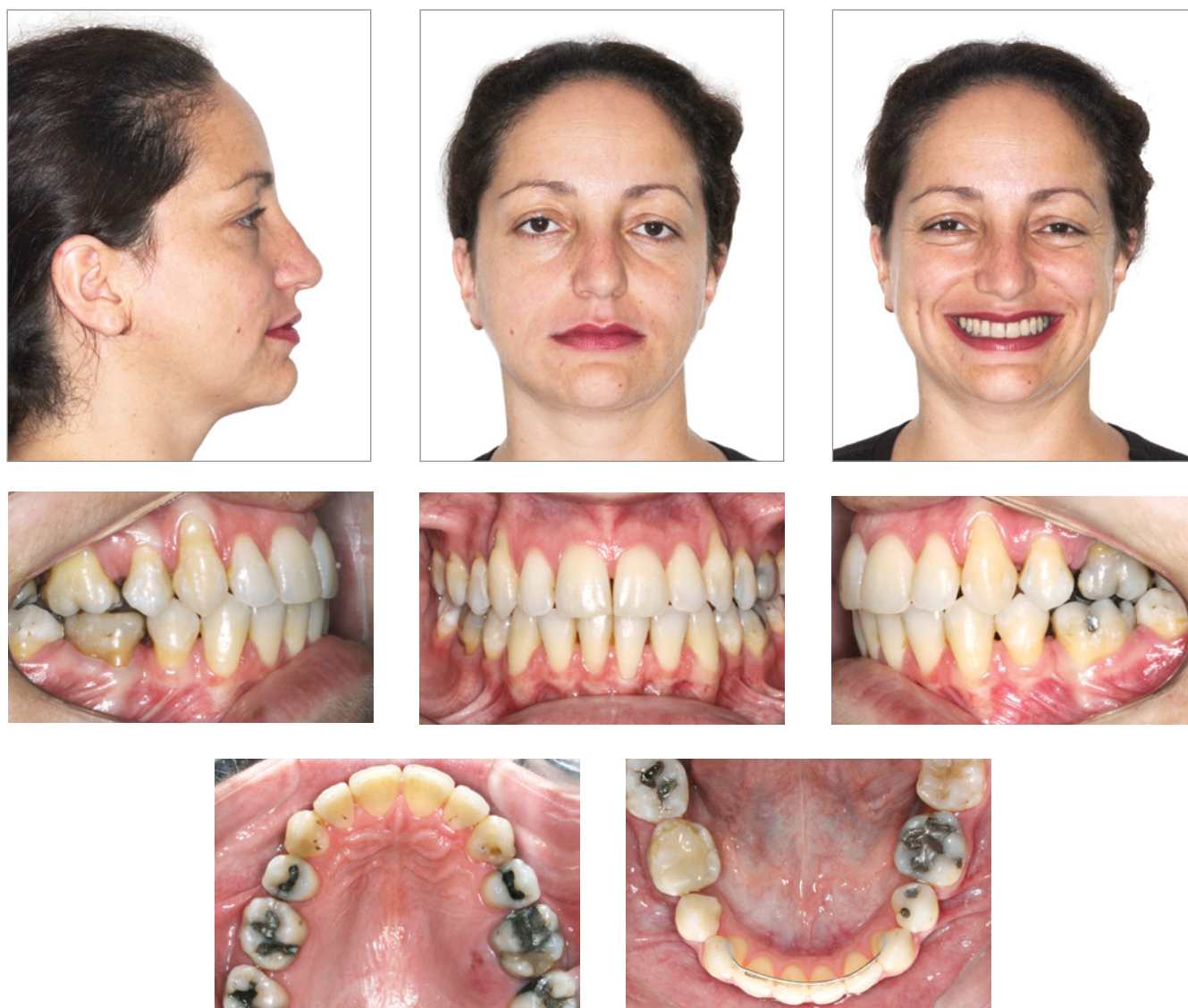

Figure 6 - Final facial and intraoral photographs.

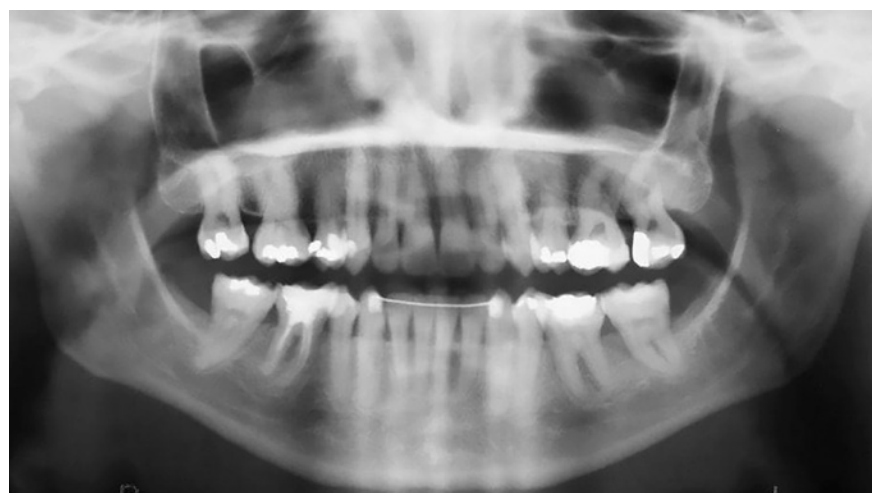

Figure 7 - Final panoramic radiograph.

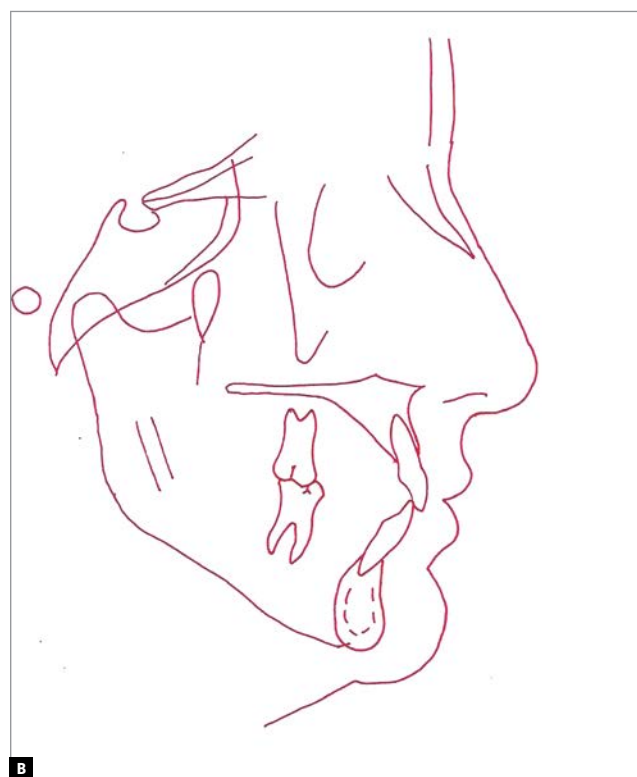
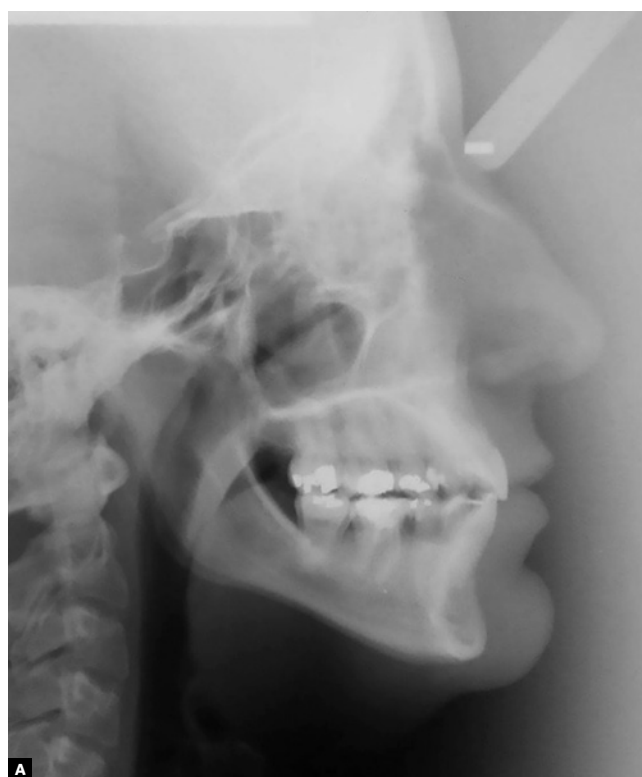

Figure 8 - Final lateral cephalogram (A) and tracing (B).

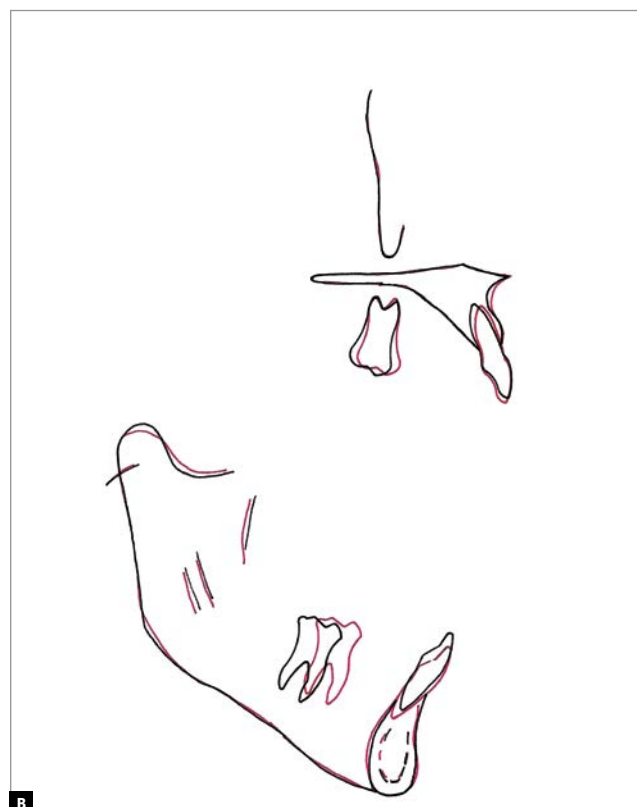
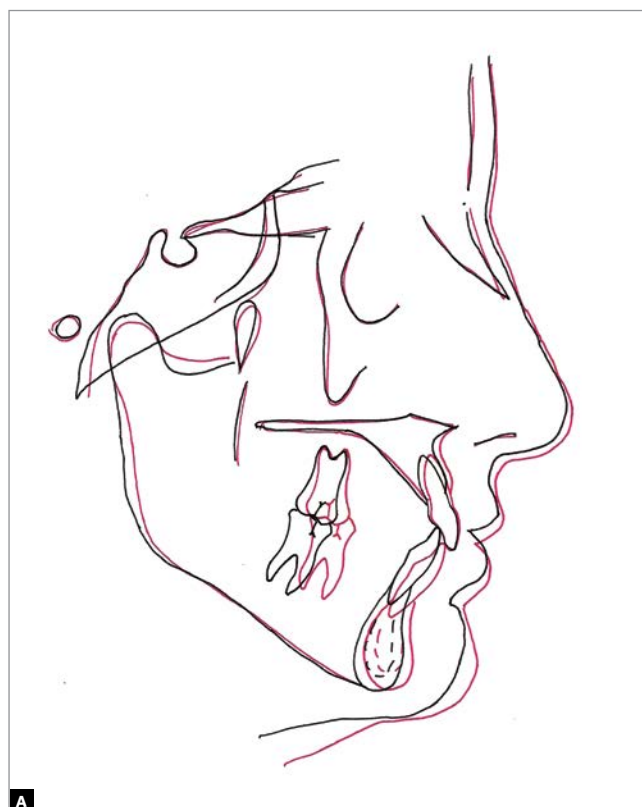
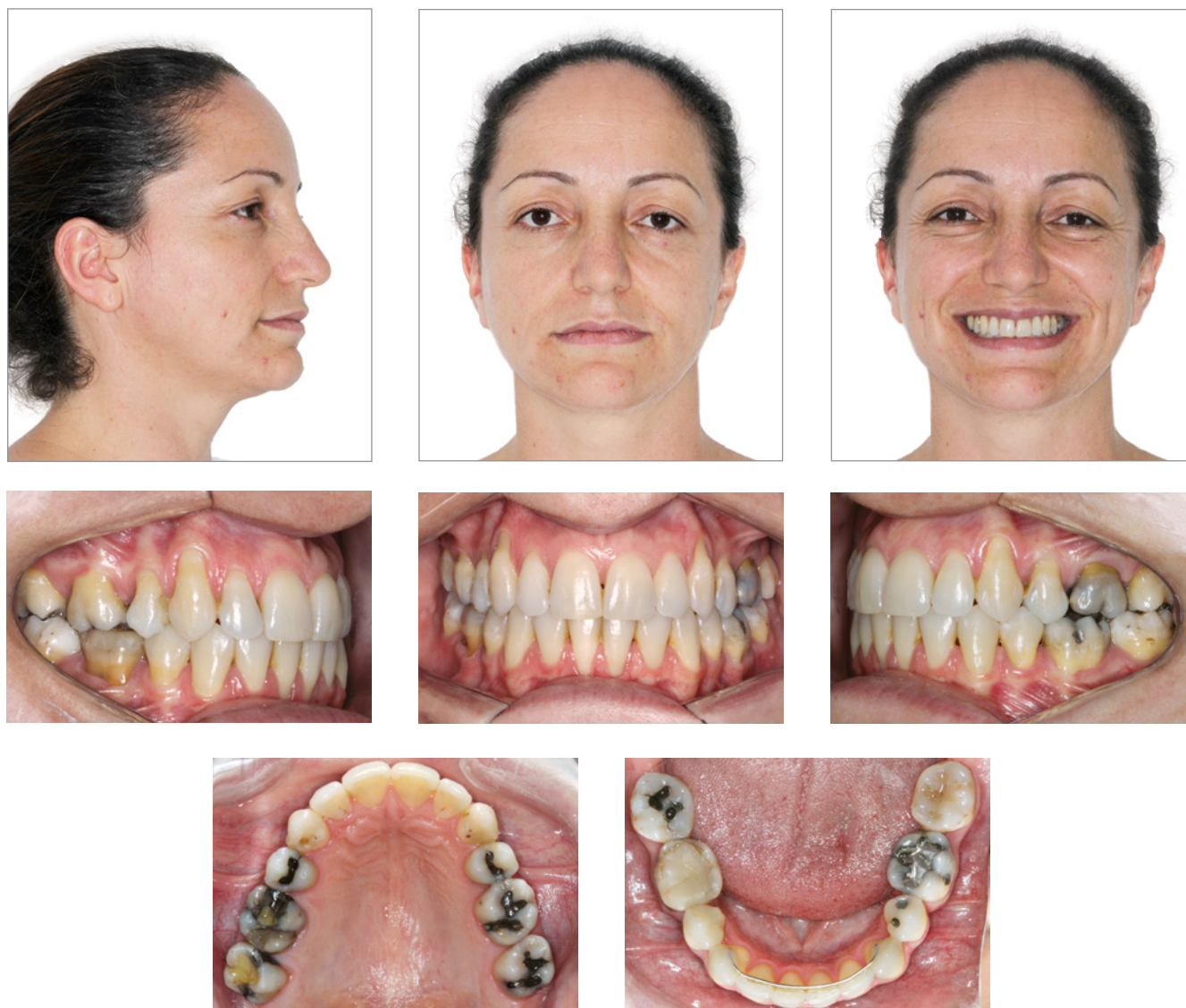

Figure 9 - Total (A) and partial (B) superimpositions of initial (black) and final (red) cephalometric tracings.





**Figure 10** - Final facial and intraoral photographs at 5-year follow-up.



Table 1 - Initial (A) and final (B) cephalometric values

Measurements			Normal	A	B	A/B diff.
Skeletal pattern	SNA	(Steiner)	82°	73°	74°	1
	SNB	(Steiner)	80°	72°	72°	0
	ANB	(Steiner)	2°	1°	2°	1
	Wits	(Jacobson)	♀ 0 ±2mm ♂ 1 ±2mm	- 8	0	8
	Angle of convexity	(Downs)	0°	1°	2°	1
	Y-axis	(Downs)	59°	62°	62°	0
	Facial angle	(Downs)	87°	83°	84°	1
	SN-GoGn	(Steiner)	32°	42°	41°	1
	FMA	(Tweed)	25°	33°	33°	0
Dental pattern	IMPA	(Tweed)	90°	90°	92°	2
	⊥NA (degrees)	(Steiner)	22°	26°	20°	6
	⊥NA (mm)	(Steiner)	4mm	9mm	5mm	4
	⊥NB (degrees)	(Steiner)	25°	25°	29°	4
	⊥NB (mm)	(Steiner)	4mm	6mm	6mm	0
	$\frac{1}{1}$ - Interincisal angle	(Downs)	130°	128°	129°	1
Profile	⊥APo	(Ricketts)	1mm	5mm	5mm	0
	Upper lip — S-line	(Steiner)	0mm	- 4mm	- 4mm	0
	Lower lip — S-line	(Steiner)	0mm	- 2mm	- 2mm	0

## DISCUSSION

The success of orthodontic treatment depends on the careful analysis of all diagnostic elements and establishment of a correct treatment planning. Among the several decisions, the professional should determine if the success of intervention requires dental extractions.<sup>2,10,13,15</sup> The extractions with orthodontic purpose, for correction of tooth crowding or intermaxillary discrepancies, have been controversial since the concepts of normal occlusion were initially enhanced, in the early 20<sup>th</sup> century.<sup>3,11,16,17,27-29</sup> Any tooth may be extracted, depending on each case, to provide more satisfactory esthetic and functional outcomes. Within this sense, there is consensus that the planning of orthodontic treatment should be customized.<sup>14,24,30</sup>

Based on these principles, the diagnosis of the need of adequacy of tooth size to the dental arches in this adult patient revealed the need of extractions. Correction of this malocclusion with extractions could have been a problem, especially for a patient with concave profile and thin upper lip. The weakened crown and need of endodontic treatment in the maxillary right second premolar, combined to the fact that the extraction of first premolars may excessively retract the facial profile, led to indication for extraction of second premolars.<sup>26</sup>

This extraction pattern resulted in a stable relationship between upper and lower lips and the Steiner's S Line (Upper lip to S Line = -4mm, Lower lip to S Line = -2mm). The same result was presented by James<sup>6</sup>, who concluded that the extractions of maxil-

lary and mandibular second premolars do not change the lower lip positioning in relation to the facial esthetic line of Ricketts.<sup>31,32</sup>

Tooth extractions might increase the profile concavity; however, the selected sequence of extractions, remodeling of point A of 1 mm and the mild extrusion of maxillary incisors provided greater support to the lips, enhancing the exposure of maxillary teeth at rest and during smiling. The extractions of second premolars allowed better control of incisors and of the lip retraction, avoiding the marked concavity of the facial profile that occurs after extractions of first premolars.<sup>11,12</sup> Indicated in cases with moderate shortage of space, in individuals with balanced facial contours and well-positioned incisors in their dental arches, the extraction of second premolars is justified in the literature.<sup>11,12</sup>

Nance<sup>11</sup> indicated the extraction of maxillary first premolars and mandibular second premolars in borderline cases with mild biprotrusion, in which the extractions of first premolars may excessively retract the facial profile. This was later corroborated by other investigators.<sup>16,17,33</sup> James<sup>6</sup> and Dewel<sup>3,28</sup> described the moderate space deficiency, which is characteristic of borderline cases in individuals with balanced facial contours, as one of the basic diagnostic requirements for indication of extractions of second premolars. According to Carey,<sup>29</sup> better results were achieved when malocclusions with discrepancies between 2.5 and 5 mm were treated by extraction of second premolars. However, according to Schoppe,<sup>34</sup> the main indication included cases with discrepancies up to 7.5 mm, in individuals with muscular balance, proportional facial contour and incisors well-positioned in the dental arches. Confirming these findings, Castro<sup>12</sup> described the advantages of extraction of second premolars for cases with need of extractions, especially for patients with satisfactory profile and favorable mandibular growth.

Conversely, some authors did not observe direct correlation between the tooth to be extracted and lip

positioning. However, they agree that the pretreatment and growth characteristics lead to different facial outcomes.<sup>18-21</sup>

In the present case, the effects of the adopted mechanics benefited the soft tissue profile of this patient. The uprighting of anterior teeth without retraction was especially important to maintain the upper lip support, which could have been a problem if the therapeutic approach had neglected the initial concave profile of the patient. According to Burstone et al,<sup>35,36</sup> many factors affect lips position, including several orthodontic and surgical procedures. A good position of the lip can be obtained by surgically or orthodontically protruding incisors, increasing/reducing the chin prominence, or both.<sup>8</sup> Specifically, in the present case, the Tweed tear-drop archwire was selected, associated to the Nance button for anchorage control, for retraction of first premolars and canines. The anterior teeth were bonded and included at a later moment to protect the profile, which is demonstrated in the superimpositions. Also, according to Legan et al,<sup>36</sup> the controlled retraction of mandibular incisors associated to the extrusion of maxillary teeth maintain the lip support, as in the present case.

Different from the findings of Herzog et al,<sup>2</sup> the mandibular intercanine distance was maintained, assuring stability of the achieved results 5 years after treatment.<sup>37,38</sup>

## CONCLUSION

Although many innovative techniques have emerged over the past few years, this paper evidences that traditional treatment is still an excellent alternative, providing lasting results for shortage of space or crowding. The extractions of second premolars may assure the profile integrity when the challenge is to achieve space in cases of negative tooth-size discrepancy.

The professionals should be aware of the diagnosis and planning of the ideal pattern of tooth extractions, to achieve the esthetics of the profile and facial balance, as well as functional occlusion and stability.

## REFERENCES

- Conley SR, Jernigan C. Soft Tissue Changes after Upper Premolar Extraction in Class II Camouflage Therapy. *Angle Orthod.* 2006 Jan;76(1):59-65.
- Herzog C, Konstantonis D, Konstantoni N, Eliades T. Arch-width changes in extraction vs nonextraction treatments in matched Class I borderline malocclusions. *Am J Orthod Dentofacial Orthop.* 2017 Apr;151(4):735-43.
- Dewel BF. Extraction in orthodontics: premises and prerequisites. *Angle Orthod.* 1973 Jan;43(1):65-87.
- Merrifield LL. The profile line as an aid in critically evaluating facial esthetics. *Am J Orthod.* 1966;52(11):804-22.
- Erdinc AE, Nanda RS, Dandajena TC. Profile changes of patients treated with and without premolar extractions. *Am J Orthod Dentofacial Orthop.* 2007 Sept;132(3):324-31.
- James RD. A comparative study of facial profiles in extraction and nonextraction treatment. *Am J Orthod Dentofacial Orthop.* 1998 Sept;114(3):265-76.
- Bishara SE, Cummins DM, Jakobsen JR, Zaher AR. Dentofacial and soft tissue changes in Class II, division 1 cases treated with and without extractions. *Am J Orthod Dentofacial Orthop.* 1995 Jan;107(1):28-37.
- Janson G, Fuziy A, Freitas MR, Castanha Henriques JF, Almeida RR. Soft-tissue treatment changes in Class II Division 1 malocclusion with and without extraction of maxillary premolars. *Am J Orthod Dentofacial Orthop.* 2007 Dec;132(6):729.e1-8.
- Hemmatpour S, Mokhtar A, Rakhshan V. Effects of Sabbagh Universal Spring 2 fixed functional appliance on Class II/1 patients at their postpubertal-peak growth period compared with the extraction method: a randomized clinical trial. *J Orofac Orthop.* 2017 Jan;78(1):41-51.
- Allgayer S, Lima EMS, Rizzatto SD, Tavares CAE, Menezes LM, Mezomo MB. Profile changes in premolar extraction. *Rev Odonto Cienc.* 2011;26(4):304-9.
- Nance HN. The removal of second premolars in orthodontic treatment. *Am J Orthod.* 1949 Sept;35(9):685-96.
- Castro N. Second-premolar extraction in clinical practice. *Am J Orthod.* 1974 Feb;65(2):115-37.
- Cheng HC, Wang YC. Effect of nonextraction and extraction orthodontic treatments on smile esthetics for different malocclusions. *Am J Orthod Dentofacial Orthop.* 2018 Jan;153(1):81-6.
- Jackson TH, Guez C, Lin F-C, Proffit WR, Ko C-C. Extraction frequencies at a university orthodontic clinic in the 21st century: Demographic and diagnostic factors affecting the likelihood of extraction. *Am J Orthod Dentofacial Orthop.* 2017 Mar;151(3):456-62.
- Allgayer S, Lima EMS, Mezomo MB. Influence of premolar extractions on the facial profile evaluated by the Holdaway analysis. *Rev Odonto Cienc.* 2011;26(1):22-9.
- Logan LR. Second premolar extraction in Class I and Class II. *Am J Orthod.* 1973 Feb;63(2):115-47.
- Schwab DT. Extraction effects on the dental profile in borderline cases. *Angle Orthod.* 1963;33(2):120-2.
- Shearn BN, Woods MG. An occlusal and cephalometric analysis of lower first and second premolar extraction effects. *Am J Orthod Dentofacial Orthop.* 2000 Mar;117(3):351-61.
- Ong HB, Woods MG. An occlusal and cephalometric analysis of maxillary first and second premolar extraction effects. *Angle Orthod.* 2001 Apr;71(2):90-102.
- Wholley CJ, Woods MG. The effects of commonly prescribed premolar extraction sequences on the curvature of the upper and lower lips. *Angle Orthod.* 2003 Aug;73(4):386-95.
- Moseling KP, Woods MG. Lip curve changes in females with premolar extraction or nonextraction treatment. *Angle Orthod.* 2004 Feb;74(1):51-62.
- Basciftci FA, Uysal T, Buyukerkmen A, Demir A. The influence of extraction treatment on Holdaway soft-tissue measurements. *Angle Orthod.* 2004 Apr;74(2):167-73.
- Oliver BM. The influence of lip thickness and strain on upper lip response to incisor retraction. *Am J Orthod.* 1982 Aug;82(2):141-9.
- Jackson TH. Authors' response. *Am J Orthod Dentofacial Orthop.* 2017;152:9-10.
- Tweed CH. *Clinical orthodontics*. 3rd ed. Saint Louis: Mosby; 1966.
- Grabner TM, Vanardall RL. *Orthodontics current principles and techniques*. 2nd ed. Saint Louis: Mosby; 1994.
- Proffit WR, Fields HW. *Ortodontia Contemporânea*. Rio de Janeiro: Guanabara Koogan; 1995.
- Dewel BF. Second premolar extraction in orthodontics: principles, procedures, and case analysis. *Am J Orthod Dentofacial Orthop.* 1955;41(2):107-20.
- Carey CW. Light force technique combining the sliding section and laminated arches. *Am J Orthod.* 1966 Feb;52(2):85-102.
- Dahiya G, Masoud AI, Viana G, Obrez A, Kusnoto B, Evans CA. Effects of unilateral premolar extraction treatment on the dental arch forms of Class II subdivision malocclusions. *Am J Orthod Dentofacial Orthop.* 2017 Aug;152(2):232-41.
- Ricketts RM. Perspectives in the clinical application of cephalometrics. *Angle Orthod.* 1981 Apr;51(2):115-50.
- Ricketts RM. Cephalometric synthesis. *Am J Orthod.* 1960 Sept;46(9):647-73.
- Schwab DT. The borderline patient and tooth removal. *Am J Orthod.* 1971;59(2):126-45.
- Schoppe RJ. An analysis of second premolar extraction procedures. *Angle Orthod.* 1964;34(4):292-302.
- Burstone CJ. Lip posture and its significance in treatment planning. *Am J Orthod.* 1967 Apr;53(4):262-84.
- Legan HL, Burstone CJ. Soft tissue cephalometric analysis for orthognathic surgery. *J Oral Surg.* 1980 Oct;38(10):744-51.
- Riedel RA. A review of the retention problem. *Angle Orthod.* 1960 Oct;30:179-99.
- Heiser W, Richter M, Niederwanger A, Neunteufel N, Kulmer S. Association of the canine guidance angle with maxillary and mandibular intercanine widths and anterior alignment relapse: Extraction vs nonextraction treatment. *Am J Orthod Dentofacial Orthop.* 2008 May;133(5):669-80.