

Facial profile changes due to bone cement graft to manage the hyperactive muscles of the gingival smile

Érica Miranda de **Torres**¹, José **Valladares-Neto**², Karina de Oliveira **Bernades**³,
Luis Fernando **Naldi**⁴, Hianne Miranda de **Torres**³, Alexandre Leite **Carvalho**³, Carlos **Estrela**⁵

DOI: <https://doi.org/10.1590/2177-6709.25.2.044-051.oar>

Objective: To evaluate facial profile changes promoted by polymethyl methacrylate (PMMA) cement graft to reduce excessive gingival display due to hyperactivity of the elevator muscles of the upper lip during smiling.

Methods: Eleven patients (all females, age range: 20 to 43 years) presenting gingival smile that were treated with PMMA cement grafts in a private clinic were selected for this retrospective study. Three angular and ten linear cephalometric facial profile measurements were performed preoperatively (baseline, T₁) and at least 6 months postoperatively (T₂). Differences between T₁ and T₂ were verified by Wilcoxon test, and the correlation between the thickness of the graft and facial profile changes was statistically evaluated by Spearman's Coefficient test. The significance level was set at $p < 0.05$.

Results: The nasolabial angle ($p = 0.03$) and the labial component of the nasolabial angle showed statistically significant differences ($p = 0.04$), with higher values in T₂. No correlations were found between the graft thickness and the statistically significant facial profile changes ($p > 0.05$).

Conclusions: The PMMA bone cement graft projected the upper lip forward, thereby increasing the nasolabial angle without affecting the nasal component. No correlations between the graft thickness and the facial profile changes were detected.

Keywords: Gingival smile. Bone cement. Polymethyl methacrylate. Facial profile.

¹ Universidade Federal de Goiás, Faculdade de Odontologia, Divisão de Reabilitação Oral (Goiânia/GO, Brazil).

² Universidade Federal de Goiás, Faculdade de Odontologia, Divisão de Ortodontia (Goiânia/GO, Brazil).

³ Universidade Federal de Goiás, Programa de Pós-graduação em Odontologia, Faculdade de Odontologia (Goiânia/GO, Brazil)

⁴ Universidade Federal de Goiás, Faculdade de Odontologia, Divisão de Periodontia (Goiânia/GO, Brazil).

⁵ Universidade Federal de Goiás, Faculdade de Odontologia, Divisão de Endodontia (Goiânia/GO, Brazil).

» Patients displayed in this article previously approved the use of their facial and intraoral photographs.

How to cite: Torres EM, Valladares-Neto J, Bernades KO, Naldi LF, Torres HM, Carvalho AL, Estrela C. Facial profile changes due to bone cement graft to manage the hyperactive muscles of the gingival smile. *Dental Press J Orthod.* 2020 Mar-Apr;25(2):44-51.

DOI: <https://doi.org/10.1590/2177-6709.25.2.044-051.oar>

Submitted: December 04, 2018 - **Revised and accepted:** February 20, 2019.

» The authors report no commercial, proprietary or financial interest in the products or companies described in this article.

Contact address: Érica Miranda de Torres
Av. Universitária, esquina com 1ª Avenida, s/ número
CEP: 74.605-220, Goiânia/GO – Brasil
E-mail: torresodonto@yahoo.com.br

INTRODUCTION

The smile is the spontaneous expression linked to joy, pleasure and receptivity.¹ Tarantili et al.² defined a pleasant smile as one in which there is complete exposure of the anterior maxillary teeth and a mild gingival display of 1 to 3 mm. An excessive gingival display greater than 3 mm is considered unpleasant or unattractive, and is popularly called “gummy smile”.^{1,3,4}

Several etiological factors have been associated to gingival smile, and it is important for the clinician to properly identify its etiology, for an adequate treatment. These factors occur separately or in combination,⁴⁻⁸ and according to the origin, they can be grouped into: dental (excessive dentoalveolar extrusion⁹), gingival (altered passive eruption^{10,11} or gingival enlargement¹²), skeletal (excessive maxillary vertical growth⁸) or muscular (short upper lip or hyperactivity of the elevator muscles of the upper lip^{1,2,6}). For this reason, various treatments have been proposed according to the etiology of the gingival smile, including orthodontic intrusion,^{5,7,9} gingivectomy,^{7,13} periodontal plastic surgery,¹³ maxillary teeth intrusion by skeletal anchorage,^{14,15} maxillary impaction by orthognathic surgery;^{7,8} upper lip repositioning,¹⁶⁻¹⁹ and botulinum toxin injection.²⁰⁻²²

Recently, a new surgical technique for the management of the gingival smile was proposed by Naldi et al.²³⁻²⁵ The technique consists in implanting a bone cement graft based on polymethyl methacrylate (PMMA) in the anterior maxilla below the pyriform aperture. According to the authors, some patients with a gingival smile have a major subnasal depression that allows the upper lip to be lodged during spontaneous smile. The PMMA bone cement graft fills this depression, preventing excessive displacement of the upper lip during contraction. The graft, associated with esthetic crown lengthening, has been shown to be effective in reducing gingival display.²³⁻²⁵ An internal bevel incision followed by a reflected full-thickness flap is performed until exposure of the subnasal depression. The PMMA bone cement is indicated by the manufacturer for use in fixing orthopedic prostheses to bone tissue. It is manipulated (powder and liquid) and adapted to the region of interest. After polymerization, the PMMA graft is fitted with drills, for better volume and conformation. Two screw fixations are used to immobilize the PMMA graft in the subnasal depression. Sutures are inserted and removed 10 days later.²³⁻²⁵ Figure 1 illustrates this surgical technique and the outcomes.

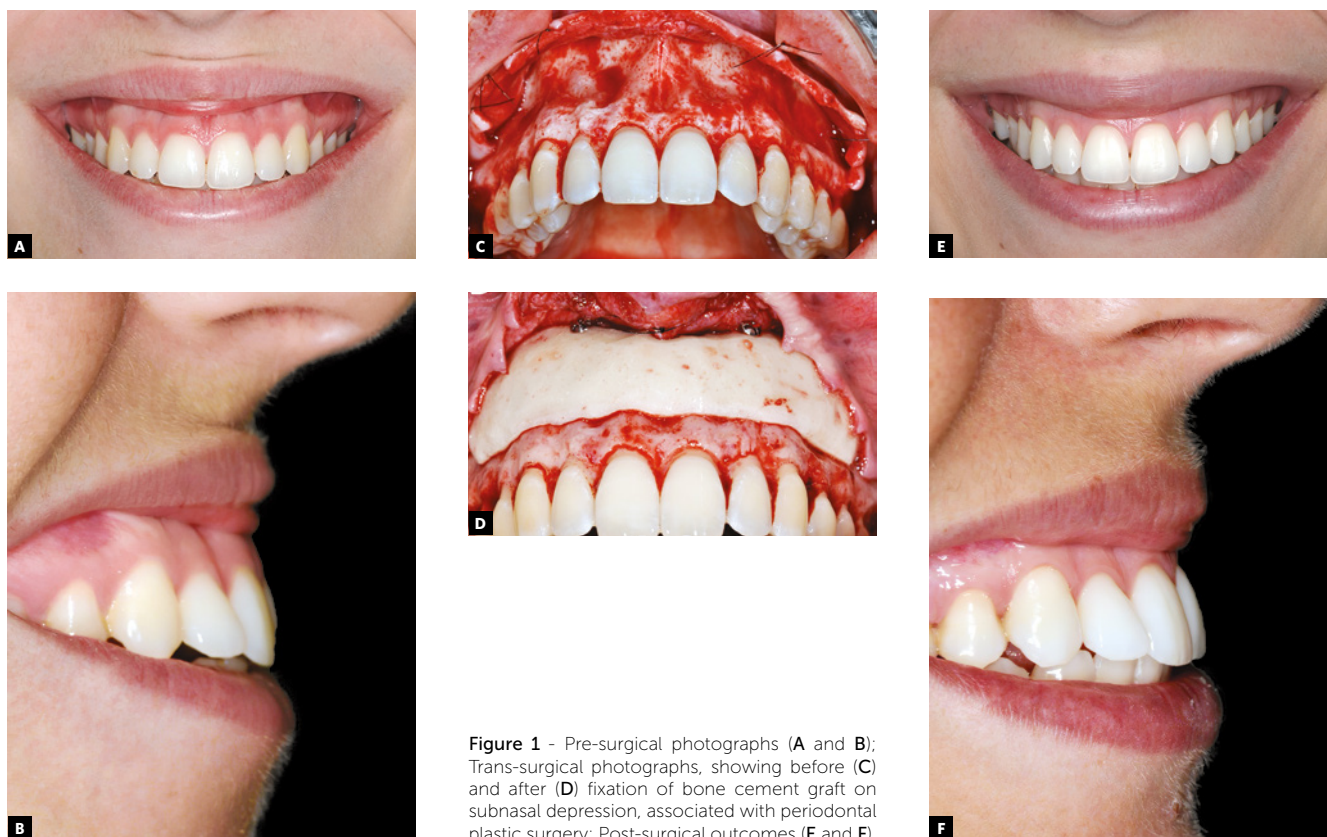

Figure 1 - Pre-surgical photographs (A and B); Trans-surgical photographs, showing before (C) and after (D) fixation of bone cement graft on subnasal depression, associated with periodontal plastic surgery; Post-surgical outcomes (E and F).

PMMA is biocompatible and effective for reduction of the gingival smile; in addition, complications or adverse reactions, such as implant or bone resorption in the recipient region, were not reported in the medium term.²³⁻²⁵ However, there is still no information about the impact of this technique on the changes in facial profile. Thus, the aim of the present study was to test the null hypothesis that PMMA cement implanted to manage the gingival smile is not able to introduce changes in facial profile at rest. In addition, this study also aimed to determine whether a correlation exists between the thickness of the bone cement and a possible change in facial profile.

MATERIAL AND METHODS

The research protocol of this retrospective study was reviewed and approved by the Research Ethics Committee of the Federal University of Goiás (Goiânia, Brazil; CEP/UFG – 065/2011). The STROBE guidelines for observational studies were followed.²⁶

Sample

The sample initially comprised 38 patients submitted to the implantation of bone cement based on PMMA (Aminofix 3, Groupe Lepine, France) at a private clinic in the city of Goiânia, Goiás, Brazil. The same surgeon operated all the patients, between November 2007 and April 2012. Among the initial sample, 11 met the inclusion criteria. All were women, aged from 20 to 43 years. The inclusion criteria were as follows: patients with gingival smile due to hyperactive muscles, treated with bone cement graft; 18 years-old or older; presence of pre- and postsurgical cephalometric radiographs with relaxed lips. The cases of hyperactivity of the elevator muscle of the upper lip involved both functional and morphological evaluation. Firstly, patients presented with high lip dynamics and, secondly, with a major subnasal depression that allows the upper lip to lodge during a spontaneous smile. The exclusion criteria were: poor image quality; cleft lip or cleft lip and palate; craniofacial syndromes; and other surgical interventions that could change the soft and hard tissues of the face during the period of study. For this study, cephalometric radiographs had been taken prior to treatment (T₁) and at least six months after surgery (T₂) from 11 patients submitted to surgical implantation of grafts based on PMMA.

Cephalometric analysis

The cephalometric radiographs (lateral cephalometric radiographs) were taken using the same cephalostat at T₁ and T₂ with an enlargement factor near to 1.0645 (6.45 percent). The patients were in a standing position and adequately protected, with the teeth in centric occlusion, lips in relaxed position, and Frankfurt plane parallel to the floor. Radiographic films were developed in an automatic processor (Flat Co., Japan).

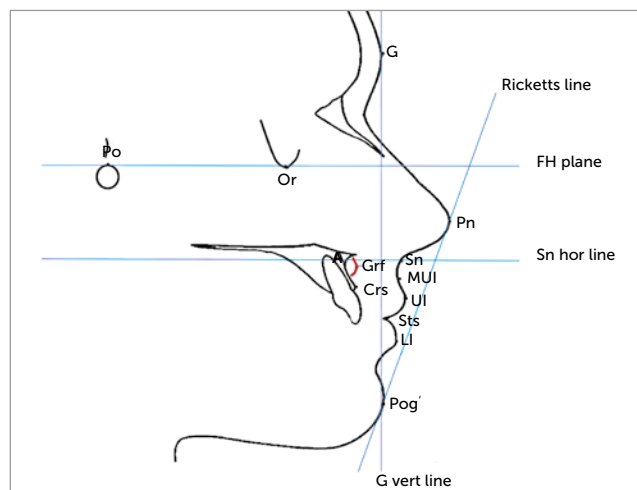


Figure 2 - Definitions of cephalometric landmarks and reference planes used in the study.

Table 1 - Definitions of cephalometric landmarks and reference planes.

Po (Porion)	The upper most point of the body of the external auditory meatus, usually regarded as coincidental with the ear rods of the cephalostat
Or (Orbitale)	The lowest point on the infraorbital margin
G (Glabella)	The most prominent point on the glabella
Pn (Pronasal)	Most prominent point of the nose in the soft profile
Sn (Subnasal)	Point located at the intersection of the upper lip and base of the nose
UI (Upper lip)	Point located in the most anterior region of the red portion of the upper lip
MUI (Medium Upper Lip)	Midpoint between points UI and Sn
Sts (Stomion)	Highest midline point of upper lip
LI (Lower lip)	Point located in the most anterior region of the red portion of the lower lip
Pog' (Soft Pogonion)	Most anterior point of the outline of the soft chin
Crs (Upper bone crest)	Interproximal bone crest of the upper central incisors
A (Subspinale – A point)	The deepest midline point between the anterior nasal spine and the prosthion
Grf (Graft)	Most anterior point of the graft of PMMA
Ricketts line (Aesthetic line of Ricketts)	Line drawn from the tip of the nose (Pn) to the tip of the chin (Pog')
FH plane (Frankfurt horizontal plane)	Connecting Po and Or points
Sn hor line	Horizontal line parallel to the FH plane passing through Sn point
G vert line	Vertical line perpendicular to the FH plane passing through G point

Table 2 - Linear and angular cephalometric measurements used the study.

Name	Measure	Description
Nasolabial angle	Pn.Sn.UI (degrees)	The angle formed by Pn, Sn and UI points
Nasal component of the nasolabial angle	(Pn-Sn).Sn hor (degrees)	The angle between nasal base (Pn-Sn) and Sn hor line
Labial component of the nasolabial angle	(Sn-UI).Sn hor (degrees)	The angle between the upper lip length (Sn-UI) and Sn hor line
Upper lip concavity	MUI-(Sn-UI) (mm)	The minor linear distance from point MUI to Sn-UI line
Upper lip length	Sn-UI (mm)	The linear distance from points Sn and UI
Upper lip vermilion length	UI-Sts (mm)	The linear distance from points UI and Sts
Upper lip thickness	Crs-UI (mm)	The linear distance between points Crs and UI
Subnasal thickness	A-Sn (mm)	The linear distance between points A and Sn
Medium upper lip thickness	A-MUI (mm)	The linear distance between points A and MUI
Upper lip protrusion	Gvert-UI (mm)	The linear distance between point UI and G vert line
Upper lip anteroposterior position	UI-(Pn-Pog') (mm)	The minor linear distance between point UI and esthetic line of Ricketts (Pn-Pog')
Lower lip anteroposterior position	LI-(Pn-Pog') (mm)	The minor linear distance between point LI and esthetic line of Ricketts (Pn-Pog')
Graft thickness	A-Grf (mm)	The linear distance between points A and Grf

Facial profile was outlined by hand, on acetate paper in a darkened room, by the same experienced and calibrated investigator. A prior calibration was performed with three cephalometric radiographs traced twice by the same investigator, with an interval of two weeks. After confirmation of excellent concordance ($ICC > 0.90$), the overall sample was measured. The cephalometric tracing was composed by the anterior contour of the maxilla, symphysis, maxillary central incisors, external auditory canal and lower border of the orbit, besides the soft tissue profile (Fig 2, Tab. 1). Thirteen skeletal and soft tissue cephalometric landmarks, being three angular and ten linear variables, were measured, including: the nasolabial angle, the nasal component of the nasolabial angle, the labial component of the nasolabial angle, upper lip concavity, upper lip length, upper lip vermilion length, upper lip thickness, subnasal thickness, upper lip protrusion, upper lip anteroposterior position, lower lip anteroposterior position, and graft thickness (Tab. 2).

Method error

To determine the reliability of the cephalometric method, all 11 cephalometric radiographs from T_1 and T_2 were traced and measured twice, with a one-month interval, by the same investigator. Systematic errors were evaluated with the intraclass correlation coefficient (ICC). Excellent concordance between the two measurements at T_1 and T_2 was found (average: 0.903, range 0.639–0.974), resulting in no systematic errors.

Statistical analysis and power calculation

The preliminary assessment of data at T_1 , T_2 , and T_1-T_2 changes revealed the presence of both nonnormal distribution (Kolmogorov-Smirnov test) and no homogeneity of variances (Levene's test) for all the variables. T_1 and T_2 variables were compared with the Wilcoxon signed-rank test. Correlations between possible statistically significant differences at T_1 , T_2 and T_1-T_2 changes and the thickness of the graft (A-Grf) were verified with Spearman's Coefficient test. The significance level was set at $p < 0.05$. SPSS 17.0 for Windows (SPSS Inc., Chicago IL, USA) was used for the statistical analysis. The power of the study was based on the sample size available and measurements that present statistically significant differences.

RESULTS

The median, minimum, and maximum values of the cephalometric measurements are described in Table 3. Statistically significant differences between T_1 and T_2 angular and linear measurements were found for the nasolabial angle (Pn.Sn.UI) ($p = 0.03$) and the labial component of the nasolabial angle [(Sn-UI).Sn hor] ($p = 0.04$). The overall changes can be summarized by a representative superimposed cephalometric tracings before (T_1) and after (T_2) surgical treatment (Fig. 3).

The thickness of the graft (A-Grf) ranged from 4 to 7 mm. Correlation analysis was performed to determine whether there was a correlation between the thickness of the graft (A-Grf) and facial profile changes. The correla-

Table 3 - Descriptive statistics and p values for comparisons between T1 and T2.

Measurement	Time	Median	Q25-Q75	P value
Pn.Sn.Ul (degrees)	T1	111	109-123	0.03*
	T2	116	111.5-129	
(Pn-Sn).Sn hor (degrees)	T1	33	30.5-35	0.475
	T2	33.5	33-36.5	
(Sn-Ul).Sn hor (degrees)	T1	79	75-88	0.04*
	T2	82	78.5-88.5	
MUL-(Sn-Ul) (mm)	T1	-2	-3(-2)	0.618
	T2	-2	-3(-1.5)	
Sn-Ul (mm)	T1	17	16-20	0.75
	T2	19	15-21	
Ul-Sts (mm)	T1	10.5	9.5-11	0.38
	T2	10.5	9.5-11	
Crs-Ul (mm)	T1	15	14-17	0.326
	T2	14	12-17	
A-Sn (mm)	T1	16	14.5-17.5	0.55
	T2	16	14-19	
A-MUL (mm)	T1	16	14-17	0.392
	T2	15	14-17.5	
Gvert-Ul (mm)	T1	6.5	6-10	0.15
	T2	7	6-9	
Ul-(Pn-Pog') (mm)	T1	-3.5	-5(-1)	0.119
	T2	-2.5	-5.5(-1)	
Ll-(Pn-Pog') (mm)	T1	-2	-2.5-2	0.337
	T2	-0.5	-2-2	

* Statistical significant differences based on Wilcoxon's test (p < 0.05)

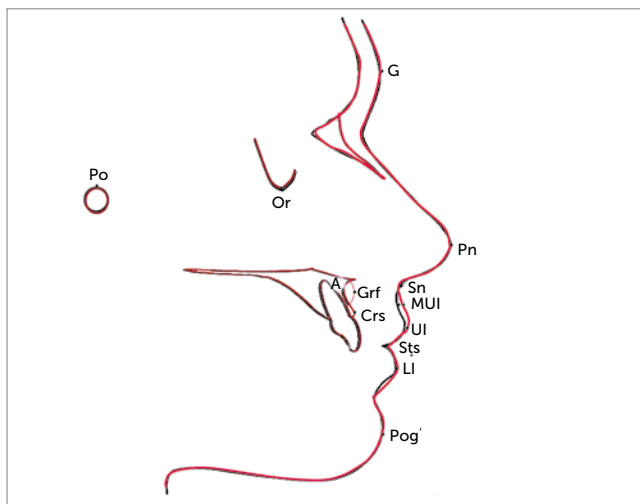


Figure 3 - Superimposed cephalometric tracing before (T1, black) and after (T2, red) treatment (superimposed on the Sella-Nasion line centered on Sella).

Table 4 - Correlation tests between A-Grf and measurements that were statistical significant.

Correlation tested	Spearman's rho (r)	P value
Pn.Sn.Ul (degrees) and A-Grf	-0.103	0.763
Dif Pn.Sn.Ul (degrees) and A-Grf	0.3	0.370
(Sn-Ul).Sn hor (degrees) and A-Grf	-0.185	0.586
Dif (Sn-Ul).Sn hor (degrees) and A-Grf	0.141	0.679

Dif is the difference between T1 and T2 (T1-T2) for the indicated measurement.

tion test was performed only for the measurements that were statistically significant. T_2 measurements were used when it was possible to obtain A-Grf, and differences between T_1 and T_2 ($T_1 - T_2$). Spearman's Coefficient test showed no statistically significant correlations (Tab. 4).

The calculation of the test power was based on the average and standard deviation of the nasolabial angle (Pn.Sn.Ul) and the labial component of the nasolabial angle [(Sn-Ul).Sn hor]. Considering an alpha level of 5%, the sample size ($n = 11$), and a clinically meaningful difference of 10 degrees to the nasolabial angle, and 8% for the labial component of the nasolabial angle, the power calculation was 0.83 and 0.87, respectively.²⁷

DISCUSSION

Many techniques have been developed for treating gingival smiles. However, there is a lack of studies related to cephalometric changes provided by these techniques. Therefore, this original study investigated the cephalometric changes that occurred due to the use of bone cement based on PMMA. The null hypothesis was rejected, since cephalometric alterations in the nasolabial angle and the labial component of the nasolabial angle were observed with the use of the bone cement based on PMMA. All patients who were available and met the inclusion criteria were evaluated. The power calculation indicated adequate power for statistical inferences.

A gingival smile is reported as being unattractive by dentists and lay people.⁴ It is primarily an aesthetic discomfort rather than a pathology, and treatment depends on the perception and willingness of the patient. A gingival smile is multifactorial and different approaches can be indicated based on its etiology.^{5,7} Hyperactivity of the upper lip can be identified by contraction of the elevator muscles of the upper lip, leaving it at 30% of its original height at rest.¹ This means 20% to 25% more muscular capacity to raise the upper lip than in subjects without a gingival smile.^{1,6} Some approaches have been recommended for this etiology, including upper lip repositioning,¹⁶⁻¹⁹ botulinum toxin injection,²⁰⁻²² and PMMA bone cement graft.²³⁻²⁵

The PMMA bone cement is marketed in Brazil and registered at the National Sanitary Surveillance Agency (ANVISA) valid until 2028. Its preliminary indication was intended for orthopedic medical surgeries. In the present study, a PMMA graft was proposed to fill the major subnasal depression observed in some patients with gingival smile. The graft was able to fill this de-

pression, resulting in reduced gingival display. It was hypothesized that this depression contributes to the lack of lip support and, when smiling, the lip tends to contract, shorten, and become lodged in this depression.²³⁻²⁵ Surgery with graft-based PMMA bone cement would probably interfere in the dynamics of the smile by limiting the retraction of elevator muscles.²³⁻²⁵ It is not clear how much of this reduction in gingival display may be due to the PMMA graft, since the graft has been associated with aesthetic crown lengthening.

However, it should be borne in mind that the technique has been shown to be effective in reducing the gingival smile. Clinical reports have demonstrated the stability and biocompatibility of the PMMA graft in the medium term (12, 18, and 22 months).²³⁻²⁵ But could the implantation of PMMA bone cement promote facial profile changes? There are no scientific studies to clarify these assumptions.

In Medicine, PMMA bone cement grafts have been used in cranioplasty, with high stability and a low complication rate.^{28,29} PMMA grafts are biocompatible,³⁰ very stable, and inert over time, and are considered a cost-effective and safe technique.^{28,29} In Dentistry, PMMA has also been used in the maxillofacial area for tumors, trauma, and TMJ ankylosis.³¹

The pioneering objective of this study was to evaluate the impact of PMMA bone cement grafts to manage the gingival smile in facial profile at rest, thereby enabling the understanding of some of the possible side effects of this intervention. The hypothesis that a PMMA graft was able to introduce cephalometric changes in facial profile was accepted.

The cephalometric results of this study demonstrated that the graft does not cause many significant changes in the facial profile. However, a small protrusion of the upper lip, promoting a slight increase of the nasolabial angle, without affecting the nasal component, was verified. It is important to highlight as a limitation of this study that the cephalometric method is a static and lateral evaluation. Frontal and functional evaluations still require investigation.

Cephalometric analysis has been conducted to evaluate facial changes due to other surgical procedures. Maxillary impaction changed the vertical and anteroposterior maxilla position, leading to nasal protraction, upper lip retraction due to retraction of the maxillary incisors, and soft tissue movement of the chin.³² Compared to maxillary impaction, a PMMA bone cement graft can

be advantageous, since it does not seem to induce major changes in facial physiognomy, and have a low risk of neurosensory deficit and bleeding, as described for orthognathic surgery.³³ However, the PMMA graft may not be the treatment of choice for resolving cases of gingival smile whose etiology is excessive vertical growth of the maxilla with greater severity.²³

Compared to other treatment options to manage hyperactivity of the upper lip, it is important to point out that the effect of PMMA graft is not temporary, as has been described for the approach with injection of botulinum toxin.²⁰⁻²² As regards upper lip repositioning, it is difficult to discuss and try to compare it with PMMA graft effects, because the approaches are very distinct.¹⁶⁻¹⁹

There was no correlation between the PMMA graft thickness and the facial profile changes. This may be explained by the small variability in the thickness of the grafts, which ranged from 4 to 7 mm. Even so, results of this study indicate a slight and long-term change in facial profile with PMMA bone cement. The PMMA graft added volume to the upper lip, projecting it forward. This facial profile change may be considered unpleasant for some patients, and therefore, this should be considered for the indication of the technique. Studies regarding patients' perceptions about the treatment of gingival smile with PMMA grafts and to clarify many other aspects involved in the technique are necessary.

Limitations








This was a retrospective study with the main sample selected from clinical files. The selection of the sample was possible due to the availability of records of cases treated by means of the surgical procedure under analysis. No control group was used due to ethical reasons, and the comparison was performed between before and after the surgical procedure. Statistical difference found only for the nasolabial angle may be due to the fact that the sample was too small and unable to reveal the actual results related to type II error. However, the high power obtained for this inference makes it reliable. The 2-D cephalometric measurements confirmed good reproducibility, and a 3-D evaluation was not the scope of this study. Moreover, the decision to submit these patients to higher X-ray exposures was not justified. The female sample limited the generalization of the data, however, there is no biological reason to find difference between the sexes.

CONCLUSIONS

» The PMMA bone cement graft to manage the hyperactive musculature during gingival smile projected the upper lip forward about 1mm, increasing the nasolabial angle without affecting the nasal component.

» No correlations between the implant thickness and the facial profile changes was detected.

Authors contribution (ORCID)

Érica M. de Torres (EMT): 0000-0002-5544-6865 
José Valladares-Neto (JVN): 0000-0003-0147-1931 
Karina O. Bernades (KOB): 0000-0001-6952-9592 
Luis Fernando Naldi (LFN): 0000-0002-4447-5177 
Hianne M. de Torres (HMT): 0000-0001-7214-2065 
Alexandre L. Carvalho (ALC): 0000-0002-9499-846X 
Carlos Estrela (CE): 0000-0002-1488-0366 

Conception or design of the study: EMT, CE. Data acquisition, analysis or interpretation: EMT, JVN, KOB, LFN, HMT, ALC, CE. Writing the article: EMT, JVN, KOB, HMT, ALC. Critical revision of the article: EMT, JVN, KOB, LFN, HMT, ALC, CE. Final approval of the article: EMT, JVN, KOB, LFN, HMT, ALC, CE.

REFERENCES

1. Miron H, Calderon S, Allon D. Upper lip changes and gingival exposure on smiling: Vertical dimension analysis. *Am J Orthod Dentofacial Orthop.* 2012 Jan;141(1):87-93.
2. Tarantili VV, Halazonetis DJ, Spyropoulos MN. The spontaneous smile in dynamic motion. *Am J Orthod Dentofacial Orthop.* 2005 July;128(1):8-15.
3. Narayan S, Narayan TV, Jacob PC. Correction of gummy smile: A report of two cases. *J Indian Soc Periodontol.* 2011 Oct;15(4):421-4.
4. Kokich VO Jr, Kiyak HA, Shapiro PA. Comparing the perception of dentists and lay people to altered dental esthetics. *J Esthet Dent.* 1999;11(6):311-24.
5. Garber DA, Salama MA. The aesthetic smile: diagnosis and treatment. *Periodontol 2000.* 1996 June;11:18-28.
6. Peck S, Peck L, Kataja M. The gingival smile line. *An Angle Orthod.* 1992 Summer;62(2):91-100; discussion 101-2.
7. Sildeberg N, Goldstein M, Smidt A. Excessive gingival display – etiology, diagnosis, and treatment modalities. *Quintessence Int.* 2009 Nov-Dec;40(10):809-18.
8. Seixá MR, Costa-Pinto RA, Araújo TM. Checklist dos aspectos estéticos a serem considerados no diagnóstico e tratamento do sorriso gengival. *Dental Press J Orthod.* 2011;16(2):131-57.
9. Ohnishi H, Yagi T, Yasuda Y, Takada K. A mini-implant for orthodontic anchorage in a deep overbite case. *Angle Orthod.* 2005 May;75(3):444-52.
10. Chu SJ, Karabin S, Mistry S. Short tooth syndrome: diagnosis, etiology and treatment management. *J Calif Dent Assoc.* 2004 Feb;32(2):143-52.
11. Dolt AH 3rd, Robbins JW. Altered passive eruption: an etiology of short clinical crowns. *Quintessence Int.* 1997 June;28(6):363-72.
12. Livada R, Shiloah J. Gummy smile: could it be genetic? Hereditary gingival fibromatosis. *J Mich Dent Assoc.* 2012 Dec;94(12):40-3.
13. Cairo F, Graziani F, Franchi L, Defraia E, Prato GPP. Periodontal plastic surgery to improve aesthetics in patients with altered passive eruption/gummy smile: a case series study. *Int J Dent.* 2012;2012:837658.
14. Kaku M, Kojima S, Sumi H, Koseki H, Abedini S, Motokawa M, et al. Gummy smile and facial profile correction using miniscrew anchorage. *Angle Orthod.* 2012 Jan;82(1):170-7.
15. Hong RK, Lim SM, Heo JM, Baek SH. Orthodontic treatment of gummy smile by maxillary total intrusion with a midpalatal absolute anchorage system. *Korean J Orthod.* 2013 June;43(3):147-58.
16. Gupta KK, Srivastava A, Singhal R, Srivastava R. An innovative cosmetic technique called lip repositioning. *J Indian Soc Periodontol.* 2010 Oct-Dec;14(4):266-9.
17. Rosenblatt A, Simon Z. Lip repositioning for reduction of excessive gingival display: a clinical report. *Int J Periodontics Restorative Dent.* 2006 Oct;26(5):433-7.
18. Humayun N, Kolhatkar S, Souiyas J, Bhola M. Mucosal coronally positioned flap for the management of excessive gingival display in the presence of hypermobility of the upper lip and vertical maxillary excess: a case report. *J Periodontol.* 2010 Dec;81(12):1858-63.
19. Rao AG, Koganti VP, Prabhakar AK, Soni S. Modified lip repositioning: A surgical approach to treat the gummy smile. *J Indian Soc Periodontol.* 2015 May-June;19(3):356-9.
20. Hwang WS, Hur MS, Hu KS, Song WC, Koh KS, Baik HS, et al. Surface anatomy of the lip elevator muscles for the treatment of gummy smile using botulinum toxin. *Angle Orthod.* 2009 Jan;79(1):70-7.
21. Indra AS, Biswas PP, Vineet V, Yeshaswini T. Botox as an adjunct to orthognathic surgery for a case of severe vertical maxillary excess. *J Maxillofac Oral Surg.* 2011 Sept;10(3):266-70.
22. Polo M. Botulinum toxin type A (Botox) for the neuromuscular correction of excessive gingival display on smiling (gummy smile). *Am J Orthod Dentofacial Orthop.* 2008 Feb;133(2):195-203.
23. Naldi LF, Adolphi D, Adolphi MC, Mendonça JAG, Leite AC, Oliveira RCG. Use of polymethylmethacrylate for esthetic crown lengthening, associated with lip repositioning: an original method. *TeamWork.* 2010;3:27-35.
24. Naldi LF, Ferreira GC, Borges GJ, Mendonça JAG, Carvalho AL, Oliveira RCG. Reposicionamento labial com cimento ortopédico associado a aumento estético de coroa clínica. *Clin Int J Braz Dent.* 2011;7(3):284-90.
25. Naldi LF, Borges GJ, Santos LFE, Andrade RS, Batista DG, Souza JB. Aesthetic crown lengthening combined with lip repositioned using bone cement. *Rev Odontol Bras Central.* 2012;21:493-97.
26. von Elm E, Altman DG, Egger M, Pocock SJ, Gøtzsche PC, Vandenbroucke JP. STROBE Initiative. The Strengthening the Reporting of Observational Studies in Epidemiology (STROBE) statement: guidelines for reporting observational studies. *Lancet.* 2007 Oct 20;370(9596):1453-7.
27. Lwanga SK, Lemeshow S. Sample size determination in health studies: a practical manual. Geneva: World Health Organization; 1991.
28. Marchac D, Greensmith A. Long-term experience with methylmethacrylate cranioplasty in craniofacial surgery. *J Plast Reconstr Aesthet Surg.* 2008 July;61(7):744-52.
29. Stieglitz LH, Gerber N, Schmid T, Mordasini P, Fichtner J, Fung C, et al. Intraoperative fabrication of patient-specific moulded implants for skull reconstruction: single-centre experience of 28 cases. *Acta Neurochir (Wien).* 2014 Apr;156(4):793-803.
30. Carlsson E, Mestres G, Treeratrakoon K, López A, Karlsson Ott M, Larsson S. In vitro and in vivo response to low-modulus PMMA-based bone cement. *Biomed Res Int.* 2015;2015:594284.
31. Smeets R, Marx R, Kolk A, Said-Yekta S, Grosjean MB, Stoll C, et al. In vitro study of adhesive polymethylmethacrylate bone cement bonding to cortical bone in maxillofacial surgery. *J Oral Maxillofac Surg.* 2010 Dec;68(12):3028-33.
32. Aydiil B, Ozer N, Marsan G. Facial soft tissues changes after maxillary impaction and mandibular advancement in high Angle Class II cases. *Int J Med Sci.* 2012;9(4):316-21.
33. Kim SG, Park SS. Incidence of complications and problems related to orthognathic surgery. *J Oral Maxillofac Surg.* 2001 Oct;59(10):1128-36; discussion 1137