

# Interdisciplinary treatment of an avulsed permanent tooth in patient with incomplete facial growth

Heloísa Helena Pinho **VELOSO**<sup>1</sup>

Felipe Cavalcanti **SAMPAIO**<sup>2</sup>

Orlando Aguirre **GUEDES**<sup>3</sup>

## ABSTRACT

**Introduction:** The rehabilitation of patients with dental avulsion history could be complex and difficult to choose. The possibility of rehabilitation with dental implants may be considered when choosing the replantation, due to the possibility of bone tissue maintenance, especially in patients with incomplete facial growth. **Objective:** The purpose of this paper is to report a dental avulsion case treated by late tooth replantation, aiming at bone level maintenance for further rehabilitation with dental implant. **Case Report:** Male patient, 11 years old, suffered dental trauma during sports practice, resulting in tooth #21 avulsion. The tooth was found after 24 hours. The therapeutic choice was tooth replantation, although the conditions were adverse due to extraoral time (60 hours) and storage medium (dry). The tooth

was cleaned, immersed in calcitonin for 15 minutes, and endodontically treated before replantation. Then, a semi-rigid splint was used for 10 days. One year after the replantation a replacement root resorption was radiographically diagnosed. After 7-year follow-up, the root was almost completely reabsorbed, with sufficient bone tissue for insertion of dental implant. The tooth remnant was removed and an immediate dental implant was performed. After 6 months, a ceramic-ceramic crown was confected. **Conclusion:** Thus, the importance of avulsed tooth replantation is clear in the maintenance of bone tissue level for dental implant placement and, consequently, reestablishment of function, as of esthetic and phonetic.

**Keywords:** Dental trauma. Tooth avulsion. Tooth replantation. Root resorption. Dental implant.

**How to cite this article:** Veloso HHP, Sampaio FC, Guedes OA. Interdisciplinary treatment of an avulsed permanent tooth in patient with incomplete facial growth. Dental Press Endod. 2011 Oct-Dec;1(3):65-70.

» The authors report no commercial, proprietary, or financial interest in the products or companies described in this article.

<sup>1</sup>Professor of Restorative Dentistry, Department of Restorative Dentistry, Federal University of Paraíba, João Pessoa, Brazil.

<sup>2</sup>Graduate Student (Master's degree), Department of Dentistry, Federal University of Goiás, Goiânia, Brazil.

<sup>3</sup>Graduate Student (Doctorate), Department of Health Sciences, Federal University of Goiás, Goiânia, Brazil.

Received: 28/11/2011 / Accepted: 30/11/2011.

Contact address: Felipe Cavalcanti Sampaio  
Décima Primeira Avenida 334, Qd. 103, Lt. 15, Ap. 208, Setor Leste Universitário  
CEP: 74.605-060 – Goiânia / GO – Brazil  
E-mail: felipecavalcantisampaio@yahoo.com

## Introduction

Traumatic dental injuries represents 5% of all head and neck traumatic injuries<sup>1</sup> and have become one of the most serious public health problem.<sup>2</sup> Among these injuries, dental avulsion is one of the few real emergency situations in dentistry and represents the most serious dental trauma,<sup>3</sup> which prevalence varies from 3,8% to 18,3%, and it is more usual in young adults and children.<sup>2,4-12</sup> The first choice treatment is the tooth replantation, the most conservative approach for this type of trauma, allowing esthetic and function preservation and avoiding the need of prosthetic rehabilitation.<sup>3</sup>

Among the factors which might affect the replantation prognosis are: Trauma extension, extraoral time, storage media, contamination and the avulsed tooth condition. These can result in periodontal inflammation, root resorption and ankylosis.<sup>13-16</sup>

The time elapsed until the replantation, essential factor for treatment success, depends on the knowledge level of the victim, family or school teachers. However, the population majority does not know the immediate conducts post-trauma.<sup>17-20</sup> The outcome is better when the replantation is performed less than 20 minutes after avulsion. As elapsed time increases, periodontal ligament cells mortify and success rate decreases substantially. Extraoral period higher than 60 minutes promotes, in most cases, extensive root resorption, which could lead to tooth loss.<sup>3,16,21,22</sup>

An alternative treatment for tooth loss due to root resorption is the dental implant. After implantology advent, bone maintenance began to receive significant attention.<sup>21</sup> However, in some situations the jaws do not have bone quantity, height or volume sufficient for settling an implant. Moreover, most of dental avulsion cases happens in young subjects, before the facial growth is complete.<sup>21</sup>

The present study aims to report a case of dental avulsion, treated by late replantation, aiming the bone level maintenance for posterior rehabilitation by dental implant.

## Case Report

Male patient, 11 year-old attended dental care due to avulsion of the tooth 21. The trauma was caused by collision in an iron bar during sports practicing. The time elapsed between the trauma and the emergency appointment amounted approximately 60 hours, the tooth being kept in a napkin until the time of the treatment.

The dental replantation was the therapeutic chosen option, even with unfavorable conditions, like prolonged extraoral period and inadequate storage media. Another observed factor was the patient's craniofacial growth and development phase.

The treatment planning followed the guidelines proposed by the International Association of Dental Traumatology (IADT) for dental avulsion management.<sup>3</sup>

During the first appointment, the clinical exam showed the tooth socket healing process with a firm consistency clot. The tooth was submitted to a cleaning process with gauze and saline. Then, the tooth was kept in a calcitonin solution (Miacalcic®, Taboão da Serra, Brazil) for 15 minutes. This medication is used for treating osteoporosis, in order to reduce bone resorption, and in this case it was used to inhibit root resorption for as much time as possible.

Endodontic treatment was performed soon after the root cleaning. As a result of the prolonged extraoral time, pulp tissue necrosis was expected, preventing revascularization and regeneration. Moreover, the time addition necessary for the endodontic treatment would not interfere in the replantation outcome, as it was expected root resorption for the unfavorable conditions of the case.

The root canal was accessed using diamond burs 1012 and 1013 (KG Sorensen, Cotia, Brazil) and instrumented using a crown-down technique. The root canal cervical third was enlarged using a LA Axxess #2 drill (SybronEndo, Orange, CA, USA). The tooth was prepared up to a file size #55 (Dentsply Maillefer, Ballaigues, Switzerland), 1 mm short of the apical foramen. The root canal was irrigated with 3 mL of 1.0% sodium hypochlorite at each change of file. The root canal filling was performed using gutta-percha (Dentsply) associated to Sealapex (SybronEndo) as sealer, by the lateral condensation technique. The quality of canal filling was confirmed radiographically. The tooth was immediately restored with composite (3M ESPE, Irvine, CA, USA).

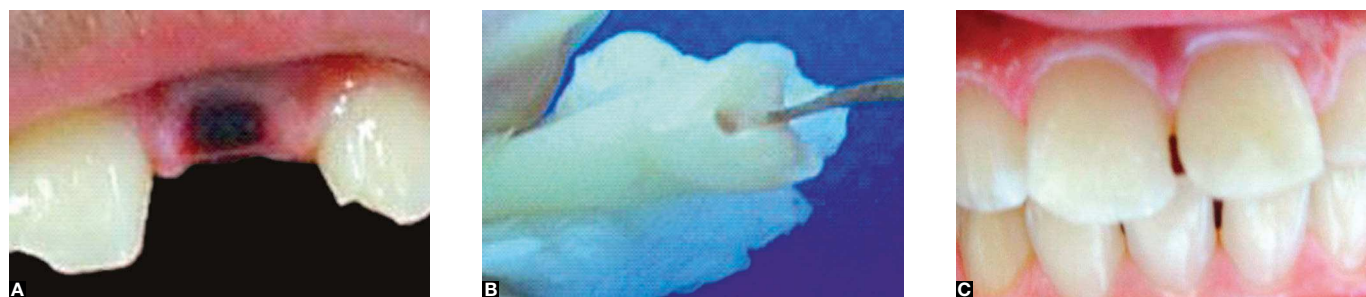
After the endodontic treatment, the clot was removed from the socket with saline, for posterior tooth repositioning. A flexible splint was performed on the replanted tooth with composite (3M ESPE) and nylon wire, which remained for 10 days. A tetanus vaccine intensification was recommended and a systemic antibiotics therapy was prescribed (amoxicillin 500 mg, 8-8 hours for 7 days), associated to an anti-inflammatory (nimesulide 100 mg, 12/12 hours for 3 days).

Follow-up was realized by clinical and radiographic attendance at weekly intervals in the first month and every 3 months.

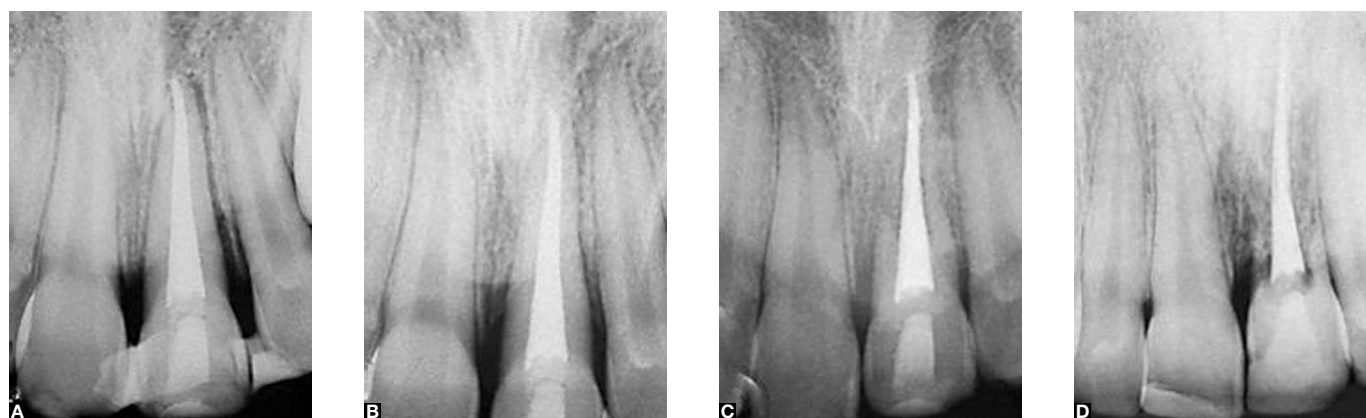
After 1 year follow-up, ankylosis and replacement root resorption was diagnosed. As this was expected, the resorption was followed-up while root tissue was gradually replaced for new bone tissue. Seven years after the replantation, the root resorption reached almost the entire root. The bone level

at the #21 tooth site was near the adjacent tooth bone level. At this moment it was decided to perform the dental implant rehabilitation.

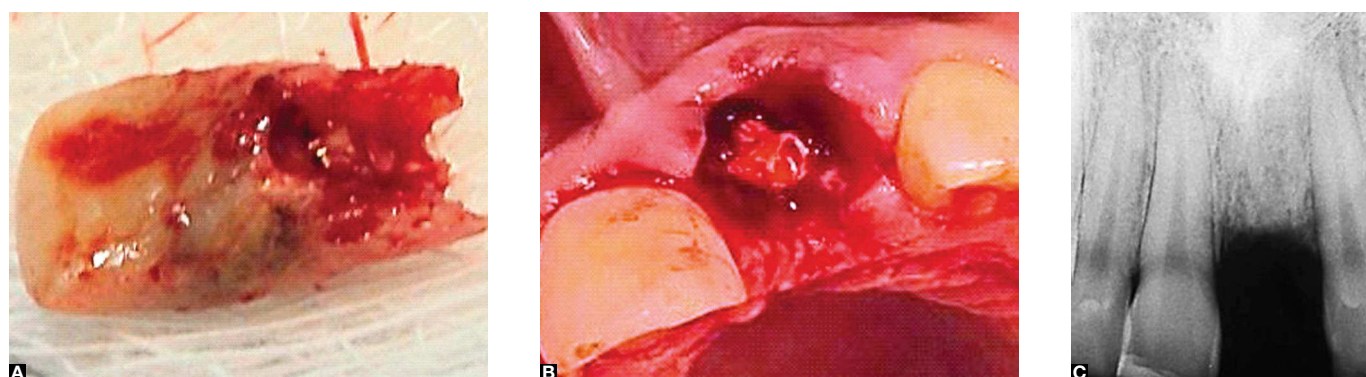
The tooth extraction was performed (Fig 3) and, at the same appointment, carried out the 3.75 mm diameter and 13 mm length (Osseotite®, BIOMET 3i, Palm Beach Gardens, FL, USA) implant placement (Fig 4 A, C). During surgical procedure primary stability was achieved, although the bone was Type III. A provisional



**Figure 1.** A) Tooth 21 avulsion. B) Endodontic treatment. C) Clinical aspect after tooth replantation.

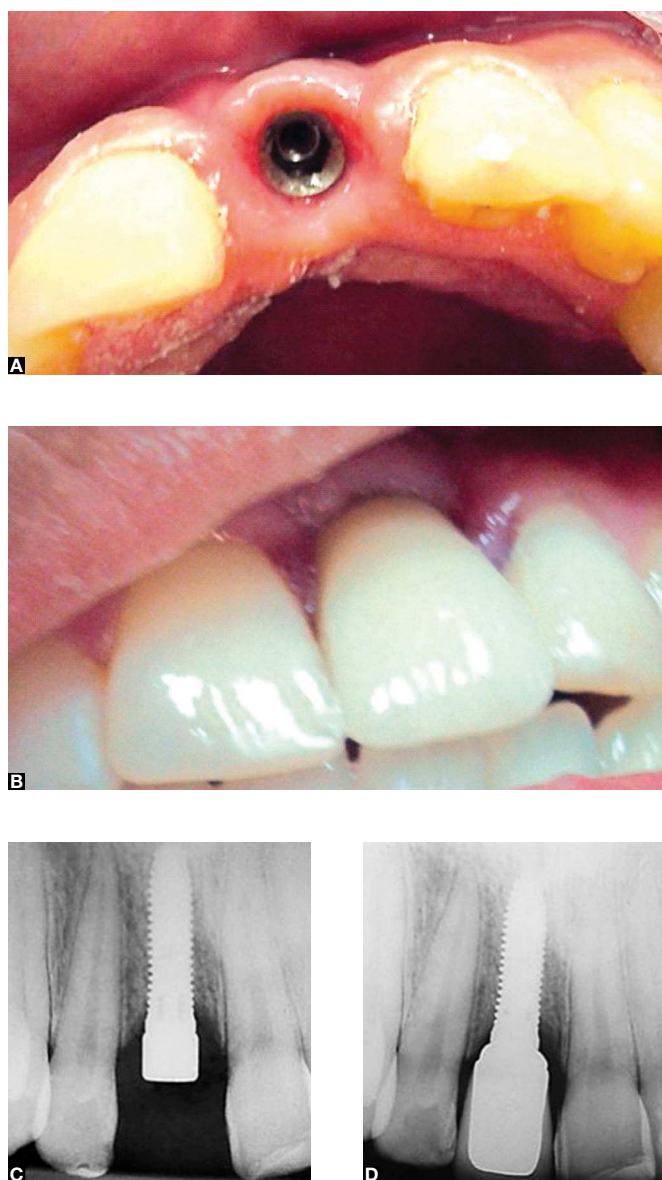


**Figure 2.** A) Radiographic aspect immediately after replantation. B) The beginning of replacement resorption after 1 year. C) Follow-up after 5 years. D) Follow-up after 7 years: complete root resorption.



**Figure 3.** A) Tooth remnant. B) Clinical aspect after extraction. C) Radiographic aspect after extraction.





**Figure 4.** A) Clinical aspect after dental implant placement. B) Clinical aspect after crown installation. C) Radiographic aspect after dental implant placement. D) Radiographic aspect after crown installation.

adhesive crown was made to maintain the esthetical aspects while the osseointegration was expected.

Six months after osseointegration confirmed radiographically, a ceramic-ceramic crown was manufactured. At the end, esthetic and functional satisfactory results were achieved, without any bone involvement or need of bone graft.

## Discussion

The increase of violence, traffic accidents and sports practicing contributed to turn dental trauma in an emergent public health problem.<sup>2,23,24</sup> Dental avulsion represents from 4% to 18%, approximately, of the permanent dentition traumatic injuries,<sup>2,4-12</sup> being responsible for an expressive number of teeth losses due to complications, as, for example, root resorption.

The treatment for dental avulsion should be the replantation. Even if local or systemic conditions are not favorable, the replantation must be done, as the maintenance of the tooth in function for some years may be considered a success.<sup>3,21,22</sup>

After replantation, the tooth should be followed-up in short periods in order to diagnose possible complications.<sup>3,21,22</sup> The replacement resorption gradually replaces the dental root for bone tissue, and should be followed-up for a period of 5 years.<sup>3,21</sup> In the case reported, the tooth was followed-up weekly in the first month and every 3 months until the root resorption was almost complete.

Formation of bone imperfections is usual as a consequence of dental trauma. In dental avulsion, the non-replantation may cause alveolar bone loss, both in width and height.<sup>21</sup> Thus, dental implant rehabilitation could be compromised, for which bone grafts would be necessary.

The treatment proposed for the case reported aimed, while maintaining the tooth the longest possible in function, to avoid bone tissue loss, which would demand bone grafts for posterior dental implants placement.

The evolution of late replanted teeth for replacement root resorption is usual. This type of resorption is favorable, since there is formation of bone tissue, specially maintaining the bone height.<sup>3,21,22,25</sup> This condition is essential for dental implant rehabilitation without the need of bone grafts. Replacement root resorption should be followed-up until there is sufficient bone tissue for implant placement.<sup>3,21,22</sup>

Another possible complication after replantation is inflammatory root resorption, which have worse outcome related to replacement resorption. The chance of inflammatory resorption occurrence could be minimized by the previous necrotic tissue removal and endodontic treatment.<sup>3,21,26</sup> In the case reported, root canal filling was performed previously to the replantation. This procedure did not affect the outcome of the

replantation, since the extraoral time was already pronounced, and in addition, it would minimize the chance of inflammatory resorption. This procedure is recommended by the guidelines proposed by the IADT.<sup>3</sup>

As most dental avulsion cases occur in young subjects, before facial growth is complete, the tooth maintenance is essential. In addition, even being the condition aimed, tooth replantation success does not require a healthy tooth in function for the entire life of the patient. The therapeutic modality which maintains the teeth for a few years and allows the complete facial growth and development should be considered a success.<sup>21</sup>

In the case reported, the periodontal ligament regeneration was not expected, as the extensive extraoral period and the absence of storage media caused necrosis of the periodontal ligament cells. The key for the replantation was the tooth disinfection.<sup>3,21</sup> Contamination in the root canal would hasten the resorption process, which could constitute a further complication factor, once the patient was still in facial growth and development phase.

The importance of the avulsed teeth maintenance for the most time possible in patients in facial growth phase is

for the impossibility of dental implants placement. These act as ankylosed teeth, without eruptive potential, causing occlusal discrepancy. Several studies showed position changes of dental implants and interference in the jaws development next to implant sites when these were placed in incomplete facial growth subjects.<sup>27-34</sup>

The tooth replantation, in the case reported, allowed bone level maintenance both in height and width for the dental implant rehabilitation without bone grafts. This maintenance was essential for esthetics, as possible bone defects, especially in the anterior maxillary wall, would cause esthetic loss. Furthermore, it kept the tooth in function for 7 years, which should be considered a success for a late replantation.<sup>21</sup>

## Conclusion

Dental avulsion cases, in incomplete facial growth patients, should be treated by the tooth replantation, even when conditions are not favorable. This treatment enables bone level maintenance without defects formation, allowing the stomatognathic system prosthetic rehabilitation. Thus, this treatment grants function, esthetic and phonetic re-establishment.

## References

- Petersson EE, Andersson L, Sorensen S. Traumatic oral vs non-oral injuries. *Swed Dent J*. 1997;21(1-2):55-68.
- Marcenes W, al Beiruti N, Tayfour D, Issa S. Epidemiology of traumatic injuries to the permanent incisors of 9-12-year-old schoolchildren in Damascus, Syria. *Endod Dent Traumatol* 1999;15(3):117-23.
- Flores MT, Andersson L, Andreassen JO, Bakland LK, Malmgren B, Barnett F, et al. Guidelines for the management of traumatic dental injuries. II. Avulsion of permanent teeth. *Dent Traumatol*. 2007;23(3):130-6.
- Guedes OA, de Alencar AH, Lopes LG, Pecora JD, Estrela C. A retrospective study of traumatic dental injuries in a Brazilian dental urgency service. *Braz Dent J*. 2010;21(2):153-7.
- Tzigkounakis V, Merglová V, Hecová H, Netolický J. Retrospective clinical study of 90 avulsed permanent teeth in 58 children. *Dent Traumatol*. 2008;24(6):598-602.
- Gong Y, Xue L, Wang N, Wu C. Emergency dental injuries presented at the Beijing Stomatological Hospital in China. *Dent Traumatol*. 2011;27(3):203-7.
- Taiwo OO, Jalo HP. Dental injuries in 12-year old Nigerian students. *Dent Traumatol*. 2011;27(3):230-4.
- Chan YM, Williams S, Davidson LE, Drummond BK. Orofacial and dental trauma of young children in Dunedin, New Zealand. *Dent Traumatol*. 2011;27(3):199-202.
- Hecova H, Tzigkounakis V, Merglova V, Netolicky J. A retrospective study of 889 injured permanent teeth. *Dent Traumatol* 2010;26(6):466-75.
- Hasan AA, Qudeimat MA, Andersson L. Prevalence of traumatic dental injuries in preschool children in Kuwait - a screening study. *Dent Traumatol*. 2010;26(4):346-50.
- Díaz JA, Bustos L, Brandt AC, Fernández BE. Dental injuries among children and adolescents aged 1-15 years attending to public hospital in Temuco, Chile. *Dent Traumatol* 2010;26(3):254-61.
- Jesus MA, Antunes LA, Risso P de A, Freire MV, Maia LC. Epidemiologic survey of traumatic dental injuries in children seen at the Federal University of Rio de Janeiro, Brazil. *Braz Oral Res*. 2010;24(1):89-94.
- Andreassen JO. Effect of extra-alveolar period and storage media upon periodontal and pulpal healing after replantation of mature permanent incisors in monkeys. *Int J Oral Surg*. 1981;10(1):43-53.
- Soder PO, Otteskog P, Andreassen JO, Modeer T. Effect of drying on viability of periodontal membrane. *Scand J Dent Res*. 1977;85(3):164-8.
- Petrovic B, Markovic D, Peric T, Blagojevic D. Factors related to treatment and outcomes of avulsed teeth. *Dent Traumatol*. 2010;26(1):52-9.
- Soares A de J, Gomes BP, Zaia AA, Ferraz CC, de Souza-Filho FJ. Relationship between clinical-radiographic evaluation and outcome of teeth replantation. *Dent Traumatol*. 2008;24(2):183-8.
- Al-Obaida M. Knowledge and management of traumatic dental injuries in a group of Saudi primary schools teachers. *Dent Traumatol* 2010;26(4):338-41.
- Skeie MS, Audestad E, Bardsen A. Traumatic dental injuries: knowledge and awareness among present and prospective teachers in selected urban and rural areas of Norway. *Dent Traumatol*. 2010;26(3):243-7.
- Vergotine RJ, Govoni R. Public school educator's knowledge of initial management of dental trauma. *Dent Traumatol*. 2010;26(2):133-6.
- Qazi SR, Nasir KS. First-aid knowledge about tooth avulsion among dentists, doctors and lay people. *Dent Traumatol*. 2009;25(3):295-9.
- Trope M. Avulsion of permanent teeth: theory to practice. *Dent Traumatol*. 2011;27(4):281-94.
- Savi A, Turillazzi O, Cocconi R, Bonanini M, Pizzi S, Manfredi M. Central incisor loss after delayed replantation following avulsion: a contemporary restorative and adjunctive orthodontic management approach. *Dent Traumatol*. 2011 Jul 14. Epub ahead of print.
- Gassner R, Bosch R, Tuli T, Emshoff R. Prevalence of dental trauma in 6,000 patients with facial injuries: implications for prevention. *Oral Surg Oral Med Oral Pathol Oral Radiol Endod*; 1999;87(1):27-33.
- Soriano EP, Caldas A de F Jr, Carvalho MV, Caldas KU. Relationship between traumatic dental injuries and obesity in Brazilian schoolchildren. *Dent Traumatol*. 2009;25(5):506-9.
- Trope M. Avulsion and replantation. *Refuat Hapeh Vehashinayim*. 2002;19(2):6-15, 76.
- Emerich K, Czerwinska M, Ordyniec-Kwasnica I. Immediate self-replantation of an avulsed permanent mandibular incisor: a case report. *Dent Traumatol*. 2010;26(5):443-6.
- Odman J, Grondahl K, Lekholm U, Thilander B. The effect of osseointegrated implants on the dento-alveolar development. A clinical and radiographic study in growing pigs. *Eur J Orthod*. 1991;13(4):279-86.
- Sennerby L, Odman J, Lekholm U, Thilander B. Tissue reactions towards titanium implants inserted in growing jaws. A histological study in the pig. *Clin Oral Implants Res*. 1993;4(2):65-75.
- Thilander B, Odman J, Grondahl K, Lekholm U. Aspects on osseointegrated implants inserted in growing jaws. A biometric and radiographic study in the young pig. *Eur J Orthod* 1992;14(2):99-109.
- Thilander B, Odman J, Lekholm U. Orthodontic aspects of the use of oral implants in adolescents: a 10-year follow-up study. *Eur J Orthod*. 2001;23(6):715-31.
- Thilander B, Odman J, Grondahl K, Friberg B. Osseointegrated implants in adolescents. An alternative in replacing missing teeth? *Eur J Orthod*. 1994;16(2):84-95.
- Thilander B, Odman J, Jemt T. Single implants in the upper incisor region and their relationship to the adjacent teeth. An 8-year follow-up study. *Clin Oral Implants Res*. 1999;10(5):346-55.
- Bernard JP, Schatz JP, Christou P, Belser U, Kiliaridis S. Long-term vertical changes of the anterior maxillary teeth adjacent to single implants in young and mature adults. A retrospective study. *J Clin Periodontol*. 2004;31(11):1024-8.
- Schropp L, Wenzel A, Kostopoulos L, Karring T. Bone healing and soft tissue contour changes following single-tooth extraction: a clinical and radiographic 12-month prospective study. *Int J Periodontics Restorative Dent*. 2003;23(4):313-23.