

# Evaluation of silver nanoparticles as irrigating solution

João Eduardo **GOMES-FILHO**<sup>1</sup>  
 Fernando **OLIVEIRA SILVA**<sup>2</sup>  
 Simone **WATANABE**<sup>3</sup>  
 Karina Vanessa **TENDORO**<sup>2</sup>  
 Luana Godoy **DALTO**<sup>2</sup>  
 Sara Vieira **PACANARO**<sup>2</sup>  
 Carolina Simonetti **LODI**<sup>4</sup>  
 Fernanda Fragoço Ferreira de **MELO**<sup>5</sup>  
 Elói **DEZAN JÚNIOR**<sup>6</sup>  
 Luciano Tavares Angelo **CINTRA**<sup>2</sup>

## ABSTRACT

**Introduction:** Irrigation is an important procedure during root canal treatment once it can help cleaning those areas of the root canal system not directly reached by instruments **Objective:** The aim of this study was to evaluate the biocompatibility and disinfection ability of silver nanoparticles dispersion in comparison to 2.5% sodium hypochlorite. **Methods:** Thirty two rats individually received 4 infected and uninfected dentin tubes irrigated with 47 ppm and 23 ppm silver nanoparticles dispersion, 2.5% sodium hypochlorite, and saline solution. Sixteen rats received one infected and one uninfected dentin tube, as the control group. After 7 and 30 days, all the animals were killed, the tubes and surrounding

tissues were removed, and prepared to be analyzed in light microscope. Qualitative and quantitative assessments of the reactions were carried out. **Results:** All solutions in uninfected tubes caused mild reactions after 30 days. All solutions in infected tubes caused severe reactions after 7 days and mild reactions after 30 days. The outcomes were similar to those of the uninfected control group, but better than those of the infected control group. **Conclusions:** It was possible to conclude that silver nanoparticles dispersion was biocompatible and may act as disinfectant in contaminated tubes, especially at 23 ppm.

**Keywords:** Endodontics. Biocompatibility. Connective tissue biology.

**How to cite this article:** Gomes-Filho JE, Silva FO, Watanabe S, Tendoro KV, Dalto LG, Pacanaro SV, Lodi CS, Melo FFF, Dezan Júnior E, Cintra LTA. Evaluation of silver nanoparticles as irrigating solution. *Dental Press Endod.* 2013 May-Aug;3(2):16-23.

<sup>1</sup>Postdoc in Endodontics, State University of São Paulo (UNESP).

<sup>2</sup>Doctorate student in Dental Science, UNESP.

<sup>3</sup>Graduated in Dentistry, UNESP.

<sup>4</sup>Full professor of Endodontics, UNESP.

<sup>5</sup>Postdoc in Endodontics, State University of Maringá (UEM).

» The authors report no commercial, proprietary or financial interest in the products or companies described in this article.

Received: March 25, 2013. Accepted: May 4, 2013.

Contact address: João Eduardo Gomes-Filho  
 Faculdade de Odontologia de Araçatuba, Universidade Estadual Paulista  
 Rua José Bonifácio, 1193 – Araçatuba/SP – Brazil– CEP: 16015-050  
 E-mail: joao@foa.unesp.br

## Introduction

Irrigation is an important procedure during root canal treatment, once it helps with cleaning those areas of the root canal system not directly reached by instruments.<sup>1</sup> Teeth with incomplete root formation present large root canals, with thin and fragile walls. These features hinder instrumentation of the canal. In such cases, in order to allow pulp regeneration, treatment of immature teeth in an attempt to revascularize the pulp has been considered. The treatment consists of irrigation and disinfection carried out with antimicrobial agents achieving successful revascularization.<sup>2</sup> In other studies, the protocol differs from other apexification techniques in which disinfection of the canal is performed with both sodium hypochlorite (NaOCl) and chlorhexidine (CHX), using a combination of antibiotics such as ciprofloxacin, metronidazole and minocycline,<sup>4</sup> achieving successful revascularization.<sup>3,4</sup> Sodium hypochlorite (NaOCl), chlorhexidine gluconate and saline solution are routinely used as irrigants.<sup>5,6,7</sup> Several studies have compared their antimicrobial effects, chemical properties and biocompatibility in order to establish an ideal solution that can be used during root canal treatment.<sup>5,6</sup>

Nanomaterials have been used to create new consumer products as well as applications for life sciences and biotechnology due to their physical and chemical properties.<sup>8</sup> Chemically, the nanoparticles (NPs) are very diverse. Silver nanoparticles (Ag NPs) are widely used in electronics<sup>9,10</sup> optical devices,<sup>10,11</sup> catalysis,<sup>10,12</sup> and antimicrobial agents.<sup>10,13</sup> Monovalent silver compounds, especially silver nitrate, have been extensively used for antimicrobial treatment. These antimicrobial properties are retained in Ag NPs and exploited in nanofiber mats, bandages, wound dressings and ointments. In addition, Ag NPs have been used to prevent bacterial colonization on various surfaces such as catheters, prosthesis and clothing.<sup>14</sup> However, silver should be used with caution, since its toxicity depends on its concentration.<sup>14</sup> On the other hand, it has been recently observed that silver nanoparticles dispersion was biocompatible, especially at a lower concentration.<sup>8</sup>

Considering that there are few studies in the literature assessing the use of Ag NPs in steps of root canal treatment, especially as irrigating solution, the aim of this study was to evaluate the biocompatibility

and disinfection ability of Ag NPs dispersion in comparison to 2.5% sodium hypochlorite using a rat subcutaneous tissue as model.

## Material and Methods

Forty-eight male 4- to 6-month-old Wistar albino rats, weighing 250–280g, were used. The animals were housed in temperature-controlled rooms and received water and food *ad libitum*. The care of the animals was performed according to the College of Dentistry — Araçatuba (UNESP) Institutional Review Board which approved the project before the experiments began.

One hundred and sixty dentin tubes were prepared using bovine teeth roots. This technique was adapted from the preparation of dentin tubes with human teeth.<sup>15</sup> The root canals were enlarged to K-file #35 and overinstrumented 2 mm beyond the apical foramen. The canals were thoroughly irrigated with 2.5% sodium hypochlorite during instrumentation. Endo-Z bur (Maillefer Dentsply, Tulsa, OK) was used to shape the dentin wall thickness to about 0.5 mm. At the end of the manufacturing process, the length of the tubes was standardized to 7 mm. Smear layer was removed with 17% EDTA and 5.25% NaOCl under ultrasonic vibration and saline solution was used as final irrigant. The dentin tubes were autoclaved for 30 min at 134°C.<sup>15</sup>

Human saliva was used to infect half of the tubes. Human saliva was collected (3 mL) and distributed into 3 vials containing 4 mL of Brain Heart Infusion broth (BHI; Himedia, Mumbai, India) and stored for 48h at 37°C. Under laminar flow, the tubes were aseptically and individually set in a 24-well plate (Corning, NY, USA) using alcohol decontaminated wax and filled with contaminated BHI. The plates were stored for 7 days at 37°C in order to allow dentin tube contamination. Every day, 0.1 mL of contaminated BHI was used to refill the tubes. Two extra tubes were used to check the contamination. The remaining tubes were not contaminated and also aseptically set in a 24-well plate.

Sixty four uninfected tubes and sixty four infected tubes were irrigated with 5 mL of 47 ppm Ag NPs dispersion, 23 ppm Ag Nps dispersion (Khemia Equipamentos Tecnológicos de Efluentes Ltda, São Paulo, São Paulo, Brazil), 2.5% sodium hypochlorite

(Apoticário, Araçatuba, São Paulo, Brazil) and saline solution (16 tubes/treatment). Sixteen extra uninfected tubes and sixteen extra infected tubes were not irrigated with any solution and were used as control.

Four pockets were created in thirty two animals according to methods previously published.<sup>15</sup> Half of the animals received four uninfected tubes and the remaining animals received four infected tubes (one tube for each treatment solution). For the controls, in sixteen remaining animals, only two pockets were created to receive untreated tubes (uninfected/ infected).

After 7 and 30 days, the animals were euthanized by overdose of anesthetic solution, and the tubes with surrounding tissues were removed, fixed, decalcified and processed using glycol methacrylate and hematoxylin-eosin stain.<sup>16,17,18</sup>

Reactions in the tissue in contact with the material on the opening of the tube were scored according to previous studies, with 0 being none or few inflammatory cells and no reaction; 1, less than 25 cells and mild reaction; 2, between 25 and 125 cells and moderate reaction; and 3, 125 or more cells and severe reaction. Fibrous capsules were considered to be thin when thickness was <150  $\mu$ m and thick at >150  $\mu$ m.<sup>17-20</sup> An average of the number of cells for each group was obtained from 10 separate areas. Results were statistically analyzed using the Kruskal-Wallis test.

## Results

### Uninfected dentin tubes

Similar histologic characteristics were found after the implantation of uninfected tubes, regardless of the treatment, including the control. After 7 days, a moderate inflammatory cell infiltration with chronic inflammatory cells consisting of lymphocytes, macrophages, and fibroblasts was present in the thin fibrous capsule. The inflammatory reaction decreased and the tissue was more organized with the predominance of fibroblasts and connective fibers on the 30<sup>th</sup> day (Fig 1).

### Infected dentin tubes

#### Ag NPs dispersion (23 ppm)

After 7 days, a severe inflammatory cell infiltration consisting of neutrophils, lymphocytes and macrophages was present in the fibrous capsule (Figs 2A and 2B). The intensity of the inflammation was reduced to mild on the 30<sup>th</sup> day consisting only by

chronic cells and the fibrous capsule near the tube was thin (Figs 2C and Fig 2D).

#### Ag NPs dispersion (47 ppm)

On the 7<sup>th</sup> day, a severe inflammatory cell infiltration consisting of neutrophils, lymphocytes and macrophages was present in the fibrous capsule similar to that observed with the 23 ppm Ag NPs (Figs 2E and 2F). The intensity of the inflammation was reduced to mild on the 30<sup>th</sup> day when it consisted only of chronic cells and the fibrous capsule near the tube was thin and well organized (Figs 2G and 2H).

#### Sodium hypochlorite (2.5%)

On the 7<sup>th</sup> day, a severe inflammatory cell infiltration consisting of neutrophils, lymphocytes and macrophages was present in the disorganized fibrous capsule (Figs 2I and 2J). The intensity of the inflammation was reduced to mild on the 30<sup>th</sup> day, consisting only of chronic cells in a thin fibrous capsule (Figs 2K and 2L).

#### Saline solution

On the 7<sup>th</sup> day, a severe inflammatory cell infiltration consisting of neutrophils, lymphocytes and macrophages was present in the disorganized fibrous capsule (Figs 2M and 2N). The intensity of the inflammation was reduced to mild on the 30<sup>th</sup> day, consisting only of chronic cells in a thin but partially disorganized fibrous capsule (Figs 2O and 2P).

### Control (empty tubes)

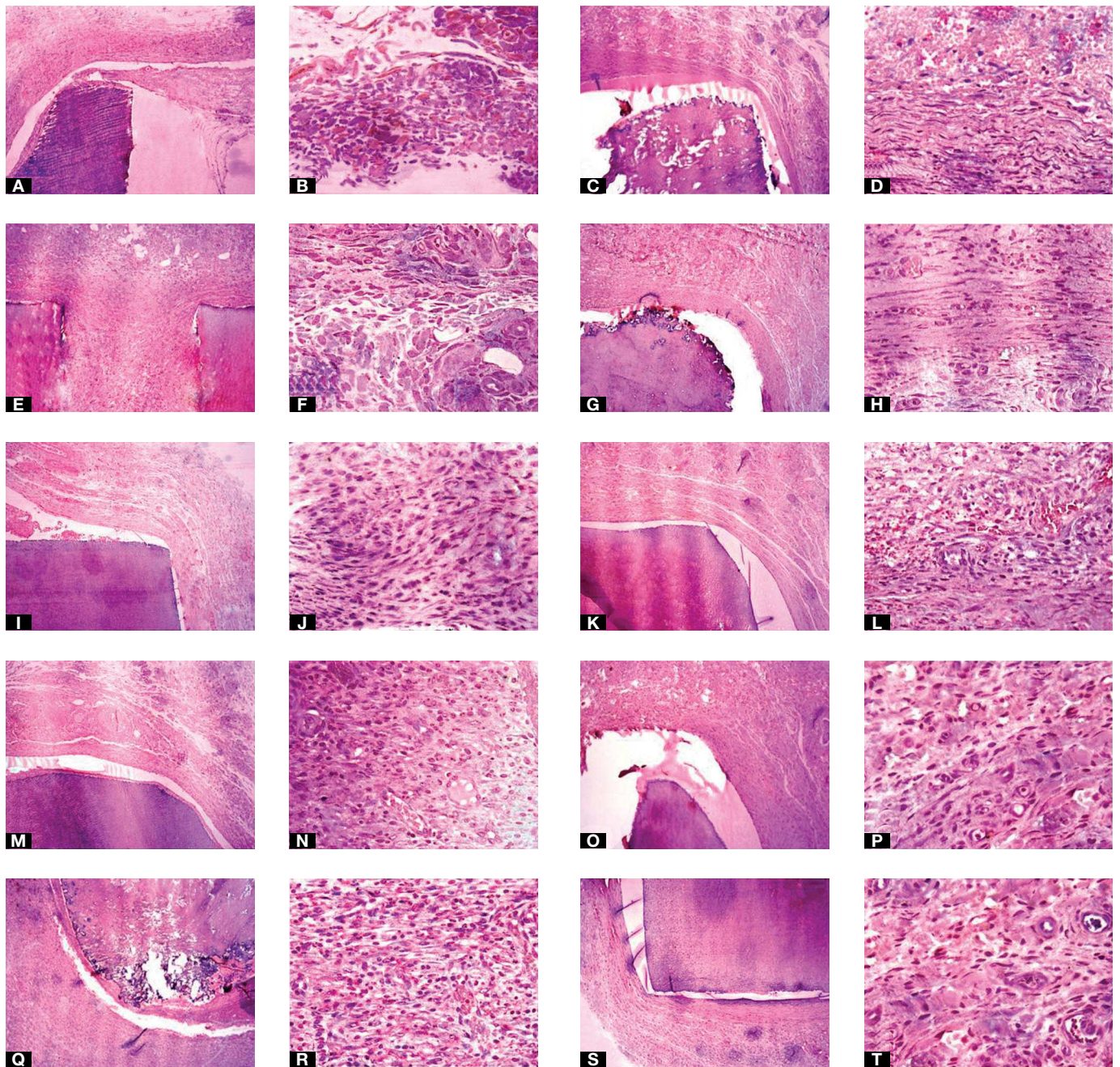
On the 7<sup>th</sup> day, a severe inflammatory cell infiltration consisting of neutrophils, lymphocytes and macrophages was present in the disorganized fibrous capsule (Figs 2Q and 2R). The intensity of the inflammation was reduced to moderate on the 30<sup>th</sup> day, consisting of chronic and acute cells in a completely disorganized fibrous capsule (Figs 2S and 2T).

### Comparison among groups

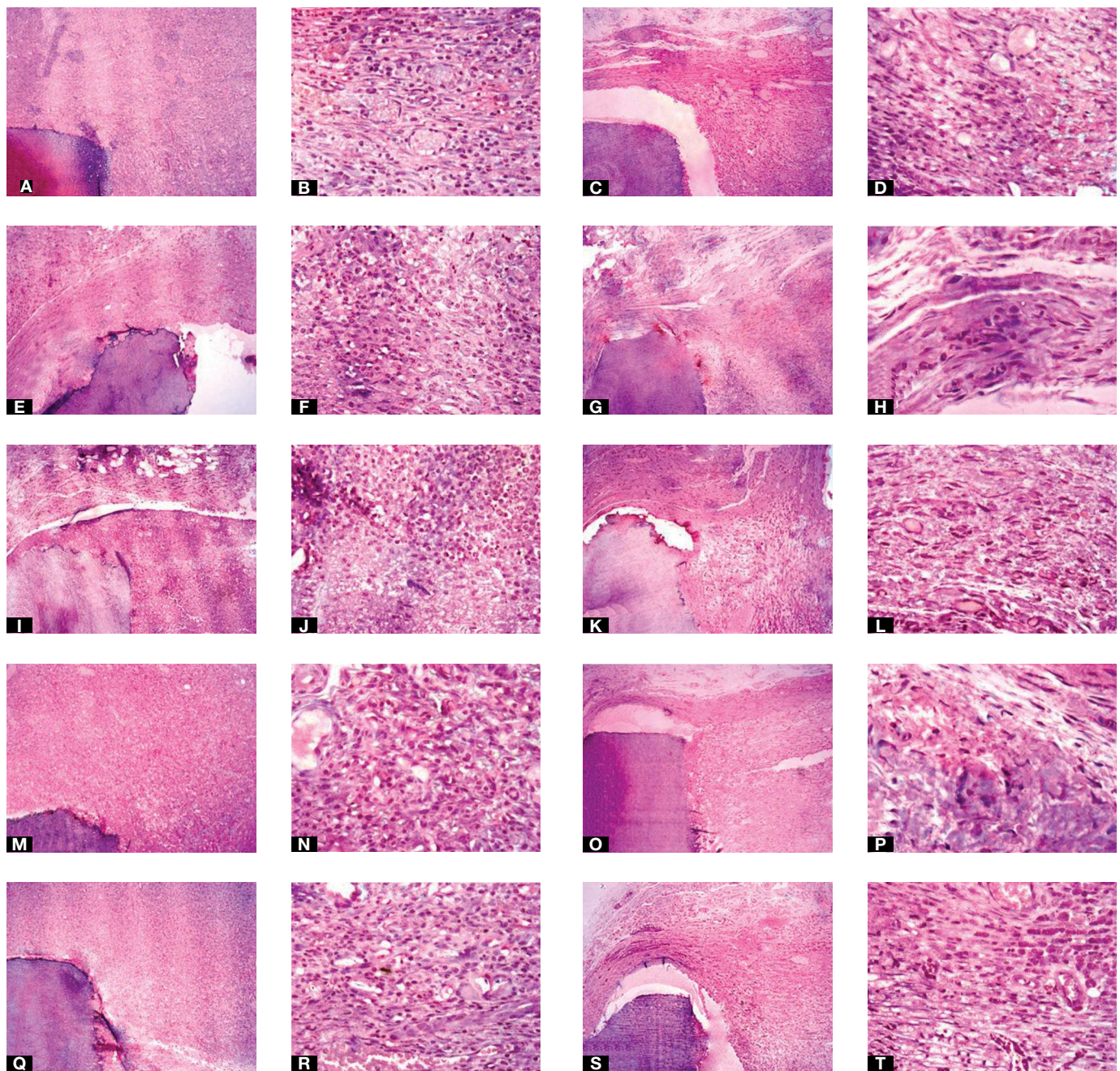
The data were compared in each period of time and are shown in Table 1.

### Uninfected dentin tubes

There was statistically significant difference ( $p < 0.05$ ) between the results observed on the 7<sup>th</sup> day (median 2)



**Figure 1.** Uninfected dentin tubes. 47ppm Ag NPs: **A, B**) thick fibrous capsule and moderate inflammatory cell infiltration (7 days, hematoxylin and eosin, 10x and 40x); **C, D**) thin fibrous capsule and mild inflammatory cell infiltration (30 days, hematoxylin and eosin, 10x and 40x). 23ppm Ag NPs: **E, F**) thick fibrous capsule and moderate inflammatory cell infiltration (7 days, hematoxylin and eosin, 10x and 40x); **G, H**) thin fibrous capsule and mild inflammatory cell infiltration (30 days, hematoxylin and eosin, 10x and 40x). 2.5% NaOCl: **I, J**) thick fibrous capsule and moderate inflammatory cell infiltration (7 days, hematoxylin and eosin, 10x and 40x); **K, L**) thin fibrous capsule and mild inflammatory cell infiltration (30 days, hematoxylin and eosin, 10x and 40x). Saline solution: **M, N**) thick fibrous capsule and moderate inflammatory cell infiltration (7 days, hematoxylin and eosin, 10x and 40x); **O, P**) thin fibrous capsule and mild inflammatory cell infiltration (30 days, hematoxylin and eosin, 10x and 40x). Control: **Q, R**) thick fibrous capsule and moderate inflammatory cell infiltration (7 days, hematoxylin and eosin, 10x and 40x); **S, T**) thin fibrous capsule and mild inflammatory cell infiltration (30 days, hematoxylin and eosin, 10x and 40x).



**Figure 2.** - Infected dentin tubes. 47ppm Ag NPs: **A, B**) thick fibrous capsule and severe inflammatory cell infiltration including the presence of neutrophils (7 days, hematoxylin and eosin, 10x and 40x); **C, D**) thin fibrous capsule and mild inflammatory cell infiltration (30 days, hematoxylin and eosin, 10x and 40x). 23ppm Ag NPs: **E, F**) thick fibrous capsule and severe inflammatory cell infiltration, observe the more organized tissue (7 days, hematoxylin and eosin, 10x and 40x); **G, H**) thin fibrous capsule and mild inflammatory cell infiltration (30 days, hematoxylin and eosin, 10x and 40x). 2.5% NaOCl: **I, J**) thick fibrous capsule and severe inflammatory cell infiltration (7 days, hematoxylin and eosin, 10x and 40x); **K, L**) thin fibrous capsule and mild inflammatory cell infiltration (30 days, hematoxylin and eosin, 10x and 40x). Saline solution: **M, N**) thick fibrous capsule and severe inflammatory cell infiltration (7 days, hematoxylin and eosin, 10x and 40x); **O, P**) thin fibrous capsule and mild inflammatory cell infiltration (30 days, hematoxylin and eosin, 10x and 40x). Control: **Q, R**) thick fibrous capsule and severe inflammatory cell infiltration (7 days, hematoxylin and eosin, 10x and 40x); **S, T**) thin fibrous capsule and moderate inflammatory cell infiltration (30 days, hematoxylin and eosin, 10x and 40x).

**Table 1.** Percentage of samples from each group, categorized according to the inflammatory score, presence of necrosis and thickness of the fibrous capsule.

Material	Score				Necrosis	Capsule
	0	1	2	3		
<b>7 days</b>						
47 ppm	0	0	100	0	Absent	Thick
23 ppm	0	0	100	0	Absent	Thick
2.5% NaOCl	0	0	100	0	Absent	Thick
Saline solution	0	0	100	0	Absent	Thick
Control	0	0	100	0	Absent	Thick
Infected 47 ppm	0	0	0	100	Absent	Thick
Infected 23 ppm	0	0	0	100	Absent	Thick
Infected NaOCl	0	0	0	100	Absent	Thick
Infected saline	0	0	0	100	Absent	Thick
Infected control	0	0	0	100	Absent	Thick
<b>30 days</b>						
47 ppm	0	100	0	0	Absent	Thin
23 ppm	0	100	0	0	Absent	Thin
2.5% NaOCl	0	100	0	0	Absent	Thin
Salina solution	0	100	0	0	Absent	Thin
Control	0	100	0	0	Absent	Thin
Infected 47 ppm	0	100	0	0	Absent	Thin
Infected 23 ppm	0	100	0	0	Absent	Thin
Infected NaOCl	0	100	0	0	Absent	Thin
Infected saline	0	100	0	0	Absent	Thin
Infected control	0	0	100	0	Absent	Thin

and 30<sup>th</sup> day (median 1) for all treatments. No statistically significant difference was observed among the materials on day 7 or 30 ( $p>0.05$ ).

### Infected dentin tubes

There was statistically significant difference ( $p<0.05$ ) among the results observed on the 7<sup>th</sup> day (median 3) and 30<sup>th</sup> day (median 1 for all treatments except for the control — median 2) for all treatments. No statistically significant difference ( $p>0.05$ ) was observed among the materials on the 7<sup>th</sup> day. On the 30<sup>th</sup> day, there was statistically significant difference among all treatments (median 1) ( $p<0.05$ ), except for control (median 2).

### Discussion

The aim of this study was to assess the biocompatibility and disinfection effect of Ag NPs dispersion for possible use as an irrigating solution in comparison to sodium hypochlorite. Infected dentin tubes were used to simulate a root canal infection which was obtained with saliva in order to generate a biofilm similar to that formed naturally with pulp exposure to the oral environment. Irrigation was used without instrumentation to achieve a critical condition aiming to test the irrigation solutions.

Biofilms are a result of a sequence of events: microbial surface attachment, cell proliferation, matrix

production, and detachment.<sup>8,21</sup> Endodontic infection is a biofilm-mediated infection, and the success of an endodontic treatment will depend on the effective elimination of bacterial biofilm from the root canal system.<sup>22</sup> Resistance of bacterial biofilm to disinfectants such as sodium hypochlorite and chlorhexidine is due to inherent microbiologic factors and the complex anatomy of the root canal system.<sup>22</sup>

In the present study, the uninfected control tubes exhibited moderate response in the beginning. This response was reduced to mild within 30 days and similar to other studies.<sup>15</sup> The infected control group exhibited a severe reaction in the beginning, which was reduced to moderate, showing persistence of the infection. The infection was reduced with saline solution irrigation, but the tissue was not completely organized evidencing some hazard in the healing process.

Sodium hypochlorite was biocompatible, since it was observed just a mild reaction after 30 days, similar to what was observed in the uninfected control tube. Sodium hypochlorite was also able to disinfect the dentin and it was evidenced by mild reaction after 30 days, corroborating previous reports.<sup>6,8</sup> Sodium hypochlorite is one of the most widely used endodontic irrigants due to its antibacterial activity and capacity of dissolving necrotic tissue remnants.<sup>7,8</sup> The antimicrobial effect of sodium hypochlorite is a result of the formation of hypochlorous acid (HOCl) when in contact with organic debris. HOCl exerts its effect by oxidation

of sulfhydryl groups within bacterial enzyme systems, thus, disrupting microbial metabolism.<sup>7,8</sup>

On the other hand, Ag NPs were also biocompatible exhibiting tissue response similar to that observed with 2,5% sodium hypochlorite in uninfected tubes. They were also able to disinfect the infected dentin tubes, similarly to the hypochlorite. Nevertheless, the fibrous capsule seemed to be more organized with 23 ppm Ag NPs than with 2,5% sodium hypochlorite or 47 ppm Ag NPs. Antibacterial experiments have demonstrated that silver is effective against a broad range of bacterial cells and mature biofilms; however, concentration is an important factor which can partially explain the results observed.<sup>8,21</sup> Nanoparticulates exhibit high antibacterial activity as a result of their polycationic/polyanionic nature, with high surface area and charge density, increasing the degree of interaction with the bacterial cell.<sup>22,23</sup>

Silver compounds have been extensively investigated in comparison to other metals because of their antibacterial, antifungal and antiviral actions.<sup>21,24,25</sup> Silver ions have been used in biomedical applications, including, within the dental field, as an antibacterial component in dental resin composites, tissue conditioners, acrylic resins, and mouthrinses.<sup>24,26-29</sup>

This study concluded that Ag NPs dispersion was biocompatible and able to disinfect the infected dentin tubes, similarly to 2.5% sodium hypochlorite. However, other studies are necessary to better analyze the behavior of this material and confirm the observed data.

## References

- Cobankara FK, Ozkan HB, Terlemez A. Comparison of organic tissue dissolution capacities of sodium hypochlorite and chlorine dioxide. *J Endod.* 2010;36(2):272-4.
- Iways S, Ikawa M, Kubota M. Revascularization of an immature permanent tooth with apical periodontitis and sinus tract. *Dent Traumatol.* 2001 ;17(4):185-7.
- Banchs F, Trope M. Revascularization of immature permanent teeth with apical periodontitis: new treatment protocol? *J Endod.* 2004;30(4):196-200.
- Hoshino E, Kurihara-Ando N, Sato I, Uematsu H, Sato M, Kota K, et al. In-vitro antibacterial susceptibility of bacteria taken from infected root dentine to a mixture of ciprofloxacin, metronidazole and minocycline. *Int Endod J.* 1996;29(2):125-30.
- Estrela CR, Estrela C, Reis C, Bammann LL, Pécora JD. Control of microorganisms in vitro by endodontic irrigants. *Braz Dent J.* 2003;14(3):187-92. Epub 2004 Mar 29.
- Gomes-Filho JE, Aurélio KG, Costa MM, Bernabé PF. Comparison of the biocompatibility of different root canal irrigants. *J Appl Oral Sci.* 2008;16(2):137-44.
- Siqueira JF Jr, Machado AG, Silveira RM, Lopes HP, de Uzeda M. Evaluation of the effectiveness of sodium hypochlorite used with three irrigation methods in the elimination of *Enterococcus faecalis* from the root canal in vitro. *Int Endod J.* 1997;30(4):279-82.
- Gomes-Filho JE, Silva FO, Watanabe S, Cintra LT, Tendoro KV, Dalto LG, et al. Tissue reaction to silver nanoparticles dispersion as an alternative irrigating solution. *J Endod.* 2010;36(10):1698-702.
- Aizawa M, Buriak JM. Block copolymer templated chemistry for the formation of metallic nanoparticle arrays on semiconductor surfaces. *Chem Mater.* 2007;19:5090-101.
- Su HL, Chou CC, Hung DJ, Lin SH, Pao IC, Lin JH, et al. The disruption of bacterial membrane integrity through ROS generation induced by nanohybrids of silver and clay. *Biomaterials.* 2009;30(30):5979-87.
- Chen J, Wiley B, McLellan J, Xiong Y, Li ZY, Xia Y. Optical properties of Pd-Ag and Pt-Ag nanoboxes synthesized via galvanic replacement reactions. *Nano Lett.* 2005;5(10):2058-62.
- Sun T, Seff K. Silver clusters and chemistry in zeolites. *Chem Rev.* 1994;94:857-70.
- Magana SM, Quintana P, Aguilar DH, Toledo JA, Angeles-Chavez C, Cortes MA, et al. Antibacterial activity of montmorillonites modified with silver. *J Mol Catal A Chem* 2008;281(1-2):192-9.
- Foldbjerg R, Olesen P, Hougaard M, Dang DA, Hoffmann HJ, Autrup H. PVP-coated silver nanoparticles and silver ions induce reactive oxygen species, apoptosis and necrosis in THP-1 monocytes. *Toxicol Lett.* 2009;190(2):156-62.
- Holland R, de Souza V, Nery MJ, Otoboni Filho JA, Bernabé PF, Dezan Júnior E. Reaction of rat connective tissue to implanted dentin tubes filled with mineral trioxide aggregate or calcium hydroxide. *J Endod.* 1999;25(3):161-6.
- American National Standards Institute. Revised American National Standards Institute American Dental Association (1979). Document no. 41: for recommended standard practices for biological evaluation of dental materials. New York, NY: American National Standards Institute; 1979.
- Federation Dentaire International recommended standard practices for biological evaluation of dental materials. Federation Dentaire International Commission on Dental Materials, Equipment, and Therapeutics: Part 4: 11 subcutaneous implantation test. *Int Dental J.* 1980;30:173-4.
- Gomes-Filho JE, Gomes BP, Zaia AA, Novaes PD, Souza-Filho FJ. Glycol methacrylate: an alternative method for embedding subcutaneous implants. *J Endod.* 2001;27(4):266-8.
- Costa CA, Teixeira HM, Nascimento AB, Hebling J. Biocompatibility of two current adhesive resins. *J Endod.* 2000;26(9):512-6.
- Yaltirik M, Ozbas H, Bilgic B, Issever H. Reactions of connective tissue to mineral trioxide aggregate and amalgam. *J Endod.* 2004;30(2):95-9.
- Monteiro DR, Gorup LF, Takamiya AS, Ruvullo-Filho AC, Camargo ER, Barbosa DB. The growing importance of materials that prevent microbial adhesion: antimicrobial effect of medical devices containing silver. *Int J Antimicrob Agents.* 2009;34(2):103-10.
- Shrestha A, Shi Z, Neoh KG, Kishen A. Nanoparticulates for antibiofilm treatment and effect of aging on its antibacterial activity. *J Endod.* 2010;36(6):1030-5.
- Kishen A, Shi Z, Shrestha A, Neoh KG. An investigation on the antibacterial and antibiofilm efficacy of cationic nanoparticulates for root canal disinfection. *J Endod.* 2008;34(12):1515-20.
- Allaker R. P. The use of nanoparticles to control oral biofilm formation. *J Dent Res.* 2010;89(11):1175-86.
- Elechiguerra JL, Burt JL, Morones JR, Camacho-Bragado A, Gao X, Lara HH, et al. Interaction of silver nanoparticles with HIV-1. *J Nanobiotechnology.* 2005 Jun 29;3:6.
- Casemiro LA, Gomes Martins CH, Pires-de-Souza FC, Panzeri H. Antimicrobial and mechanical properties of acrylic resins with incorporated silver-zinc zeolite - Part 1. *Gerodontology.* 2008;25(3):187-94.
- Herrera M, Carrión P, Baca P, Liébana J, Castillo A. In vitro antibacterial activity of glass-ionomer cements. *Microbios.* 2001;104(409):141-8.
- Kawahara K, Tsuruda K, Morishita M, Uchida M. Antibacterial effect of silver-zeolite on oral bacteria under anaerobic conditions. *Dent Mater.* 2000;16(6):452-5.
- Rai M, Yadav A, Gade A. Silver nanoparticles as a new generation of antimicrobials. *Biotechnol Adv.* 2009;27(1):76-83.