

Influence of observer's experience on diagnosing simulated periapical lesions

Edith **LARA-CARRILLO**¹

Gabriel **ARZATE-SOSA**²

doi: <http://dx.doi.org/10.1590/2178-3713.4.3.034-041.oar>

ABSTRACT

Objective: To compare the performance of observers with different knowledge when detecting periapical lesions.

Methods: We obtained nine dry human hemimandibles. Periapical lesions were created with a bur and radiographic sets were taken for each hemimandible in four stages (initial, no cancellous bone, removal of 0.5 and 1 mm of cortical bone). Each radiographic set comprised five digital radiographs taken at different angulations (ortho, mesio, disto, lingual and vestibuloradial). Thirty six radiographs sets were obtained with a total of 180 images. The images were evaluated by experienced examiners and students. Mann Whitney test

and Spearman's correlation were applied for data comparison. **Results:** In all study stages, no statistically significant differences were found ($P \leq 0.05$) between observers, with a positive association established by Spearman's correlation in two stages (removal of 0.05 and 1 mm of cortical bone; 0.866 and 0.500, respectively). **Conclusions:** There were no statistically significant differences in diagnostic accuracy between experienced examiners and students when detecting simulated periapical lesions in dry human mandibles.

Keywords: Dental education. Dental radiography. Endodontics. Diagnostic imaging.

How to cite this article: Lara-Carrillo E, Arzate-Sosa G. Influence of observer's experience on diagnosing simulated periapical lesions. *Dental Press Endod.* 2014 Sept-Dec;4(3):34-41. DOI: <http://dx.doi.org/10.1590/2178-3713.4.3.034-041.oar>

» The authors report no commercial, proprietary or financial interest in the products or companies described in this article.

Submitted: April 25, 2014. Revised and accepted: May 05, 2014.

Contact address: Edith Lara-Carrillo
Facultad de Odontología Universidad Autónoma del Estado de México
Paseo Tollocan esq. Jesús Carranza Colonia Universidad – C.P. 50130
Toluca – Estado de México – Mexico
E-mail: laracaedith@hotmail.com

¹Professor, Department of Pediatric Dentistry, Universidad Autónoma del Estado de México.

²MSc in Endodontics, Instituto de Estudios Avanzados en Odontología Dr. Yury Kuttler.

Introduction

Periapical lesions are located inside the jaws. They are characterized by cancellous and cortical bone loss, which is primarily caused by bacterial invasion into the periapical dental area, and their identification is often difficult. Root canal treatment is the method of choice not only for killing these microorganisms, but also for allowing bone repair. Additionally, intraoral radiographs are essential for proper root canal treatment. The need for appropriate diagnosis to locate periapical radiolucent areas promoted the use of various methods, such as the horizontal and vertical variation of x-ray direction.

In 1910, Clark introduced the technique known as Same Lingual Opposite Buccal (SLOB). This principle is based on the change in position of an object present in the radiographic examination when the horizontal projection angle is modified. Three radiographs are taken: the first is taken directly over the tooth, which we will call central or ortho position; whereas the second is mesial to this position, and the third is taken distal to the first or central position. If the subject image is projected in the direction of the tube, which moves towards mesial or distal, the object is located in the lingual or palatal surface; however, if the object is projected opposite the tube direction, it is located in the buccal surface.¹⁻⁴

The number of films used and the vagueness of instructions made Clark's rule unsatisfactory. For this reason, in 1952, Richards amended this rule and went on using only two radiographs: Changing the vertical angulation causes the images of the buccal root apices to move vertically in relation to the lingual apices and in the same direction in which the x-ray beam is directed. This rule is referred to as the BAMA rule: Buccal Always Moves Away. The horizontal angulation should be changed when attempting to locate a point in relation to a vertical line, such as a root canal; the vertical angulation, however, should be changed when attempting to locate a point in relation to a horizontal line, such as the mandibular canal.^{3,5,6,7}

With advances in technology, digital imaging offers advantages in comparison to film-based radiography; for instance, it allows better resolution and speed, in addition to eliminating mistakes in conventional radiographic processing. Likewise, this technology offers faster image acquisition and instant replay, and allows

images to be retained for future reference. Moreover, digital images can be enlarged, easily stored in a computer and require little radiation dose.⁸⁻¹³

Numerous studies^{14,15,16} have been conducted to investigate the radiological identification of anatomical features by experienced and unexperienced forensic dentists, but only a few studies have assessed groups with different levels of dental clinical experience identifying oral diseases such as periapical lesions. Thus, the aim of this study was to compare the performance of observers with different levels of knowledge when detecting periapical lesions by means of horizontal and vertical angulations in dry human mandibles.

Material and methods

This study sample comprised ten dry human hemimandibles, but one was eliminated because its first left molar had previous root canal treatment, which was an exclusion criteria.

Preparation

Human research ethics approval was obtained from the Institute for Advanced Studies in Dentistry Dr. Yuri Kuttler in Mexico City.

In the left hemimandibles, we made a square acrylic base in the mandible angle so as to position it in the horizontal plane. On the other hand, in the right hemimandibles, the acrylic base was made in the front area of the mandible.

Each hemimandible was set in a device fabricated to standardize the projection at different angulations (orthoradial, mesioradial, distoradial, linguoradial and vestibuloradial) before any bone defect was created (Fig 1).

In each hemimandible, we obtained a buccal wall block using slow speed fissure carbure burs (Meisinger HM 15101, Germany) in four different cuts:

1. At the upper mandible border, including molars and premolars.
2. Five millimeters away from the distal surface of the last molar present, vertically towards the lower mandible border.
3. Between the first premolar and canine, vertically towards the lower mandible border.
4. Along the lower mandible border so as to join the second and third cuts.

Chisels were used to separate the buccal wall block, and thickness was measured with a caliper (Fig 2).

In the buccal wall block, we removed 3 mm of cancellous bone using chisels in the apical direction of the first molar (Fig 3A). We repositioned the buccal wall block holding it with plastic strips so as to avoid movement while the radiographs were taken (Fig 3B).

Afterwards, we performed periapical dental lesions at two different depths in the same place where cancellous bone had been previously removed. To this end, high-speed wheel diamond burs (6909, Brasseler, USA) with a diameter of 3 mm were used in each hemimandible, as follows:

1. We separated the buccal wall block and created the first defect with a thickness of 0.5 mm.
2. The buccal wall blocks were repositioned and the periapical radiographs taken.
3. The second defect was created in the same place with a thickness of 1 mm.
4. Again, the buccal wall blocks were repositioned and the last set of radiographs was taken (Fig 4).

The periapical dental lesions were created on the following sites:

- » Mandible 1:
 - Right hemimandible — Periapical on the mesial root of the second molar.




Figure 1. Device used to take radiographic images with different angulations.

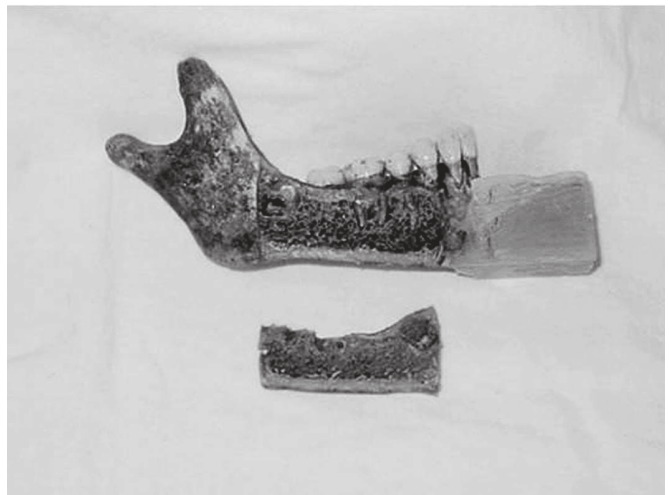
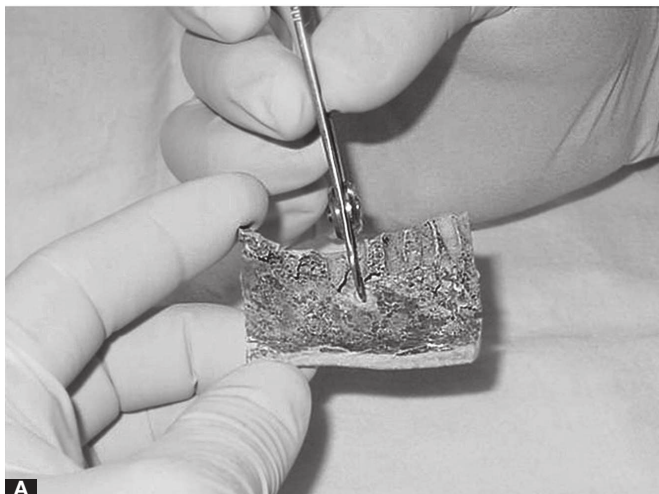
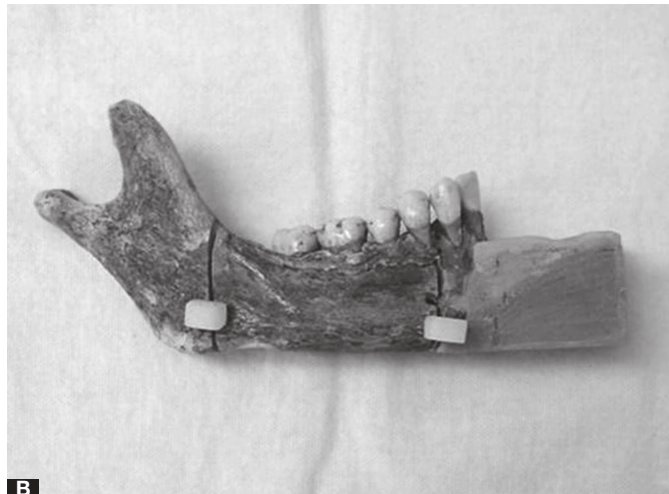


Figure 2. Separation of the buccal cortical wall.



A



B

Figure 3. **A**) Cancellous bone removed with chisels; **B**) Cortical wall repositioned for radiograph taking.

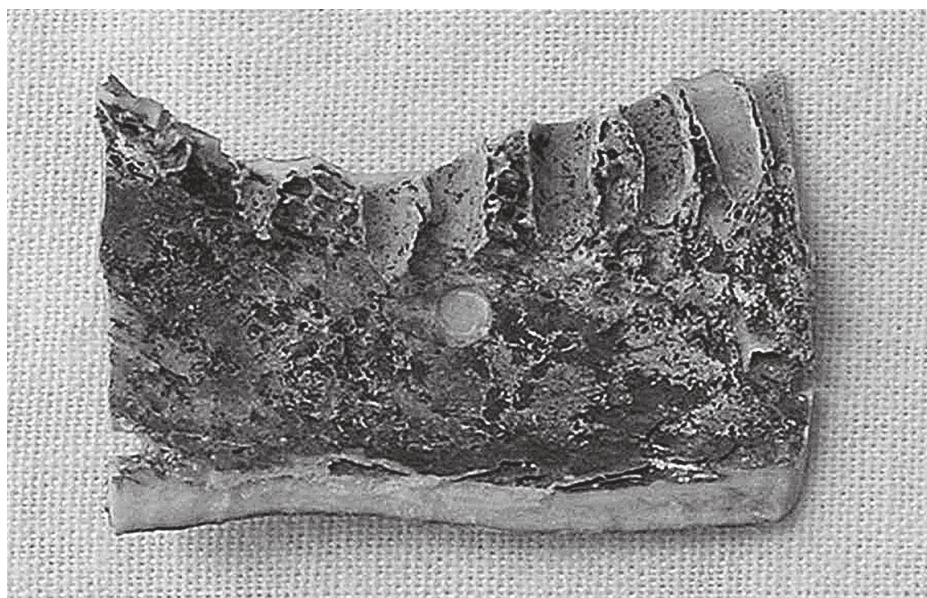

Figure 4. Wear to simulate periapical lesions at two different depths.

- Left hemimandible — Periapical on the distal root of the first molar.
- » Mandible 2:
 - Right hemimandible — Periapical on the distal root of the first molar.
 - Left hemimandible — Periapical on the mesial root of the second molar.
- » Mandible 3:
 - Right hemimandible — Periapical on the mesial root of the second molar.
 - Left hemimandible — Periapical on the distal root of the first molar.
- » Mandible 4:
 - Right hemimandible — Periapical on the distal root of the first molar.
 - Left hemimandible — Periapical on the mesial root of the second molar.
- » Mandible 5:
 - Right hemimandible — Periapical on the mesial root of the second molar.
 - Left hemimandible — Missing.

The amount of bone removed was confirmed by a caliper.

Image acquisition

In each hemiarch, four radiographic sets were taken at each stage:

- » Stage 1: Before any cut or wear.

- » Stage 2: After cuts of the cortical wall and cancellous bone removal.

- » Stage 3: After the periapical dental lesion was performed with 0.5 mm in depth at the same site where the cancellous bone was removed.

- » Stage 4: After the periapical dental lesion was performed with 1 mm in depth at the same site mentioned in stage 3.

At each stage, five digital images were taken (RVG Kodak 5100, Rochester, NY, USA) according to the following exposure parameters: 70 kV, 8 mA and distance between the focal-spot and the sensor set at 20 cm. Images were acquired from different angulations: orthoradial, mesioradial, distoradial, linguoradial and vestibuloradial. Subsequently, 36 radiographic sets were obtained with a total of 180 images. The digital images were saved and stored in TIFF format without compression (8 bits, with a resolution of 600 dpi and a file size about 700 kB).

The images were assessed by six examiners divided into two categories: experienced examiners (three specialists in Endodontics with over 20 years of experience) and three students of the Masters degree in Endodontics at the Institute for Advanced Studies in Dentistry “Dr. Yuri Kuttler” in Mexico City.

By blind form, the 180 images were randomly projected for 30 seconds and grouped in radiograph sets in the five angulations (orthoradial, mesioradial, distoradial, linguoradial and vestibuloradial) so as to give

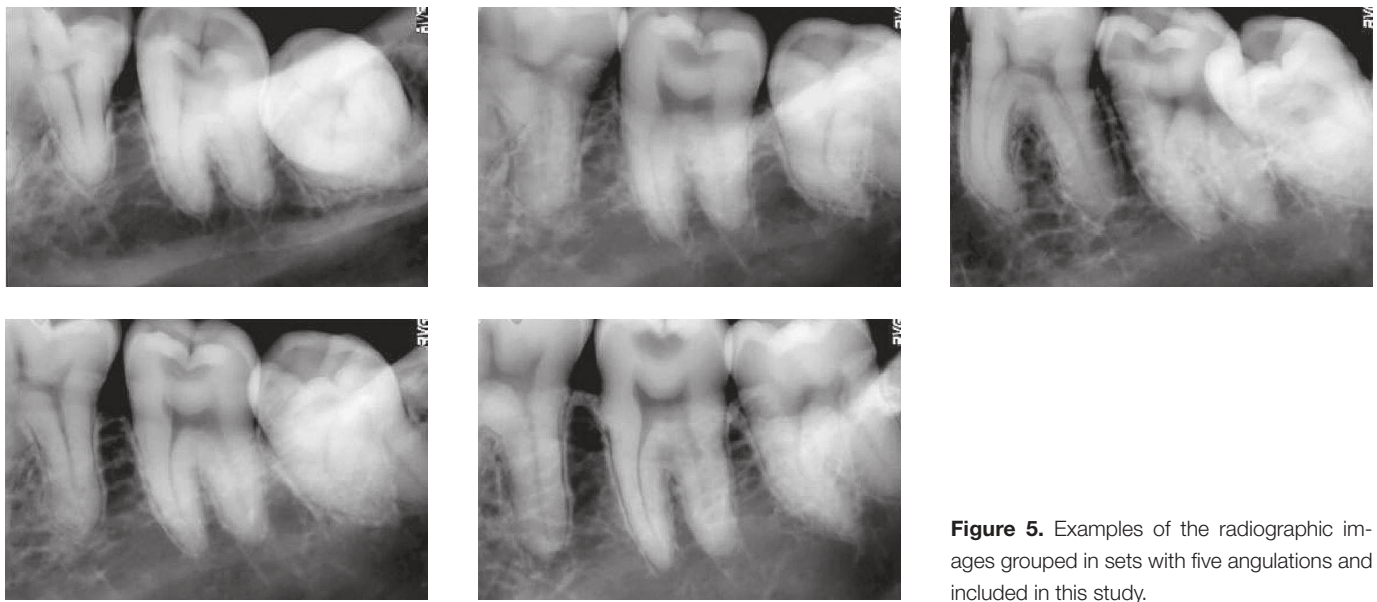


Figure 5. Examples of the radiographic images grouped in sets with five angulations and included in this study.

examiners a complete view of the periapical lesion and allow them to identify the best angle they were able to observe the radiolucent area (Fig 5).

We conducted separate sessions for experienced observers and students. Examiners were seated at approximately 300 cm away from the screen, and the images were projected at a distance of 380 cm on a screen 180 cm wide x 180 cm long. The computer image measured 30 cm; however, when projected, the image was 150 cm x 150 cm with a magnification of 5X.

The examiners were trained before the sessions based on the following instructions:

- We will project 180 individual images and 36 sets of images from five different angles.
- You must identify the radiolucent areas.
- You must indicate the best angle from which the periapical lesion was identified.

Statistical analysis

The data obtained in both groups (experienced examiners and students), when detecting simulated periapical lesions, were compared by means of the Mann Whitney test and Spearman's correlation using Minitab statistical package version 15 (Minitab, Inc., USA, 2008) with a P-value set at 0.05.

Results

Table 1 shows that, at early stages in which bone loss was minor, observers did not report periapical lesions. However, whenever bone loss was greater, as at stages 3 and 4, both groups frequently reported that periapical lesions were observed radiographically, especially in radiographs taken in vestibulo-radial angulation.

To compare the identification of periapical lesions between experienced examiners and students, we used the nonparametric Mann-Whitney test, since two small independent samples and variable measurements were used. We compared both groups in each radiographic angulation and at each stage of the study. Results revealed that no statistically significant differences ($P < 0.05$) were found between experienced examiners and students detecting simulated periapical lesions.

Only a few cases at stages 3 and 4 (cortical wear 0.5 and 1.0-mm deep) were statistically significant ($P \leq 0.08$) when assessing images in mesioradial angulation (Table 1).

With the results of the Mann Whitney test, we applied Spearman's correlation only at stage 3 and 4, with a view to comparing experienced examiners

Table 1. Medians by stages with different angles between examiners groups.

| Stages | Angulations | | | | | | | | | |
|---------|-------------|----|--------|----|--------|----|---------|----|--------|----|
| | Ortho | | Mesio | | Distal | | Lingual | | Buccal | |
| | OX | SO | OX | SO | OX | SO | OX | SO | OX | SO |
| Stage 1 | 0 | 0 | 0 | 0 | 0 | 0 | 1 | 0 | 0 | 0 |
| p | * | | * | | * | | * | | * | |
| Stage 2 | 0 | 0 | 0 | 0 | 0 | 0 | 0 | 0 | 0 | 0 |
| p | * | | * | | * | | * | | * | |
| Stage 3 | 3 | 4 | 1 | 3 | 5 | 5 | 0 | 1 | 9 | 8 |
| p | 0.3687 | | 0.0765 | | 1.000 | | 0.4795 | | * | |
| Stage 4 | 7 | 6 | 2 | 4 | 5 | 7 | 1 | 4 | 9 | 9 |
| p | 1.000 | | 0.0722 | | 0.4936 | | 0.0765 | | * | |

OX= experienced observers; SO= students observers. P value was based on Mann Whitney test. P value was set at 0.05. * all values were identical.

Table 2. Correlations between examiners groups, at stages 3 and 4.

| Variable | Variable | r-value | p-value |
|----------|----------|---------|---------|
| S3_OX_O | S3_SO_O | -0.500 | 0.667 |
| S3_OX_M | S3_SO_M | 0.866 | 0.333 |
| S3_OX_D | S3_SO_D | -0.500 | 0.667 |
| S3_OX_L | S3_SO_L | 0.866 | 0.333 |
| S3_OX_V | S3_SO_V | * | * |
| S4_OX_O | S4_SO_O | -0.945 | 0.212 |
| S4_OX_M | S4_SO_M | 0.500 | 0.667 |
| S4_OX_D | S4_SO_D | -0.500 | 0.667 |
| S4_OX_L | S4_SO_L | 0.000 | 1.000 |
| S4_OX_V | S4_SO_V | * | * |

S3= stage three; S4= stage four; OX= experienced observers; SO= students observers; O= orthoradial; M= mesioradial; D= distoradial; L= linguoradial; V = vestibuloradial. = Spearman's correlation coefficient. P value was set at 0.05. * = all values were identical.

and students in each of the radiographic angles obtained. Spearman's correlation confirmed that there were no statistically significant differences ($P < 0.05$), but there was a positive association at stages 3 and 4 (0.866 and 0.500, respectively) for images in the mesioradial angulation (Table 2).

Discussion

It is widely known that mandible bone is more compact and has a thicker cortical than maxillary bone. Whenever 12.5% of cortical or 6.6% of minerals are lost, a periapical lesion must be radiographically detected. These alterations can be maintained without important changes due to the protection of these corticals even after death.¹⁷

Marmary et al¹⁸ showed that periapical lesions can be diagnosed based on periapical radiographs when they are still limited to the cancellous bone and before they have eroded the cortices. Our results show that at the early stages of this research (after removing cortical and cancellous bone), it was difficult to observe the radiolucent areas created, regardless of the observer's experience.

Periapical lesion is usually monitored in a subjective manner and with the aid of conventional radiographs, which does not assure precise identification of periapical lesion changes or extension. Digital radiography and image analysis software have provided more precise radiographic evaluation of periapical lesion areas assessed in different follow-up periods.¹¹

Digital images can be modified in terms of tone, brightness, color and contrast, which avoids the presence of dark areas that hamper identification.

The use of digital images offers larger images with a consistent resolution and allows projection without deformation, thereby facilitating observation and identification of normal and pathological structures without observer's experience being a decisive factor.

Intraoral radiography plays an adjunctive role in diagnosis. An x-ray image shows an object in two dimensions; however, it is well known that structures are in three dimensions. In some occasions, it is difficult to determine the apex of a tooth, either due to the tip of the apex not being viewed on the radiograph or being obscured by some other feature or artifact. Variations in the direction of the beam allows the structures that difficult the identification of anatomical and pathological components to move.

It is recommended that intraoral radiographs be taken at different X-ray beam angles, so as to reduce the risk of periapical involvement. Walton¹ recommends changing the horizontal angle to observe the third dimension using the buccal object rule which has been reported by numerous investigators.^{2-5,19}

Brynolf²⁰ asserts that when three different angles (ortho, mesio and distoradial) are used, it increases the accuracy of radiographic interpretation from 74% to 90%.

Goering² highlights the importance of different horizontal and vertical angles to visualize the morphological characteristics of periodontal and endodontic diseases.

Based on the above, we used in our study five recommended angles (ortho, mesio, disto, lingual and vestibuloradial).¹⁻⁷ But it is worth noting that both groups

frequently reported more periapical lesions in vestibuloradial images, at the last stages of this research.

Tveit et al⁷ assessed the diagnoses of caries adjacent to restorations with different radiopacities by means of variations in vertical angulation. They concluded that the quality of secondary caries diagnosis was not significantly affected by variations in vertical angulation. In the present research, the X-ray beam projection angle was found to affect the accuracy of periapical lesion diagnosis.

In agreement with Hishikawa et al,²¹ we found higher detectability of defects created in vestibular angulations. The authors also obtained the highest values with angulations of 10 to 20° mesially.

In the present study, we demonstrate that experience is not a determining factor in identifying normal and pathological anatomical and periapical lesions; however, Flint et al.¹⁹ mention that experienced forensic dentists have higher level of accuracy in radiological identification than those without experience.

Our methods were similar to those used by De Molon⁹ whose study compares embossed digital and unprocessed film-based images, as well as direct visual measurements in dry pig mandibles used to detect bone defects. Measurements were taken by experienced, graduate and undergraduate students with no differences among observers who yielded satisfactory results.

In conclusion, there were no statistically significant differences in the diagnostic accuracy of experienced examiners and students detecting simulated periapical lesions in dry human mandibles.

Furthermore, the use of both horizontal and vertical angles allow better identification of anatomical and pathological structures, since it provides different diagnostic perspectives.

References

- Walton RE. Endodontic radiographic techniques. *Dent Radio Photogr.* 1973;46:51-9.
- Goering CA, Elmer J. A simplified look at the buccal object rule in endodontics. *J Endod.* 1987;13(12):570-2.
- Gröndahl K, Gröndahl HG, Webber RL. Influence of variations in projection geometry on the detectability of periodontal bone lesion. A comparison between subtraction radiography and conventional radiographic technique. *J Clin Periodontol.* 1984;11:411-20.
- Clark CA. A method of ascertaining the relative position of unerupted teeth by means of film radiographs. *Proc R Soc Med.* 1910;3(Odontol Sect):87-90.
- Richards AG. Roentgenographic localization of the mandibular canal. *J Oral Surg (Chic).* 1952;10(4):325-9.
- Wenzel A. Dental student's ability for three-dimensional perception of two-dimensional images using natural stereopsis: its impact on radiographic localization. *Dentomaxillofac Radiol.* 1999;28(2):98-104.
- Tveit AB, Espelid I, Erickson RL, Glasspoole EA. Vertical angulation of the x-ray beam and radiographic diagnosis of secondary caries. *Community Dent Oral Epidemiol.* 1991;19(6):333-5.
- Ting NA, Broadbent JM, Duncan WJ. Dental radiography in New Zealand: digital versus film. *N Z Dent J.* 2013;109(3):107-14.
- Molon RS, Sakakura CE, Morais-Carrillo JAND, Almeida Júnior PC, Castro MLL, Scaf G. Comparison between embossed digital imaging and unprocessed film-based radiography in detecting periodontal bone defects: an in vitro study. *Oral Radiol.* 2012;28:95-100.
- Farida A, Maryam E, Ali M, Ehsan M, Sajad Y, Soraya K. A comparison between conventional and digital radiography in root canal working length determination. *Indian J Dent Res.* 2013;24(2):229-33.
- Carvalho FB, Goncalves M, Guerreiro-Tanomaru JM, Tanomaru-Filho M. Evaluation of periapical changes following endodontic therapy: digital subtraction technique compared with computerized morphometric analysis. *Dentomaxillofac Radiol.* 2009;38(7):438-44.
- Alcaraz M, Velasco F, Martínez-Beneyto Y, Alcaraz-Saura M, Velasco E, Achel GD, et al. Evolution of diagnostic reference levels in Spanish intraoral radiology. *Radiat Prot Dosimetry.* 2012;151(1):166-71.
- Hellstern F, Geibel MA. Quality assurance in digital dental radiography-justification and dose reduction in dental and maxillofacial radiology. *Int J Comput Dent.* 2012;15(1):35-44.
- Sholl SA, Moody GH. Evaluation of dental radiographic identification: an experimental study. *Forensic Sci Int.* 2001;115(3):165-9.
- Hemasathya BA, Balagopal S. A study of composite restorations as a tool in forensic identification. *J Forensic Dent Sci.* 2013;5(1):35-41.
- Soomer H, Lincoln MJ, Ranata H, Penttilä A, Leibur E. Dentists' qualifications affect the accuracy of radiographic identification. *J Forensic Sci.* 2003;48(5):1121-6.
- Bender IB. Factors influencing the radiographic appearance of bony lesions. *J Endod.* 1982;8:161-70.
- Marmary Y, Koter T, Helling I. The effect of periapical rarefying osteitis on cortical and cancellous bone. A study comparing conventional radiographs with computed tomography. *Dentomaxillofac Radiol.* 1999;28(5):267-71.
- Flint DJ, Dove SB, Brumit PC, White M, Senn DR. Computer-aided dental identification: an objective method for assessment of radiographic image similarity. *J Forensic Sci.* 2009;54(1):177-84.
- Brynof I. Roentgenologic periapical diagnosis. II. One, two or more roentgenograms? *Sven Tandlak Tidskr.* 1970;63(5):345-50.
- Hishikawa T, Izumi M, Naitoh M, Furukawa M, Yoshinari N, Kawase H, et al. The effect of horizontal x-ray beam angulation on the detection of furcation defects of mandibular first molars in intraoral radiography. *Dentomaxillofac Radiol.* 2010;39(2):85-90.