

# An unusual maxillary second molar with two palatal root canals: a case report

Humberto Ramah Menezes de **MATOS**<sup>1</sup>

Aldo **ANGELIM-DIAS**<sup>2</sup>

Vanessa Anastácio de **OLIVEIRA**<sup>3</sup>

Suyane Parente **LEITE**<sup>3</sup>

Wlhadya Kaenny de Freitas **COSTA**<sup>3</sup>

DOI: <http://dx.doi.org/10.14436/2358-2545.6.1.038-042.cre>

## ABSTRACT

**Introduction:** Maxillary second molars usually have three root canals. However, this group of teeth has a complex internal anatomy, and sometimes one may encounter morphological variation. **Objective:** This study reports a case of morphological variation in a maxillary second molar with two palatal root canals in which all canals were treated endodontically. **Case report:** A healthy 50-year-old male patient arrived at the private dental clinic for endodontic treatment of his maxillary right second molar (#17). The patient reported having undergone an emergency procedure due to pain of pulpal origin. At clinical

examination, thermal stimulus to cold, vertical and horizontal percussion and palpation were performed, all of which yielded negative results. Additionally, radiographic examination was taken. Second molar was diagnosed with pulp necrosis without apical periodontitis. To better diagnosis internal morphology, visual examination with surgery was carried out, and a second root canal was found at the distal face. **Conclusion:** Although variations in the amount of root canals rarely occur in the palatal root, especially in the maxillary second molar region, clinicians should be aware of potential variations.

**Keywords:** Molar. Dental pulp cavity. Root canal therapy.

**How to cite this article:** Matos HRM, Angelim-Dias A, Oliveira VA, Leite SP, Costa WKF. An unusual maxillary second molar with two palatal root canals: a case report. *Dental Press Endod.* 2016 Jan-Apr;6(1):38-42.

DOI: <http://dx.doi.org/10.14436/2358-2545.6.1.038-042.cre>

<sup>1</sup>MSc student in Clinical Dentistry (Endodontics), Universidade Estadual de Campinas (FOP-UNICAMP), School of Dentistry, Piracicaba, São Paulo, Brazil.

<sup>2</sup>Professor, Universidade de Fortaleza (Unifor), Department of Dentistry, Fortaleza, Ceará, Brazil.

<sup>3</sup>Undergraduate student of Dentistry, Universidade de Fortaleza (UNIFOR), Fortaleza, Ceará, Brazil.

» The authors report no commercial, proprietary or financial interest in the products or companies described in this article.

» Patients displayed in this article previously approved the use of their facial and intraoral photographs.

Submitted: 16/12/2015. Revised and accepted: 01/04/2016.

Contact address: Humberto Ramah Menezes de Matos  
E-mail: [betto\\_menezes@hotmail.com](mailto:betto_menezes@hotmail.com)

## Introduction

The main goal of endodontic therapy is to prevent apical periodontitis and/or healing of present periapical lesion. To this end, one must clean, shape and seal the root canal system, otherwise it would cause endodontic treatment failure. Knowledge of the inner morphology of root canals and potential variations in each tooth is necessary, so that treatment with the appropriate auxiliary tools associated with chemical solutions can be implemented, thus promoting disinfection and providing complete filling of the root canal. If the endodontist cannot identify the presence of extra root canals, it may result in treatment failure.<sup>1</sup>

In permanent dentition, molars are the teeth most frequently associated with endodontic failure,<sup>2,3</sup> particularly the maxillary first molar. Most studies in the literature have focused on morphology of the mesio-buccal root, particularly its mesiobuccal opening.<sup>4</sup> The presence of a second root canal in the mesio-buccal root is the main factor of root canal therapy failure when one cannot locate its opening.<sup>3,4,5</sup> Literature reviews have used different methods to determine the incidence of this root canal, such as computed tomography,<sup>5,6</sup> digital radiographs,<sup>7</sup> diaphanization,<sup>8</sup> among others. The incidence of a root canal in the mesio-palatal root has been reported between 18% and 96.1%.<sup>9,10</sup> Cases reported by Kottoor et al<sup>11</sup> and Badole et al<sup>12</sup> showed that maxillary first molars with seven root canals have a low incidence. To diagnose such variations, the use of clinical radiograph and CT are most often used.

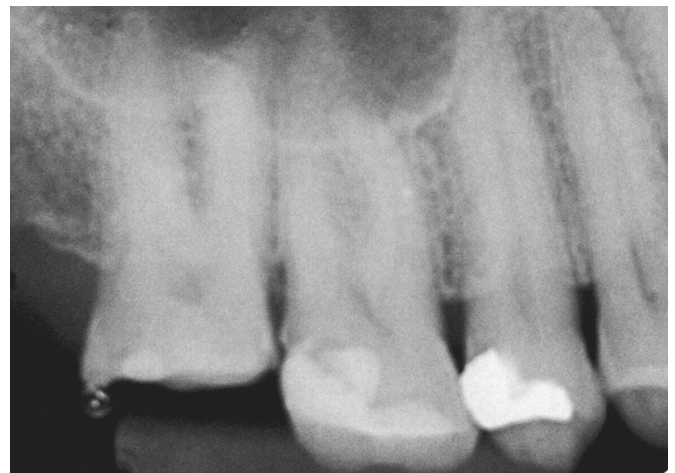The same variation can be found for maxillary second molars. This group of teeth also exhibits inner anatomic variations of clinical relevance. Among them, the number of root canals has been reported. The incidence of two palatal root canals is low.<sup>13,14</sup> The literature reveals that the presence of such variation ranges between 0.4% and 1.4%.<sup>15-18</sup>

## Case report

A healthy 50-year-old male patient arrived at the private dental clinic for endodontic treatment of his maxillary right second molar.<sup>17</sup> The patient reported having undergone an emergency procedure due to pain of pulpal origin. During anamnesis, the patient reported no pain while drinking cold or hot liquids,

eating hot or cold food or while chewing. At clinical examination, thermal stimulus to cold, vertical and horizontal percussion and palpation were performed, all of which yielded negative results. The condition was diagnosed as pulp necrosis and asymptomatic apical periodontitis. Endodontic treatment was then initiated. Pretreatment radiograph revealed a highly radiopaque material on the tooth structure. There was no radiolucency area compatible with bone thinning in root tips. The pulp chamber showed to be relatively small and the root with atresic root canals (Fig 1).

After anesthesia with 2% lidocaine with epinephrine 1:100.000 (DFL, Rio de Janeiro, Brazil), the temporary restoration was removed with a diamond bur (1013, KG Sorensen Barueri, Brazil) and access cavity was performed under rubber dam isolation. 2.5% sodium hypochlorite was used as an auxiliary chemical substance to irrigate the root canals during cleaning and shaping. An endodontic probe DG16 was used to explore the pulp chamber floor, allowing identification of the mesiobuccal root



**Figure 1.** Initial radiograph showing extensive temporary restoration of tooth #17 and no periapical radiolucency.

canals, distobuccal root canal and two palatal root canals. To better diagnose the anatomical variation of the case, visual examination with optical microscopy (DF Vasconcellos M900) was carried out, and a second root canal was found (Fig 2).

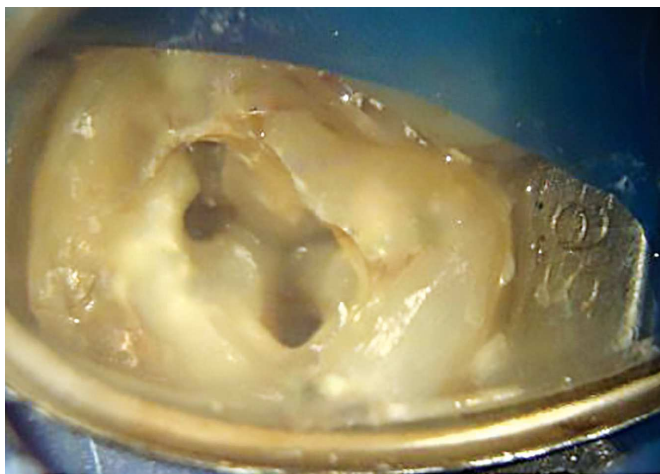
Mesiobuccal root canals, distobuccal canal and second palatal root canals were explored with manual #10 K-files (Dentsply Maillefer, Ballaigues, Switzerland) along their entire length. The palatal root canal was explored with a manual #15 K-file (Dentsply Maillefer, Ballaigues, Switzerland). During initial instrumentation of the mesiobuccal root canal and distobuccal root canal, a #10 K-file (Dentsply Maillefer, Ballaigues, Switzerland) was used. For the two palatal root canals, a #15 K-file (Dentsply Maillefer, Ballaigues, Switzerland) was taken to length. After using an electronic apex locator (Root ZX II, J. Morita, Kyoto, Japan) to confirm and estimate the working length for the canals. A #2 gates glidden (Dentsply Maillefer, Ballaigues, Switzerland) was used to remove the dentin triangle and to prepare the cervical third of the mesiobuccal, distobuccal and the two palatal root canals which were prepared with a Reciproc R25 file (VDW, Munich, Germany) to the total length of the root canals. For the palatal

root canal, the crown-down technique was used for cleaning and shaping. Gates glidden (Dentsply Maillefer, Ballaigues, Switzerland) sizes #3 and #2 were used in the coronal third of the canal, while the middle and apical thirds were prepared with Reciproc R40 (VDW, Munich, Germany) to the total length of the root canal.

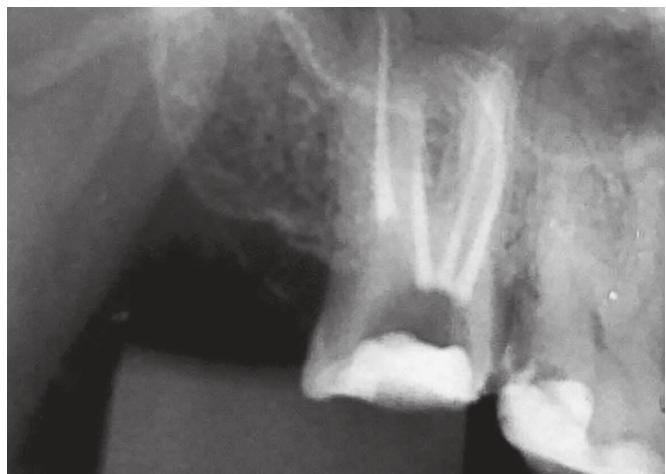
Final irrigation with EDTA was carried out for five minutes to remove the smear layer, exposing the dentinal tubules, apical ramifications, apical deltas or side canals. Gutta percha compatible with Reciproc instruments were selected for root canal filling (VDW, Munich, Germany). Final irrigation and aspiration with sodium hypochlorite were performed to remove the chelating substance. Filling was performed by means of the lateral condensation technique with AH Plus sealer (Dentsply Maillefer, Ballaigues, Switzerland). Finally, a temporary restoration with composite resin was placed over the access opening, and a final radiograph taken (Fig 3). The patient was then referred to final restoration.

## Discussion

This case report highlighted the unusual anatomy of a maxillary second molar with two palatal



**Figure 2.** Image of microscopic visualization allowing visualization of the two root canals in the palatal root.



**Figure 3.** Final radiograph showing all the canals along its entire length. Note that the two palatal root canals have an independent path.

root canals. Most of the literature reviews describe maxillary second molars to have three roots with three or four root canals.<sup>4-9</sup> The prevalence of maxillary second molars with two root canals is very rare.<sup>17,18,19</sup> The literature is also scarce regarding the presence of two separate palatal root canals, as reported in this clinical case.

One of the main tools used by most clinicians and specialists during endodontic treatment is conventional or digital radiograph, which helps the professional from diagnosis to short observation of the clinical case. However, two-dimensional images and overlay of anatomical structures are limitations of this method.<sup>7,18</sup>

Dental cone-beam computed tomography (CBCT) has been used as supplementary examination. It is extremely valuable to aid diagnosis of pathologies or diseases that are not always evident to traditional dental X-rays.<sup>12</sup> CBCT provides tridimensional visualization and an accurate photograph of the inner morphology of the entire tooth to be treated in several section planes.<sup>12,13,18-22</sup> However, due to cost and radiation doses, this examination is not required in all endodontic treatment cases.

Another clinical tool commonly used by clinicians, especially endodontists, is the use of the surgical operating microscope which provides better luminosity and also better operative access to the inner morphology of the tooth, thus favoring a more accurate exploration of the pulp chamber floor, facilitating the procedures to be performed. It also helps to identify

pulp calcifications or atresia more accurately, detect the presence of micro fractures, identify isthmus, achieve coronary access, prevent iatrogenesis and unnecessary dentin removal, so that the root canal can be properly operated and instrumented.<sup>23,24</sup>

In this case report, the use of the surgical operating microscope was essential for identification of the second palatal canal, since this tooth is present in 0.4% to 1.4% of second molars.<sup>15-19</sup> Ashraf et al<sup>25</sup> and Ramasamy<sup>26</sup> reported cautious management of a maxillary second molar with two palatal root canals for diagnosis and treatment. Patel and Patel<sup>27</sup> reported two cases of second maxillary molars with two palatal root canals. The authors emphasize that special attention should be given during endodontic treatment, with diagnosis reached with radiographic images of excellent quality at different angles, exploring the pulp chamber floor.

While these variations present low incidence, it is important for clinicians to be aware of this unusual morphology. This can give support to clinicians during diagnosis and treatment planning of maxillary molars, so as to avoid incomplete preparation of the root canal system and further reduce the chances of failure.<sup>28,29</sup>

## Conclusion

This case report shows an unusual case of maxillary second molar with two palatal root canals with independent paths. With the visual magnification of the optical microscope it was possible to assess and manage the root canal.

## References

1. Sidow SJ, West LA, Liewehr FR, Loushine RJ. Root canal morphology of human maxillary and mandibular third molars. *J Endod.* 2000;26:675-8.
2. Vertucci FJ. Root canal morphology and its relationship to endodontic procedures. *Endod Top.* 2005;10:3-29.
3. Weine FS, Healey HJ, Gerstein H, Evanson L. Canal configuration in the mesiobuccal root of the maxillary first molar and its endodontic significance. *Oral Surg Oral Med Oral Pathol.* 1969 Sept;28(3):419-25.
4. Cleghorn BM, Christie WH, Dong CC. Root and root canal morphology of the human permanent maxillary first molar: a literature review. *J Endod.* 2006 Sept;32(9):813-21.
5. Zheng QH, Wang Y, Zhou XD, Wang Q, Zheng GN, Huang DM. A cone-beam computed tomography study of maxillary first permanent molar root and canal morphology in a Chinese population. *J Endod.* 2010 Sept;36(9):1480-4.
6. Kim Y, Lee SJ, Woo J. Morphology of maxillary first and second molars analyzed by cone-beam computed tomography in a Korean population: variations in the number of roots and canals and the incidence of fusion. *J Endod.* 2012 Aug;38(8):1063-8.
7. Patel S, Dawood A, Whaites E, Pitt Ford T. New dimensions in endodontic imaging: part 1. Conventional and alternative radiographic systems. *Int Endod J.* 2009 Jun;42(6):447-62.
8. Alavi AM, Opananon A, Ng YL, Gulabivala K. Root and canal morphology of Thai maxillary molars. *Int Endod J.* 2002 May;35(5):478-85.
9. Kullid JC, Peters DD. Incidence and configuration of canal systems in the mesiobuccal root of maxillary first and second molars. *J Endod.* 1990 Jul;16(7):311-7.
10. Buhrlay LJ, Barrows MJ, BeGole EA, Wenckus CS. Effect of magnification on locating the MB2 canal in maxillary molars. *J Endod.* 2002 Apr;28(4):324-7.
11. Kottoor J, Velmurugan N, Sudha R, Hemamalathi S. Maxillary first molar with seven root canals diagnosed with cone-beam computed tomography scanning: a case report. *J Endod.* 2010 May;36(5):915-21.
12. Badole GP, Warhadpande MM, Shenoi PR, Lachure C, Badole SG. A rare root canal configuration of bilateral maxillary first molar with 7 root canals diagnosed using cone-beam computed tomographic scanning: a case report. *J Endod.* 2014 Feb;40(2):296-301.
13. Peikoff MD, Christie WH, Fogel HM. The maxillary second molar: variations in the number of roots and canals. *Int Endod J.* 1996 Nov;29(6):365-9.
14. Shojaeian S, Ghoddsi J, Hajian S. A case report of maxillary second molar with two palatal root canals and a furcal enamel pearl. *Iran Endod J.* 2013 Winter;8(1):37-9.
15. Baratto-Filho F, Fariniuk LF, Ferreira EL, Pecora JD, Cruz-Filho AM, Sousa-Neto MD. Clinical and macroscopic study of maxillary molars with two palatal roots. *Int Endod J.* 2002 Sept;35(9):796-801.
16. Jafarzadeh H, Javidi M, Zarei M. Endodontic retreatment of a maxillary second molar with three separate buccal roots. *Aust Endod J.* 2006 Dec;32(3):129-32.
17. Shin SJ, Park JW, Lee JK, Hwang SW. Unusual root canal anatomy in maxillary second molars: two case reports. *Oral Surg Oral Med Oral Pathol Oral Radiol Endod.* 2007 Dec;104(6):e61-5.
18. Deveaux E. Maxillary second molar with two palatal roots. *J Endod.* 1999;25(8):571-3.
19. Matos HRM, Mastroianni LB, Angelim-Dias A. In vitro study of the morphology of internal lower second molars. *RSBO.* 2014;11(2):172-7.
20. Chandra SS, Rajasekaran M, Shankar P, Indira R. Endodontic management of a mandibular first molar with three distal canals confirmed with the aid of spiral computerized tomography: a case report. *Oral Surg Oral Med Oral Pathol Oral Radiol Endod.* 2009 Oct;108(4):e77-81.
21. Lee SJ, Jang KH, Spangberg LS, Kim E, Jung IY, Lee CY, et al. Three-dimensional visualization of a mandibular first molar with three distal roots using computer-aided rapid prototyping. *Oral Surg Oral Med Oral Pathol Oral Radiol Endod.* 2006 May;101(5):668-74.
22. Toubes KM, Côrtes MI, Valadares MA, Fonseca LC, Nunes E, Silveira FF. Comparative analysis of accessory mesial canal identification in mandibular first molars by using four different diagnostic methods. *J Endod.* 2012 Apr;38(4):436-41.
23. Villas-Bôas MH, Bernardineli N, Cavenago BC, Marciano M, Del Carpio-Perochena A, Moraes IG, et al. Micro-computed tomography study of the internal anatomy of mesial root canals of mandibular molars. *J Endod.* 2011 Dec;37(12):1682-6.
24. Carvalho MC, Zuolo ML. Orifice locating with a microscope. *J Endod.* 2000 Sept;26(9):532-4.
25. Maggiore F, Jou YT, Kim S. A six-canal maxillary first molar: case report. *Int Endod J.* 2002 May;35(5):486-91.
26. Ashraf H, Dianat O, Hajrezai R, Paymanpour P, Azadnia S. Endodontic treatment of a double-rooted maxillary second molar with four canals: a case report. *Iran Endod J.* 2014 Fall;9(4):304-6.
27. Ramasamy S. A rare clinical phenomenon of four rooted maxillary second molar: a case report. *Saudi J Dent Res.* 2014;5(2):30-2.
28. Patel S, Patel P. Endodontic management of maxillary second molar with two palatal roots: a report of two cases. *Case Rep Dent.* 2012; 2012(2012):590406.
29. Fakhari E, Shokraneh A. A maxillary second molar with two separate palatal roots: a case report. *J Dent (Shiraz).* 2013 Jun;14(2):87-9.
30. Fontana CE, Ibáñez CDM, Davini F, Martin CFM, Rocha DGP, Bueno CES. Endodontic therapy of maxillary second molar showing a unusual internal anatomy. *RSBO.* 2012;9(2):213-7.
31. Kararia N, Kararia V, Mathur M. Endodontic retreatment of a maxillary first molar with two palatal roots and three palatal canals. *J Adv Med Dent Sci.* 2014;2(2):180-3.