

Management of perforating internal root resorption in maxillary central incisor: case report

Élida Boaventura **MENDES**¹
Gustavo Moreira de **ALMEIDA**²
Marcos Roberto dos Santos **FROZONI**¹
Alberto Costa **PORTO JR.**²

DOI: <https://doi.org/10.14436/2358-2545.10.2.073-078.oar>

ABSTRACT

Introduction: Internal root resorption is the progressive destruction of intraradicular dentin as a result of clastic activities. It is usually asymptomatic and discovered by chance on routine radiographic examinations. It is of vital importance to make a correct diagnosis so that the appropriate treatment can be provided because in some cases can result in destruction of the dental element. **Objective:** The aim of this study is to report a case of successful non-surgical management of perforating internal resorption in an maxillary central incisor,

in the middle third of the root. **Materials and Methods:** The treatment was successfully performed with the aid of an operative microscope. The apical third was filled with gutta-percha and epoxy-resin-based sealer and the perforation site it was repaired with mineral trioxide aggregate. **Conclusion:** Clinical findings and periapical radiographs show that the symptoms and signs ceased, and the results were satisfactory at 3-years follow-up with radiographic examination.

Keywords: Root Resorption. Root Canal Obturation. Root Canal Filling Materials. Root Canal Preparation.

How to cite: Mendes EB, Almeida GM, Frozoni MRS, Porto Jr. AC. Management of perforating internal root resorption in maxillary central incisor: case report. *Dental Press Endod.* 2020 May-Aug;10(2):73-8.
DOI: <https://doi.org/10.14436/2358-2545.10.2.073-078.oar>

» The authors report no commercial, proprietary or financial interest in the products or companies described in this article.

» Patients displayed in this article previously approved the use of their facial and intraoral photographs.

Submitted: November 23, 2018. Revised and accepted: February 11, 2019.

¹ Instituto de Pesquisas São Leopoldo Mandic, Programa de Pós-graduação em Odontologia (Campinas/SP, Brazil).

² Faculdade do Centro Oeste Paulista, Curso de Especialização em Endodontia (Ilhéus/BA, Brazil).

Contact address: Élida Boaventura Mendes
Praça José Marcelino, nº 14, sala 1004, Edifício Cidade de Ilhéus
Bairro São Sebastião – CEP: 45.653-754
E-mail: elidabmendes@hotmail.com

Introduction

A successful endodontic treatment depends on the knowledge of the morphology of root canal anatomy and an accurate diagnosis, leading to the safe and correct treatment. Internal resorption is generally asymptomatic and is usually identified by chance on routine radiographs.^{1,2} Post-treatment periodic radiographic follow-up is recommended to monitor the absence of signs and symptoms.³

Traumatic injuries of preodontoblasts and odontoblasts that protect the inner wall of the root dentin are the probable causes of internal root resorption. May be mechanical following dental trauma, orthodontic treatment, chronic inflammation of the pulp and periodontal disease, surgical procedures and excessive pressure of an impacted tooth or tumor.⁴

Internal resorption usually found either in the middle third of the root. Root canal treatment stays the treatment of choice as it eliminates the granulation tissue before the process reaches the periodontal ligament. When root perforation occurs, communications between the root canal system and either periradicular tissues or the oral cavity lead to pulp necrosis and infection and may often reduce the prognosis of treatment.^{5,6}

The operating microscope associated with ultrasonic activation improves the visualization of the surgical site and assists in the removal of granulation tissue. The residual canal space was filled with gutta-percha, and the perforated lesion with mineral trioxide aggregate. The MTA cement is effective in closing pulpal perforations and at the same time ability to stimulate tissue repair.^{7,21}

This case report describes the treatment and 3-year follow-up of a perforating internal resorption that evolved favorably after gutta-percha filling, and the MTA with the aid of operative microscope.

Case Report

A 13-year-old male patient was referred for endodontic evaluation. The main complaint was a fistula in the buccal mucosa region of element 11. He was previously attended by another professional, who reported receiving a patient with a fistula, performed endodontic access and did not follow the treatment because of continuous bleeding.

The medical history was unremarkable. A history

of childhood dental trauma has been reported although the age at which it occurred is not known.

Clinical examination revealed a sinus tract located on the attached gingiva of the maxillary right central incisor, crown color change, coronary fracture and a buccal position in the dental arch. The tooth was sensitive to percussion and palpation and responded negatively to cold pulp testing. Periodontal probing depth and mobility was within normal limits.

Radiographic investigation revealed the presence of internal root resorption in the cervical and middle third of the root and a normal width of the root canal in the apical third in the maxillary right central incisor (Fig 1). The sinus tract was traced with a gutta-percha point Fine Medium (Odous De Deus Ind. e Com Ltda., Belo Horizonte, MG, Brazil), which suggested the point of communication with the root external surface at the middle third with rupture of cementum layer and communication with adjacent periodontal tissues (Fig 2). Radiographic findings suggest thickening of the periodontal ligament space with no destruction of adjacent bony structure. The diagnosis of perforating internal resorption and pulp necrosis was proposed.

Management proposed was nonsurgical root canal treatment. The patient and his parents were fully informed about the treatment procedure and the follow-up examinations, and a written informed consent form was obtained before the treatment procedure commenced.

A standard access cavity was prepared after administration of local anesthesia Lidocaine 2% 1:100.000 (Alphacaine 100®, DFL-Brazil) and rubber dam isolation. Initial exploration of the cervical third of canals was performed with a endodontic explorer and large reabsorption area with granulation tissue severe bleeding was encountered. The canal was then gently irrigated with 2.5% sodium hypochlorite (Fórmula e Ação - São Paulo, Brazil) using a 24G needle connected to a disposable 10-ml syringe with simultaneous aspiration. The root canal was negotiated with a size 10 file c-pilot (VDW, Munich, Germany). During root canal instrumentation, communication between the resorption cavity and the periodontium hindered penetration of files from the apical third of the root canal. The canal was filled

with calcium hydroxide paste (Ultracal XS; Ultradent Products Inc., South Jordan, UT) to control bleeding at the perforation and ensure complete elimination of the granulation tissue (Fig 3).

After 30 days, the remaining granulation tissue was removed with irrigation/aspiration and ultrasonic agitation. The Irrisonic tip (E1-Irrisonic, Helse Dental Technology, Santa Rosa de Viterbo-SP, Brazil) is used to activate the irrigating solution for 30 seconds in the middle third. This made it possible to view with aid microscope Alliance (São Carlos, São Paulo). Access to the apical part of the root canal was achieved using a size 10 file c-pilot (VDW, Munich, Germany) passing beyond the resorption area. Length determination was performed electronically using the Root ZXII (Osada, Japan) and confirmed radiographically. The apical third of the root canal instrumentation was performed manually. The anatomical diameter of the canal was standardized from the initial preparation with size 40 K-files up to #55 by the step-back technique (Maillefer, Ballaigues, Switzerland). The apical third was filled

with gutta-percha and endodontic sealer AHPlus (Dentsply, DeTrey, Konstanz, Germany). The gutta percha point was partially removed using thermo-compactator (Easy Endo, Belo Horizonte, MG). MTA (Angelus, Londrina, Brazil) was inserted with into the resorption area with the aid of absorbent paper points soaked in saline from the middle third to the cervical third. Periapical radiography showed complete filling of the intraradicular space. (Fig 5) The access cavity was sealed with temporary restorative and the tooth was restored with composite resin (Filtek TM Z250 3M ESPE, Sumaré, São Paulo, Brazil) and the patient was referred for definitive restoration.

Results

The clinical evaluations after 1 year (Fig 6), 2 years (Fig 7) and after 3 years (Fig 8) showed satisfied clinical and radiographic result and complete fistula healing. The patient remained asymptomatic during the follow-up period and the treatment was considered successful.

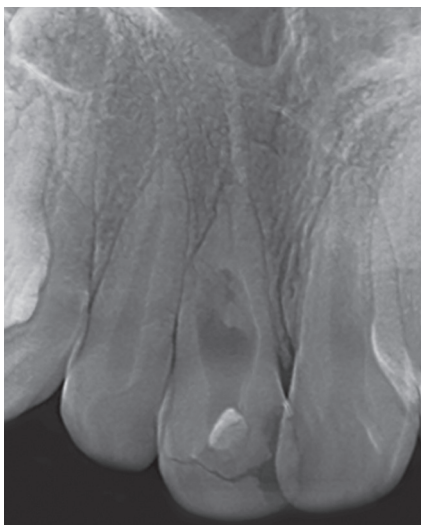

Figure 1. Preoperative periapical radiograph suggesting internal root resorption.

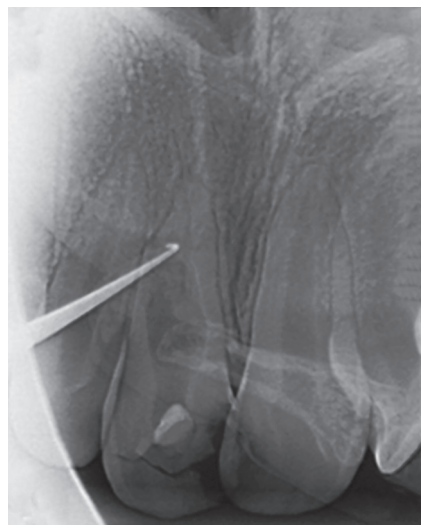

Figure 2. A fistulograph suggesting the communication area with the periodontium.

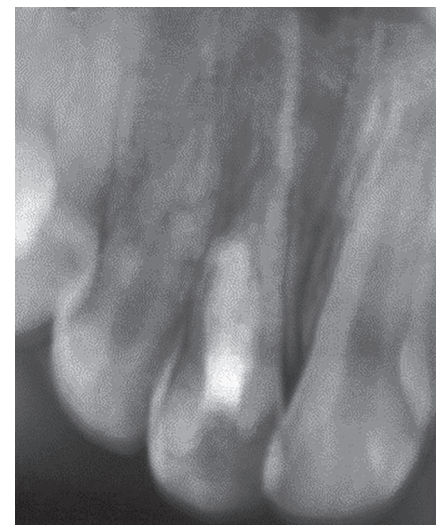

Figure 3. Calcium hydroxide filling the root canal and resorption.

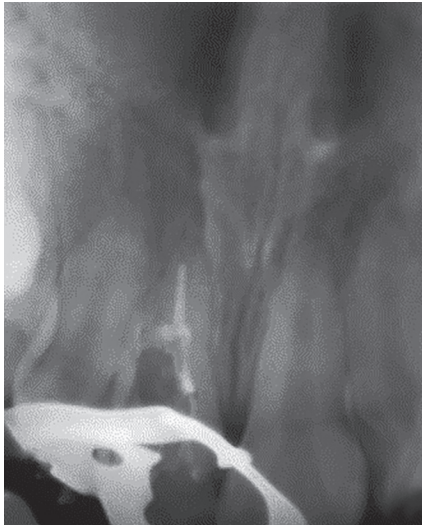


Figure 4. Apical third filling with gutta-percha and endodontic sealer.

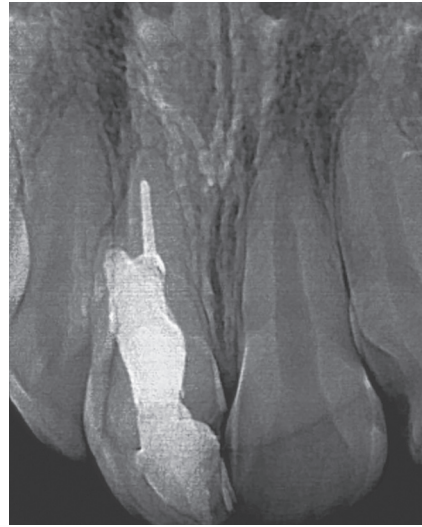


Figure 5. MTA filling the resorption area in the middle and cervical third.

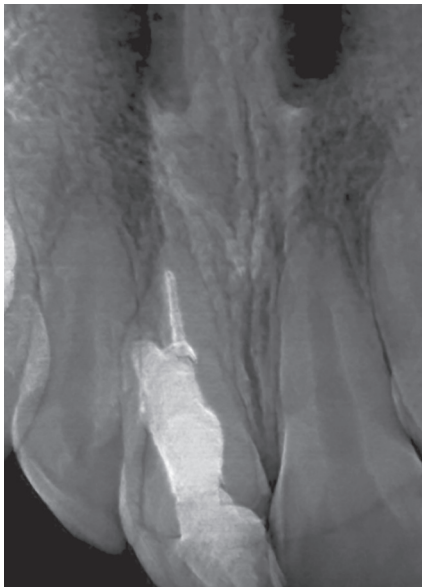


Figure 6. 1-year follow-up.

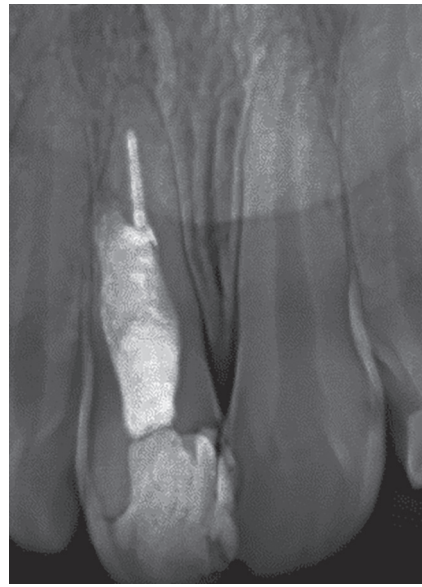


Figure 7. 2-years follow-up.

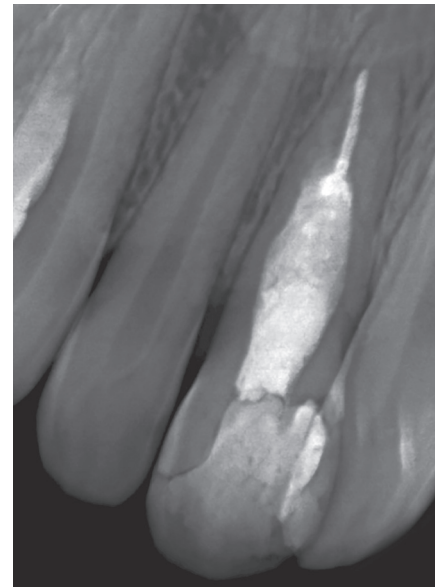


Figure 8. 3-years follow-up.

Discussion

Internal root resorption is the progressive destruction of intraradicular dentin the canal walls as a result of clastic activities due to dental trauma. The loss of odontoblastic layer and predentin initiate the resorption process. Where odontoclasts are in contact with the tooth surface, the characteristic brush border can

be seen facing exposed surface.^{8,9} The maxillary permanent central incisors are the most commonly affected teeth in patients with increased overjet and lip incompetence. A disruption to the blood supply to teeth after dental trauma can cause necrosis.¹⁰ These findings coincide with the reported case of a necrotic central incisor after complete resorption advance.

Internal root resorption is often asymptomatic, and painful symptoms do not appear until an advanced stage of the lesion. Thus, they are usually discovered by chance on routine radiographs. The symptoms may be of acute or chronic apical periodontitis after the entire pulp has undergone necrosis and the pulp space has become infected.^{1,2} As in the reported case, patients do not seek immediate care, only when there is fistula.

Internal root resorption is characterized by the radiographic appearance of an oval shaped enlargement within the pulp chamber and disappearance of the original canal shape in the area of the resorption. The migration of the granulation tissue through the resorptive defect to the external root surface was the cause for destruction of adjacent bony structure. This is difficult to detect as it is superimposed by the intact bone.⁵ This might have been the possible cause why extent of bone loss remained undetected in the present case.

In this clinical case the lesion was identified by periapical radiography though cone-beam computerized tomography is most accurate which enables three-dimensional viewing of resorptive defects caused by internal resorption and to determine the actual extension of root resorption and the number of affected surfaces.¹¹ Failure of the conventional periapical radiographic examination to diagnose periapical lesions does not justify the routine use of CT examinations in endodontic therapy; however, the technique can be used if more information is needed for the management of bone formation.³

From a histologic perspective, internal root resorption is characterized by the presence of highly vascularized granulation tissue. In this case irrigation with approximately 2ml of hypochlorite with ultrasonic agitation was used to remove organic debris through gentle irrigation to keep it within root space.^{12,13,14} To allow visualization of the area to be evaluated operating microscope was been used to facilitate the proper cleaning of the root canal, sectioning of the apical segment of gutta-percha and to assist in correct insertion of the MTA in the resorption area.¹⁵

Historically prolonged use of calcium hydroxide with multiple changes of the dressing has been used in the treatment of resorption inducing the formation of a hard tissue barrier. Andreasen, Farik and Munksgaard (2006)¹⁶ concluded that dentin in contact with calcium hydroxide would show a reduction in fracture strength after a certain period of time. Root filling with MTA would prevent the mentioned weakening of dentin. In another study Kahler, Shetty and Andreasen (2017)¹⁷ concluded that thin and fragile roots could be the cause of fracture rather than the calcium hydroxide dressing. MTA, calcium silicate-based cement, is successfully used to seal perforations because of its biocompatibility, sealing ability and hard tissue formation.^{18,19} In the present case the apical third was filled with gutta-percha, and the perforated lesion was repaired with mineral trioxide aggregate as in the technique reported by Hsien et al (2003).²⁰ Calcium hydroxide dressing was used to enhance debridement of the internal root resorption defect as well as a forming physical-chemical barrier, preventing the reinfection of the root canal, and invagination of the granulation tissue of the area reabsorbed.³

When determining a prognostic for a tooth with internal root resorption, endodontically treated, post-treatment radiographic controls for at least two years should be recommended.²¹ In the present study clinical and radiographic follow-up was conducted for 3 years demonstrating a functional tooth with no endodontic pathosis. The tooth was in function with no discomfort or pain during that time. Finally, treatment was considered successful.

Conclusions

Management of internal root resorption with root perforation and communication between periodontal and pulpal tissue is more difficult. The present study shows though intraoral periapical radiograph proven to be satisfactory and is still an economical and accessible technique readily available to the clinicians for routine treatment procedures. Treatment with appropriate technique and material as mineral trioxide aggregate for treating such defects is of great boon in conserving the tooth and preventing extractions.

References

1. Fuss Z, Tsesis I, Lin S. Root resorption: diagnosis, classification and treatment choices based on stimulation factors. *Dent Traumatol.* 2003;19(4):175-82.
2. Palekar A, Maria R, Jindal V. Perforating internal resorption: Review and case reports. *J Pierre Fauchard Acad.* 2008;22(4):147-51.
3. Patel S, Ricucci D, Durak C, Tay F. Internal root resorption: a review. *J Endod.* 2010;36(7):1107-21.
4. Andreasen FM, Kahler B. Pulpal response after acute dental injury in the permanent dentition: clinical implications-a review. *J Endod.* 2015;41(3):299-308.
5. Altundasar E, Demir B. Management of a perforating internal resorptive defect with mineral trioxide aggregate: a case report. *J Endod.* 2009;35(10):1441-4.
6. Neville BW, Damm DD, Allen CM, Bouquot JE. Anormalidades dentárias: Perda de estrutura dentária pós desenvolvimento. In: *Patologia Oral & Maxilofacial.* 4ª ed. Rio de Janeiro: Guanabara Koogan; 2016. Cap. 2, p. 142-44.
7. Gayathri P, Pandey RK, Jain E. Management of internal resorption of central incisor using hybrid technique. *BMJ Case Reports.* 2014 Jan 28;2014:bcr2013201570.
8. Tronstad L. Root resorption: Etiology, terminology and clinical manifestations. *Endod Dent Traumatol.* 1988 Dec;4:241-52.
9. Vaananen K. Mechanism of osteoclast mediated bone resorption-rationale for the design of new therapeutics. *Adv Drug Deliv Rev.* 2005;25(7):959-71.
10. Al-Nazhan S, Andreasen JO, Al-Bawardi S, Al-Rouq S. Evaluation of the effect of delayed management of traumatized permanent teeth. *J Endod.* 1995;21(7):391-3.
11. Estrela C, Bueno MR, De Alencar AH, Mattar R, Valladares Neto J, Azevedo BC, et al. Method to evaluate inflammatory root resorption by using cone beam computed tomography. *J Endod.* 2009;35(11):1491-7.
12. Haapasalo M, Endal U. Internal inflammatory root resorption: the unknown resorption of the tooth. *Endod Topics.* 2006;14:60-79.
13. Almeida G, Marques E, Martin AS, Bueno CES, Nowakowski A, Cunha RS. Influence of irrigating solution on postoperative pain following single-visit endodontic treatment: randomized clinical trial. *J Can Dent Assoc.* 2012;78:c84.
14. Ulusoy OI, Savur IG, Alaçam T, Çelik B. The effectiveness os various irrigation protocols on organic tissue removal from simulated internal resorption defects. *Int Endod J.* 2018;51(9):1030-6.
15. Nunes E, Silveira FF, Soares JA, Duarte MAH, Soares SMCS. Treatment of perforating internal root resorption with MTA: a case report. *J Oral Sci.* 2012;54(1):127-31.
16. Andreasen JO, Munksgaard EC, Bakland LK. Comparison of fracture resistance in root canals of immature sheep teeth after filling with calcium hydroxide or MTA. *Dent Traumatol.* 2006;22(3):154-6.
17. Kahler SL, Shetty S, Andreasen FM, Kahler B. The effect of long-term dressing with calcium hydroxide on the fracture susceptibility of teeth. *J Endod.* 2017;44(3):464-9.
18. Lee SJ, Monsef M, Torabinejad M. The sealing ability of a mineral trioxide aggregate for repair of lateral root perforations. *J Endod.* 1993;19(11):541-4.
19. Torabinejad M, Chivian N. Clinical applications of mineral trioxide aggregate. *J Endod.* 1999;25:197-205.
20. Hsien HC, Cheng YA, Lee YL, Lan WH, Lin CP. Repair of perforating internal resorption with mineral trioxide aggregate: a case report. *J Endod.* 2003;29(8):538-9.
21. Consolaro A, Consolaro RB, Prado RF. Reabsorção interna: uma pulpopatia inflamatória. In: *Reabsorções dentárias nas especialidades clínicas.* 3ª ed. Maringá: Dental Press; 2012. p. 315-43.