

Minimally invasive rehabilitation of an extensively damaged vital tooth using the CAD/CAM system

Alana Pinto Caroso **Souza**¹

Renato Piai **Pereira**²

Adriana Oliveira **Carvalho**³

<https://doi.org/10.14436/2447-911x.17.3.100-113.oar> • Submitted: June 21, 2019 • Revised and accepted: July 04, 2020

(1) Universidade Estadual de Campinas, Faculdade de Odontologia de Piracicaba, Postgraduate Program in Materials Dental (Piracicaba/SP, Brazil). (2) Universidade Estadual do Sudoeste da Bahia, Dentistry Department (Jequié/BA, Brazil). (3) Universidade Estadual de Feira de Santana, Dentistry Department (Feira de Santana/BA, Brazil).

How to cite: Souza APC, Pereira RP, Carvalho AO. Minimally invasive rehabilitation of an extensively damaged vital tooth using the CAD/CAM system. J Clin Dent Res. 2020 Sept-Dec;17(3):100-13. **Contact address:** Alana Pinto Cardoso Souza. Rua Dalva Ribeiro, nº 164. Bairro São José. Jequié-BA. CEP: 45.203-152. E-mail: alanacaroso@gmail.com. *The authors report no commercial, proprietary or financial interest in the products or companies described in this article. Patients displayed in this article previously approved the use of their facial and intraoral photographs.*

ABSTRACT

Objective: The restoration of vital teeth with extensive loss of coronal structure is a challenge for modern dentistry. The most common treatment for this type of case is the use of mechanical retention through the use of intraradicular retainers such as glass fiber posts after endodontic therapy, followed by the fabrication of an indirect restoration. However, more recent approaches have proposed more conservative treatments, due to advances in Adhesive Dentistry combined with the use of minimally invasive preparations, which prevented a reduction in the fracture resistance of dental remnants. **Methods:** This article describes a clinical case report involving the rehabilitation of an extensively damaged vital tooth. A 63-year-old female patient, on clinical and radiographic examination, an extensive coronary fracture of dental unit 17 was

found without pulp and/or periodontal involvement. **Results:** A minimally invasive indirect restoration was performed with a lithium disilicate fabricated with the CAD/CAM system in a single visit without the need for additional wear and especially without the use of intracanal post. The proposed treatment was followed up for 2 years and showed good evolution. **Conclusion:** Minimally invasive indirect restorations fabricated with the CAD/CAM system combined with an adequate adhesive technique are an effective, conservative and aesthetic alternative to restore extensively damage vital posterior teeth.

KEYWORDS

Ceramics. Tooth Crown. Dental Restoration, Permanent. Esthetics, Dental

INTRODUCTION

The planning of restorative treatment of teeth that have lost a large part of their structure due to caries, fracture, wear or a combination of these factors is a challenge for the clinician. Traditionally, the most common approach to this type of tooth remnant has been endodontic treatment to allow the use of an intraradicular retainer and, consequently, to obtain additional retention for a possible indirect restoration.^{1,2}

There have been great advances in dentistry in recent years with regard to mechanical retention and adhesive techniques, which have allowed the preservation of healthy tissues through the use of minimally invasive preparations. Studies have shown that preservation of the healthy tooth structure and the use of an adequate adhesive technique are essential factors for the success of restorative treatment.³

Furthermore, the evolution of digital technology is transforming the day-to-day in Dentistry, especially in Prosthodontics. When talking about dental prosthesis, great advances can be noted, such as the use of CAD/CAM (computer-aided design/computer-aided manufacturing) system. Restorations produced by the CAD/CAM system have some advantages compared to conventional techniques: the reduced manufacturing time, the restorative material thickness precise control, as well as better quality of restorative materials.⁴

The aim of this article was to describe a case report of an extensively damaged vital tooth rehabilitation using a minimally invasive indirect lithium disilicate restoration fabricated by CAD/CAM system.

CASE REPORT

A 63-year-old female patient presented with a fractured posterior tooth. The clinical and radiographic examination revealed an extensive coronary fracture of tooth 17 in the absence of pulp and/or periodontal involvement (Fig 1). After the patient had read and signed the free informed consent form stating the risks

and benefits of treatment and providing permission for use of the images without identification for scientific publication, rehabilitation therapy was initiated, which consisted of the steps described below. This case report was approved by the institutional research ethics committee (CAAE: 94010518.4.0000.0055).

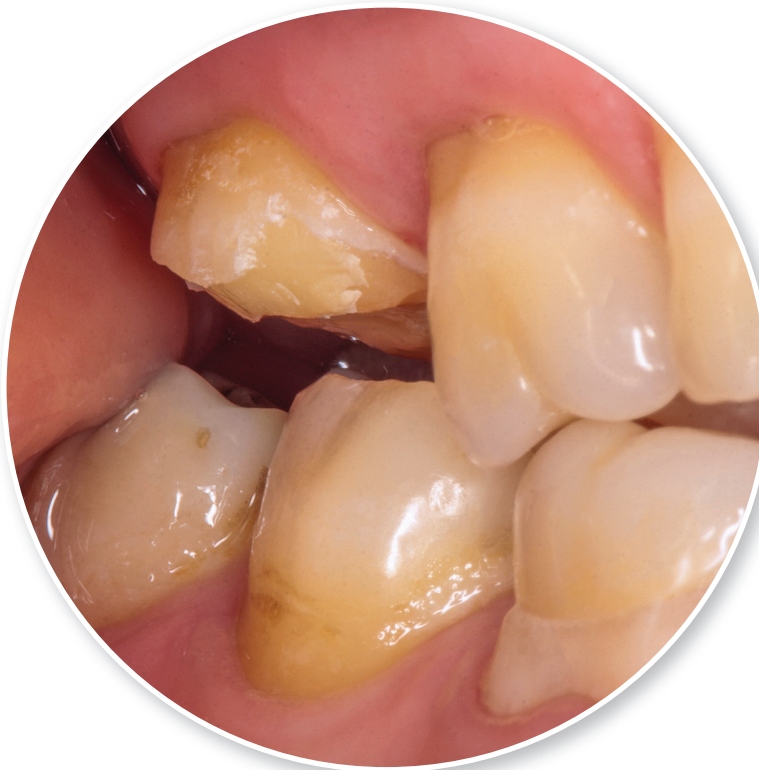

Figure 1: Preoperative view on tooth 17 with coronary fracture.

For tooth management, only the surface of the tooth remnant was polished using a fine-grained and slightly tapered shape bur coupled to an electric micromotor (Fig 2). Next, Immediate Dentin Sealing (IDS) was performed with a two-step self-etch adhesive (Clearfill SE Bond, Kuraray Co., Osaka, Japan) using a LED curing light (Valo; Ultradent Products, Inc., South Jordan, Utah, USA). After this procedure, a new finish was made throughout the enamel to remove any residue of the adhesive system over the enamel margin, which could impair final bonding.

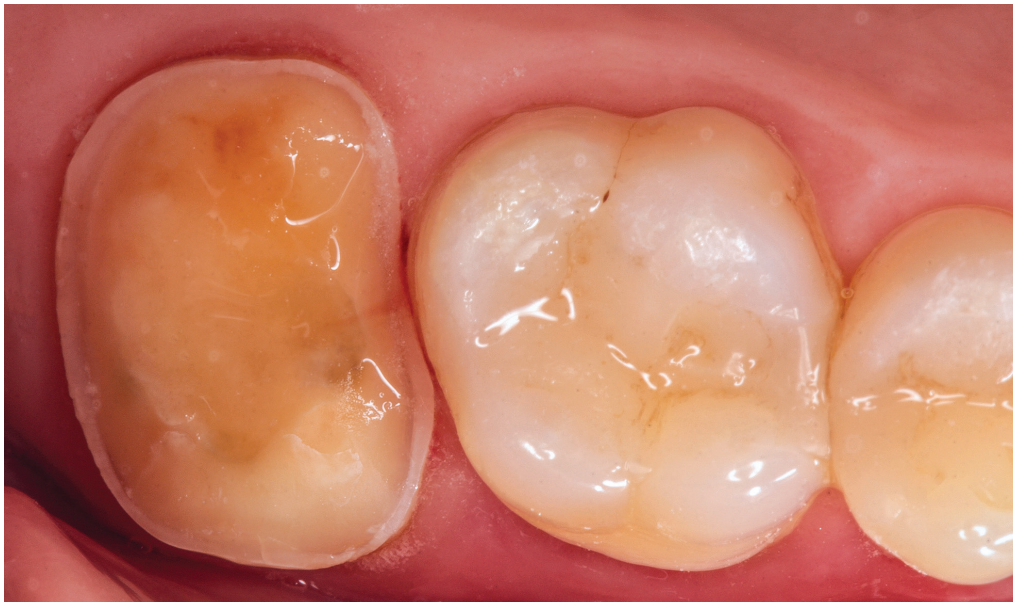

Figure 2: Molar prepared for an overlay with dentin sealing.

After tooth preparation, a #000 retraction cord (Ultrapak, Ultradent Products) was inserted, and titanium dioxide (Vita Cerec Powder Scan Spray, VITA Zahnfabrik, Bad Säckingen, Germany) was applied as contrast powder to the units to be scanned. The intraoral scans of the prepared tooth, antagonists and state of occlusion were obtained with a Cerec AC intraoral scanner (CEREC AC, Sirona Dental Systems, Bensheim, Germany) (Fig 3). The overlay was fabricated using the MCXL milling unit of the

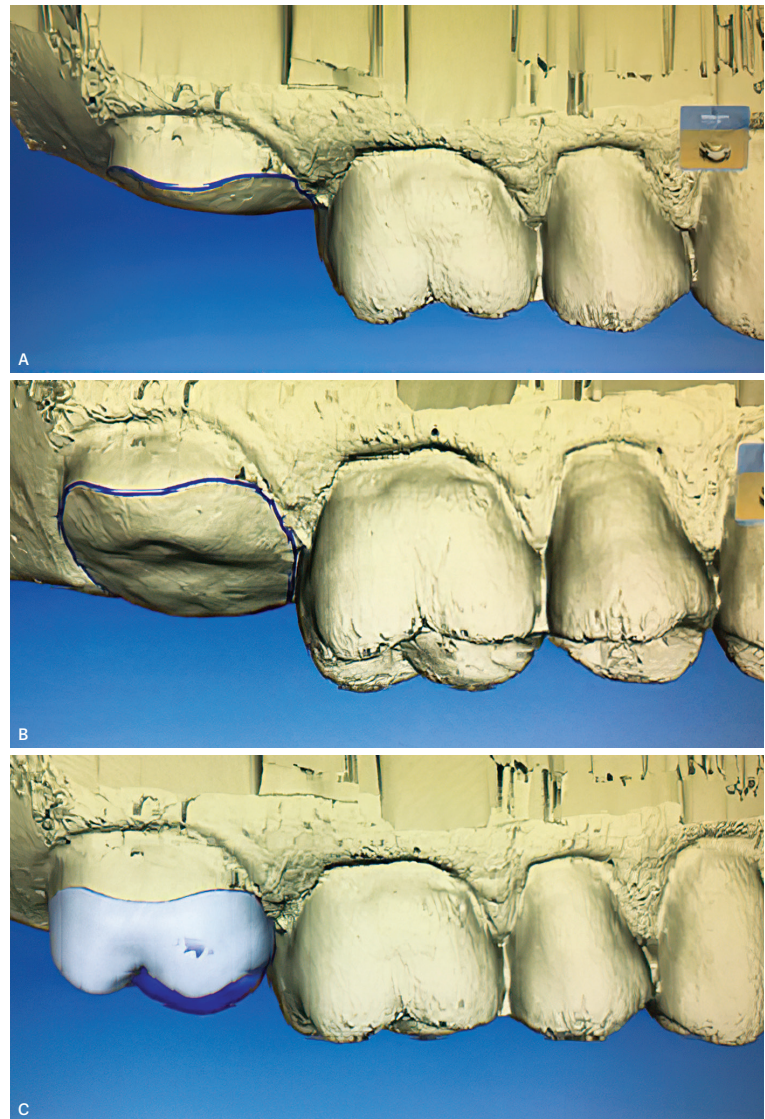


Figure 3: Computer Aided Design (CAD). **A)** Side view. **B)** Marginal outline of the preparation. **A)** Design of the restoration.

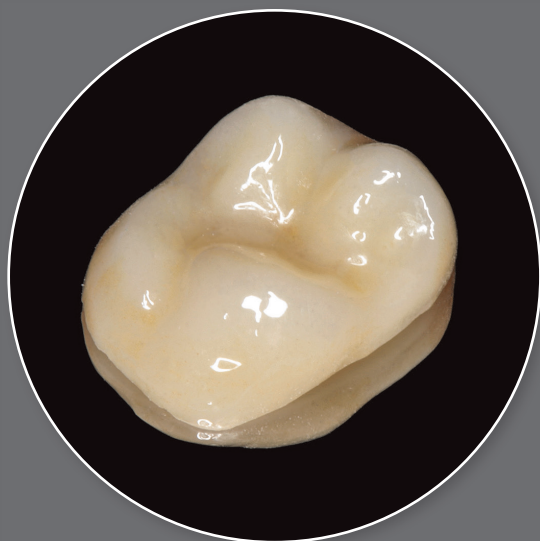


Figure 4: Overlay The overlay ready for cementation.

CAD/CAM system (CEREC MCXL, Sirona, Bensheim, Germany) and a lithium disilicate ceramic block (IPS e.max CAD, Ivoclar Vivadent, Schaan, Liechtenstein). The tooth color was selected using a scale for e.max (Ivoclar Vivadent, Amherst, NY, USA), color A3.5 was chosen for the middle third and A2 for the incisal and occlusal thirds. After milling, the overlay was sintered in a furnace (Programat CS2, Ivoclar Vivadent, Schaan, Liechtenstein) (Fig 4).

After evaluation of the overlay's performance, absolute isolation was performed and the inner surface of the overlay was prepared with 10% hydrofluoric acid (Dentsply, Milford, MA, USA) for 20 seconds. After abundant rinsing with water and drying, 37% phosphoric acid (Dentsply, Petrópolis, RJ, Brazil) was spread on the surface with a microbrush, followed by rinsing and drying. Finally, silane (RelyX, Ceramic Primer, 3M/ESPE, St. Paul, MN, USA) was applied for 20 seconds.

In the tooth, 37% phosphoric acid was applied for 30 seconds for selective acid-etching of the enamel, followed by rinsing with water and air-drying. A two-step self-etch adhesive system (Clearfill SE Bond, Kuraray Co., Osaka, Japan) was applied according to the manufacturer's instructions. The adhesive (bond) was also applied internally to the overlay. The overlay was

placed with dual-cure resin cement (Variolink N, Ivoclar Vivadent, Schaan, Liechtenstein) (Fig 5). Excess was removed with a brush, spatula and dental floss, followed by light-curing for 40 seconds on each side. The margins were finished and polished with porcelain polishing points (Flexicups, Cosmedent, Chicago, IL, USA), and occlusal contacts were checked with carbon paper (AccuFilm, Parkell, Inc., Edgewood, NY, USA) in normal maximum

intercuspatation, right/left laterality, and protrusion (Fig 6).

The patient returned for assessment after 6 months and an orthodontic appliance was observed in the restored unit. The restorative treatment of tooth 17 was followed up clinically for 2 years and it can be seen radiographically that the overlay remained well adapted to the dental remnant (Fig 7).

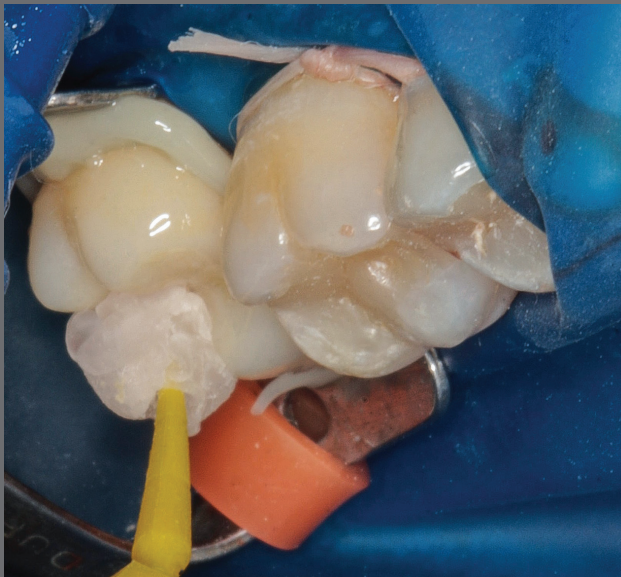

Figure 5: Cementation of overlay.

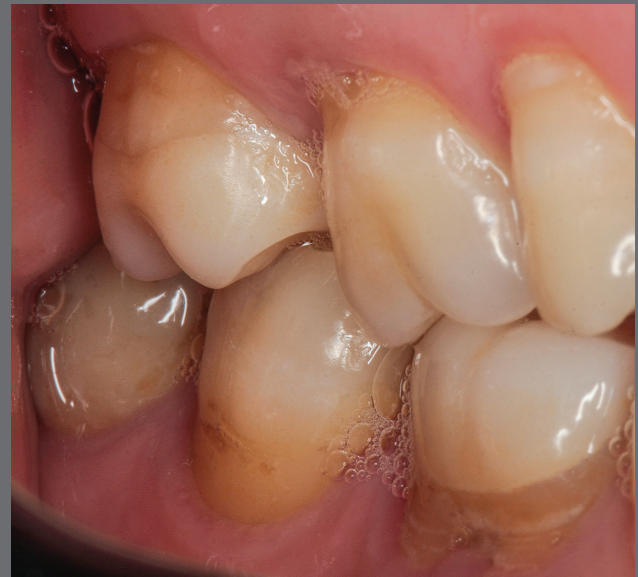

Figure 6: Final restoration - Overlay after cementation.

DISCUSSION

Traditionally, elective endodontic treatment has been indicated for prosthetic purposes of teeth with extensive coronal loss in order to allow root canal instrumentation and the placement of a post, which would increase retention between the coronary restorative material and the root remnant.⁵ This

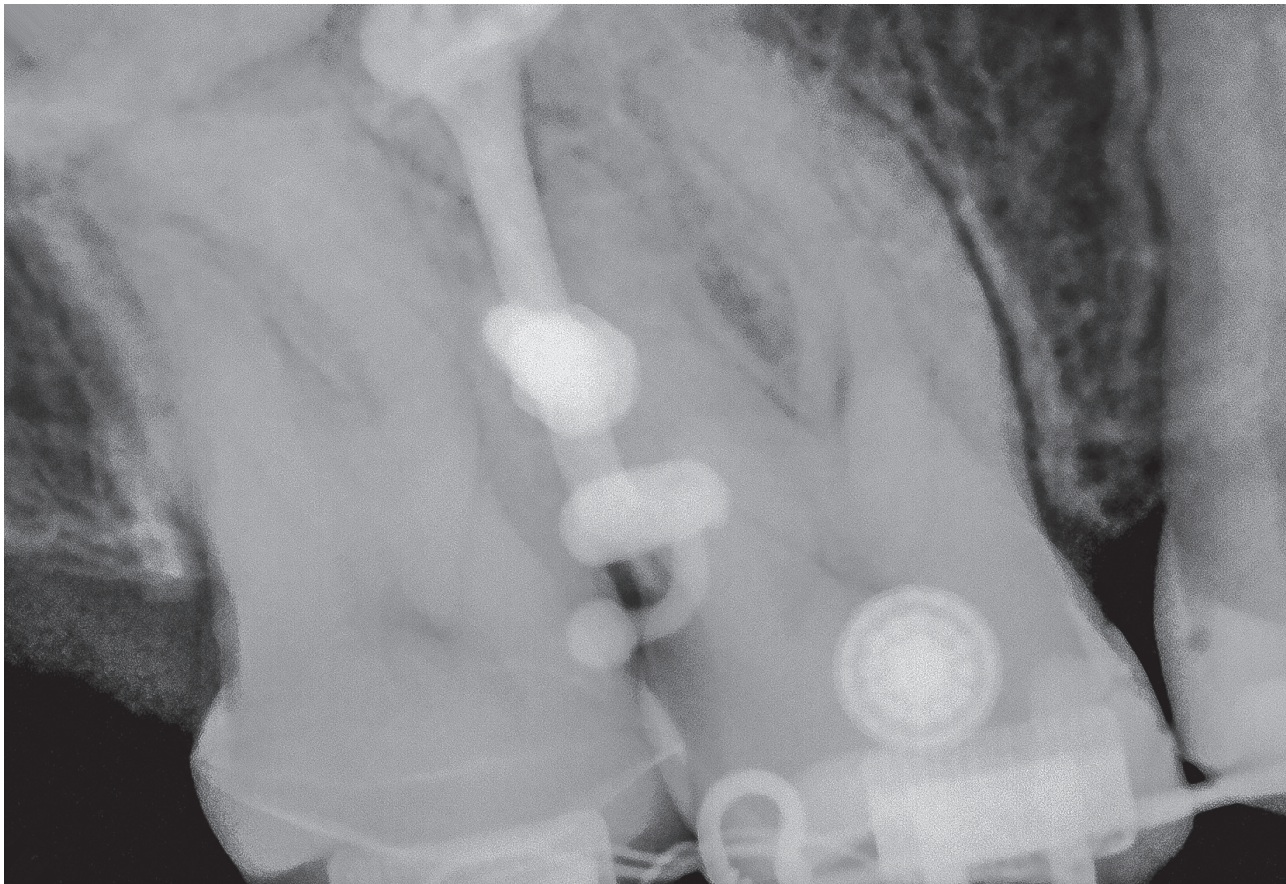


Figure 7: Radiograph of unit 17 after 2 years.

devitalization for prosthetic purposes has been questioned since flexibility and fracture resistance are increased when the tooth is hydrated by vital pulp.^{3,6} In addition, tooth devitalization is associated with some complications. Although the rate is relatively low, there is a risk of endodontic failure, perforation, stress concentration in dentin, and root fracture^{1,7}. Performing an endodontic access interferes with the biomechanical integrity of the tooth since preservation of the radicular and coronal tooth structure is one of the most important factors to prevent fatigue,^{8,9} and this can compromise the long-term performance of the restored tooth. It was therefore chosen not to perform endodontic treatment in order to preserve as much as possible the healthy tooth structure.

The use of post-reinforcement was believed to increase the strength of the tooth-crown set. However, a recent study¹⁰ showed that the use of posts in endodontically treated teeth resulted in a survival that was the same or lower

than that of teeth treated endodontically without a post. In addition, the former has a limited prognosis¹¹ as the post-reinforcement can increase the risk of tooth fracture, especially cast posts and cores that generate high stress and can cause catastrophic root fractures. On the other hand, pre-fabricated glass fiber retainers behave similarly to the tooth¹² thanks to adhesive dentistry and because their elasticity module is similar to that of dentin.¹³ However, the use of a pre-fabricated glass fiber post is disadvantageous since the remnant tooth structure is lost during preparation of the tooth.¹¹

Advances in adhesive dentistry have enabled indirect restorations in endodontically treated teeth without the need for a glass fiber post or cast post and core, to guarantee retention of the restoration.¹⁴ This less invasive alternative consists of the fabrication of a restoration using a monoblock technique, called endocrown.¹⁵ In most cases, failures in this type of restoration

are characterized by non-catastrophic fractures involving the restorative material and are easily resolved by replacing the crown.^{11,16} In the present case, this type of treatment was not indicated since endodontic treatment was not performed.

In the case of extensively damaged vital teeth without an indication for endodontic treatment, except for reasons of crown retention, a new alternative is sought to restore these teeth based on the minimally invasive technique and new knowledge about the improvement of adhesion. In the present case, only regularization of the occlusal surface was chosen without creating a traditional retention preparation, thus avoiding the unnecessary removal of tissue and the consequent reduction in fracture resistance of the tooth structure.^{11,16,17} This was possible because the tooth was a molar, which has a large area for adhesion. Less invasive preparations better protect the underlying tooth remnant but displacement of the

overlay may occur more easily.

The ferrule has the function of avoiding displacement of the overlay and increasing the fracture resistance of the tooth.^{7,17} In the present case, the ferrule was not made with the intention of avoiding the irreversibility of tooth wear once it was performed and, in this way, preserving the healthy tooth structure, in addition to maintaining the entire margin of restoration in enamel. However, a small chamfer could have been fabricated to facilitate positioning of the restoration in the cavity. In addition, molars are more subjected to axial than to oblique loads. Posterior teeth are subjected to occlusal loads parallel to the long axis of the tooth and to essentially compressive masticatory loads.^{12,14} Thus, a posterior tooth like a molar is less likely to undergo displacement or any movement of the indirect restoration under the action of occlusal loads when compared to an anterior tooth.

The indirect restoration was fabricated using the CAD/CAM system,

which permitted rapid planning and execution. Among the available ceramics, lithium disilicate was chosen as the material because it combines mechanical resistance and adequate esthetics. Since the tooth had an onlay replacing the palatine cusps and the buccal cusps were lost due to a trauma, an overlay preparation was necessary with full coverage of the cusps without cervical extension. Crown preparation was not done since the tooth was a second upper molar that does not appear in the patient's smile line. The preparation was performed according to the principles of anterior tooth preparation for ultra-thin veneers and preparations for occlusal veneers in posterior teeth in patients with severe occlusal erosions.^{18,19} These occlusal veneers are extracoronal occlusal restorations that require a simple preparation guided by the remaining anatomical features.

Having a substrate that responds well to adhesion and that maintains this condition for a long period is a fundamental

factor for minimally invasive restorative treatment.^{20,21} Adhesion to enamel is known to be more favorable and stable than adhesion to dentin or composite resin.²¹ In the present case, this adhesion was achieved using a selective enamel etching technique in which 37% phosphoric acid is applied to the enamel before the use of a self-etch adhesive system. For adequate adhesion to dentin, the protocol introduced by Dietschi and Spreafico²² and improved by Magne et al.²³ has been suggested, in which IDS is used (a procedure that proposes to seal the freshly cut dentin with an adhesive system immediately after preparation and before impression making), combined with an adhesive material (resin cement or heated composite resin) as luting agent.^{18,22-24} This approach allows to improve the adhesive durability of the interface between the restorative material and tooth substrate.²⁵

Despite the favorable result of the restorative treatment employed, further clinical case studies and follow-up for a longer period of time are necessary.

CONCLUSION

Minimally invasive indirect restorations made by the CAD/CAM system combined with an adequate adhesive technique proved to be an effective, conservative and aesthetic alternative to restore extensively damaged vital posterior teeth.

REFERENCES

- Jiang W, Bo H, Yongchun G, LongXing N. Stress distribution in molars restored with inlays or onlays with or without endodontic treatment: a three-dimensional finite element analysis. *J Prosthet Dent*. 2010 Jan;103(1):6-12.
- Carvalho AO, Bruzi G, Anderson RE, Maia HP, Giannini M, Magne P. Influence of adhesive core buildup designs on the resistance of endodontically treated molars restored with lithium disilicate CAD/CAM crowns. *Oper Dent*. 2016 Jan-Feb;41(1):76-82.
- Hilgert LA, Schweiger J, Beuer F, de Andrada MAC, Araújo E, Edelhoff D. Odontologia restauradora com sistemas CAD/CAM: o estado atual da arte Parte I - Princípios de utilização. *Clin Int J Braz Dent*. 2009 July-Sept;5(3):294-303.
- Alleman DS, Nejad MA, Alleman DS. The protocols of biomimetic restorative dentistry: 2002 to 2017. *Inside Dent*. 2017 June;13(6).
- Mazaro JVQ, dos Santos AB, Zavanelli AC, de Mello CC, Lemos CAA, Gennari Filho H. Avaliação dos fatores críticos para a seleção e aplicação clínica dos pinos de fibra: relato de caso clínico. *Rev Odontol Araçatuba*. 2014 July-Dec;35(2):26-36.
- Soares CJ, Santana FR, Silva NR, Preira JC, Pereira CA. Influence of the endodontic treatment on mechanical properties of root dentin. *J Endod*. 2007 May;33(5):603-6.
- Baba NZ, Goodacre CJ. Restoration of endodontically treated teeth: contemporary concepts and future perspectives. *Endod Topics*. 2014;31(1):68-83.
- McCarthy R. The application of indirect composite onlays in the restoration of severely broken down posterior teeth. *J Ir Dent Assoc*. 2015 Dec;61(6):309-12.
- Torbjörner A, Fransson B. Biomechanical aspects of prosthetic treatment of structurally compromised teeth. *Int J Prosthodont*. 2004 Mar-Apr;17(2):135-41.
- Ploumaki A, Bilkhair A, Tuna T, Stampf S, Strub JR. Success rates of prosthetic restorations on endodontically treated teeth: a systematic review after 6 years. *J Oral Rehabil*. 2013 Aug;40(8):618-30.
- Magne P, Carvalho AO, Bruzi G, Anderson RE, Maia HP, Giannini M. Influence of no-ferrule and no-post buildup design on the fatigue resistance of endodontically treated molars restored with resin nanoceramic CAD/CAM crowns. *Oper Dent*. 2014 Nov-Dec; 39(6):595-602.
- Ramírez-Sebastià A, Bortolotto T, Cattani-Lorente M, Giner L, Roig M, Krejci I. Adhesive restoration of anterior endodontically treated teeth: influence of post length on fracture strength. *Clin Oral Investig*. 2014;18(2):545-54.
- Gbadebo OS, Ajayi DM, Oyekunle OOD, Shaba PO. Randomized clinical study comparing metallic and glass fiber post in restoration of endodontically treated teeth. *Indian J Dent Res*. 2014 Jan-Feb;25(1):58-63.
- Biacchi GR, Mello B, Basting RT. The endocrown: an alternative approach for restoring extensively damaged molars. *J Esthet Restor Dent*. 2013 Dec;25(6):383-90.
- Pissis P. Fabrication of a metal-free ceramic restoration utilizing the monobloc technique. *Pract Periodontics Aesthet Dent*. 1995 June-July;7(5):83-94.
- Carvalho AO, Bruzi G, Anderson RE, Maia HP, Giannini M, Magne P. Influence of adhesive core buildup designs on the resistance of endodontically treated molars restored with lithium disilicate CAD/CAM crowns. *Oper Dent*. 2016 Jan-Feb;41(1):76-82.
- Biacchi GR, Basting RT. Comparison of fracture strength of endocrowns and glass fiber post-retained conventional crowns. *Oper Dent*. 2012 Mar-Apr;37(2):130-6.
- Magne P, Schlichting LH, Maia HP, Baratieri LN. In vitro fatigue resistance of CAD/CAM composite resin and ceramic posterior occlusal veneers. *J Prosthet Dent*. 2010 Sept;104(3):149-57.
- Schlichting LH, Maia HP, Baratieri LN, Magne P. Novel-design ultra-thin CAD/CAM composite resin and ceramic occlusal veneers for the treatment of severe dental erosion. *J Prosthet Dent*. 2011 Apr;105(4):217-26.
- Escribano NI, Del-Nero MO, de la Macorra JC. Inverse relationship between tensile bond strength and dimensions of bonded area. *J Biomed Mater Res Appl Biomater*. 2003 July 15;66(1):419-24.
- Ferraris F. Posterior indirect adhesive restorations (PIAR): preparation designs and adhesion clinical protocol. *Int J Esthet Dent*. 2017;12(4):482-502.
- Dietschi D, Spreafico R. Adhesive metal-free restorations: current concepts for the esthetic treatment of posterior teeth. *Nova Odessa: Quintessence*; 1997. p. 60-77.
- Magne P. Immediate dentin sealing: a fundamental procedure for indirect bonded restorations. *J Esthet Restor Dent*. 2005;17(3):144-54.
- Magne P, Knezevic A. Influence of overlay restorative materials and load cusps on the fatigue resistance of endodontically treated molars. *Quintessence Int*. 2009 Oct; 40(9):729-37.
- Dietschi D, Spreafico R. Evidence-based concepts and procedures for bonded inlays and onlays. Part I. Historical perspectives and clinical rationale for a biosubstitutive approach. *Int J Esthet Dent*. 2015 Summer;10(2):210-27.