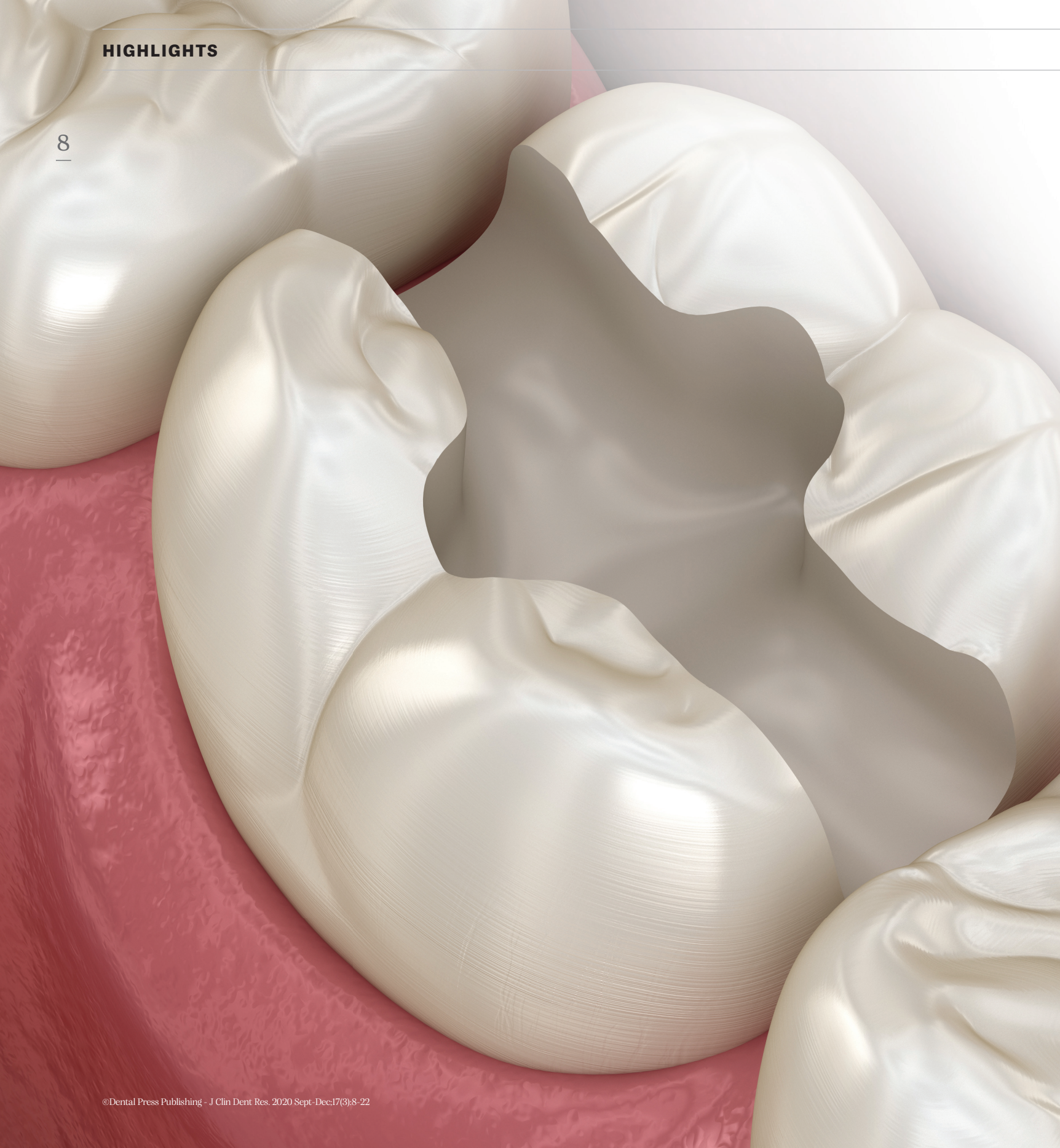



# Semi-Direct Composite Restorations

Lucas Silveira Machado<sup>1</sup> and Rodolfo Bruniera Anchieta<sup>2</sup>

In this new edition of the **Highlights** section, we will address a novelty theme in terms of restorative techniques. Information was sought regarding composite resin restorations using the **semi-direct** technique.

The semi-direct restoration technique allows for some benefits with regard to making the restoration and the **clinical time** with the patient. Perhaps the main advantage of the semi-direct technique is based on the fact that the restoration can

be performed in a single **clinical session**, by the dentist himself, without the need to send the model to be made in the prosthetic laboratory. On the other hand, contact with the patient is reduced only to the time necessary for **preparation, molding and cementation**.

However, like any novelty, we need relevant arguments for the use of the technique by the clinician, such as which are the best resins to be used, which is the best impression technique, which

Submitted: July 28, 2020 • Revised and accepted: August 18, 2020

(1) Universidade Federal do Rio Grande do Sul, Faculdade de Odontologia, Departamento de Odontologia Conservadora (Porto Alegre/RS, Brazil). Doctorate and Master's Degree in Dentistry, Universidade Estadual Paulista, Faculdade de Odontologia de Araçatuba (Araçatuba/SP, Brazil). (2) Centro Universitário do Norte Paulista, Faculdade de Odontologia (São Jose do Rio Preto/SP, Brazil). Universidade Estadual Paulista, Faculdade de Odontologia de Araçatuba, Departamento de Odontologia Restauradora (Araçatuba/SP, Brazil). Doctorate and Master's Degree in Dental Prosthesis, Universidade Estadual Paulista, Faculdade de Odontologia de Araçatuba (Araçatuba/SP, Brazil).

preparation principles should we adopt, which best casting technique to obtain of models, what is the best adhesive strategy for these situations, and what is the longevity of these restorations.

Therefore, we have gathered some of the main published scientific articles, which addressed the topic “semi-direct restorations”, for the elaboration of information, with critical and interpretative analyzes of the evidence available in the literature.

The first article compares the mechanical performance and enamel fractures of direct, semi-direct and CAD / CAM restorations, performed in large MOD-type cavities. The article was published in *Dental Materials* in 2018.

### OPTIMIZATION OF LARGE MOD RESTORATIONS: COMPOSITE RESIN INLAYS VS. SHORT FIBER-REINFORCED DIRECT RESTORATIONS

Luciana Mara Soares, Mehrdad Razaghy,  
Pascal Magne

*Dent Mater.* 2018 Apr;34(4):587-597.

doi: 10.1016/j.dental.2018.01.004. Epub 2018 Jan 20.

#### ABSTRACT

**Objective:** To compare mechanical performance and enamel-crack propensity of direct, semi-direct, and CAD/CAM approaches for large MOD composite-resin restorations. **Methods:** 45

extracted maxillary molars underwent standardized slot-type preparation (5-mm depth and bucco-palatal width) including immediate dentin sealing (Optibond FL) for the inlays (30 teeth). Short-fiber reinforced composite-resin (EverX Posterior covered by Gradia Direct Posterior) was used for the direct approach, Gradia Direct Posterior for the semi-direct, and Cerasmart composite resin blocks for CAD/CAM inlays. All inlays were adhesively luted with light-curing composite-resin (preheated

Gradia Direct Posterior). Shrinkage-induced enamel cracks were tracked by transillumination photography. Cyclic axial isometric chewing (5-Hz) was simulated, starting with a load of 200N (5000 cycles), followed by stages of 400, 600, 800, 1000, 1200, and 1400N (maximum 30,000 cycles each) until fracture or to a maximum of 185,000 cycles. Survived specimens were subjected to cyclic-load-to-failure test at 30-degree angle on the palatal cusp. **Results:** Only small shrinkage-induced cracks were found in 47% of the direct restorations compared to 7% and 13% of semi-direct and CAD/CAM inlays, respectively. Survival to accelerated fatigue was similar for all three groups (Kaplan-Meier  $p > .05$ ) and ranged between 87% (direct) and 93% (semi-direct and CAD/CAM). Cyclic-load-to-failure tests did not yield significant differences either (Life Table analysis,  $p > .05$ ) with median values of 1675N for CAD/CAM inlays, 1775N for fiber-reinforced direct restorations and 1900N for semi-direct inlays. **Significance:** All three restorative techniques yielded excellent mechanical performance above physiological masticatory loads. Direct restorations performed as good as inlays when a short-fiber reinforced composite-resin base was used.

**COMMENTS:** This work evaluated the influence of three restorative approaches (direct, semi-direct and CAD / CAM) for large restorations of composite resin MOD and their effects on the mechanical performance and the tendency to enamel cracking. The null hypotheses were accepted in part because there was no significant difference found in the mechanical performance between the restorative techniques used. There were, however, differences in the propensity to crack the enamel. From a clinical point of view, it is undeniable that occlusion and anatomical morphology are better dominated with indirect inlays than with direct techniques. The cost-effectiveness ratio for the patient, however, can be a limiting factor for choosing indirect. Additional clinical studies should confirm the alternative choice of lined restorations using fiber-reinforced composite with a dentin substitute. The challenge of restoring large MOD defects was assessed and all three restorative techniques produced excellent mechanical performance, even above physiological masticatory loads. Large direct MOD restorations can work just as well as inlays (semi-direct or CAD / CAM) when using a fiber-reinforced composite resin base.

The second article evaluates some reports and clinical evaluations of restorations performed on composite resins, in preparation of the onlay and inlay type. The article was published in the *International Journal of Esthetic Dentistry*, in the year 2019.

### **EVIDENCE-BASED CONCEPTS AND PROCEDURES FOR BONDED INLAYS AND ONLAYS. PART III. A CASE SERIES WITH LONG-TERM CLINICAL RESULTS AND FOLLOW-UP**

**Didier Dietschi, Roberto Spreafico**

*Int J Esthet Dent. 2019;14(2):118-133.*

#### **ABSTRACT**

This third article in this series (Part III) aims to present new clinical results and long-term follow-up of resin composite inlays and onlays using the modern clinical concepts presented in the Part I and Part II articles. These revised protocols have contributed to eliminating the most frequent difficulties related to the preparation, isolation, impression taking, and cementation of tooth-colored inlays and onlays. This clinical report presents a series of 25 cases of indirect or semidirect inlays and onlays (intra- and extraoral techniques) made of microhybrid and nanohybrid composites with 6- to 21-year follow-ups. The restoration performance was assessed through

clinical examination, intraoral radiographs, and clinical photographs. The overall clinical assessment aimed to confirm the absence (success) or presence (failure) of decay or restoration fracture, while the restoration quality was judged on intraoral photographs. The restoration status with regard to margins, anatomy, and color was assessed using three quality scores (A = ideal, B = satisfactory, C = insufficient). Descriptive statistics were used to evaluate the possible impact of composite structure (microhybrid or nanohybrid) or observation time on restoration quality. Over this medium- to long-term observation period, no clinical failure was reported. Only a few restorations (mainly those made of conventional inhomogeneous nanohybrid) presented discrete marginal discoloration (n = 4) or occlusal anatomy change due to wear (n = 7). This first clinical

survey with long-term follow-up supports the application of the aforementioned clinical concepts, which thus far have only been validated by in vitro studies.

**COMMENTS:** The first and second parts of this series of articles described the indications, advantages and detailed clinical procedures for the manufacture of semi-direct inlays, applying revised and optimized clinical and biomechanical concepts. The most relevant improvements brought to the most comprehensive treatment approach were immediate dentin sealing, post-dentin preparation (known as double bonding or immediate dentin sealing [IDS]). Another principle discussed was regarding the elevation of the margin in very deep preparations in the proximal (replacement of the cervical margin or elevation of the deep margin). The immediately formed adhesive base (IDS) protects pulp-dentin structures from any contamination or physical-chemical disturbance during the temporary phase, as well as stabilizes and improves the quality of the adhesive interface. In addition, this updated general clinical protocol allows the safe use of temporary cementless restorations and facilitates the manufacture of restorations,

thanks to a more uniform cavity design. The aforementioned concepts, covering the latest material and technology developments, have fundamentally changed the clinical approach of the authors and the procedures for indirect partial posterior restorations (inlays and onlays). The suggested procedures also help the professional to eliminate the most frequent difficulties related to the preparation, isolation, molding and cementation of dental inlays and onlays, while preventing complications such as discomfort during the interim phase and post-operative sensitivity. Interestingly, the current results suggest that material wear is not a problem for indirect composite restorations, and that the clinical application of the CMR (cervical margin elevation) concept has not triggered any recurrent proximal failure within the cases studied. Despite the known limits of a retrospective clinical evaluation and the low number of controlled restorations, the data from this research combined with the numerous positive results in vitro in relation to the clinical protocols used in this article, support the continued use of composite resins and indirect techniques for restoration extensive cavities.

The third article compared different materials to obtain models with silicone. The article was published in the *International Journal of Esthetic Dentistry*, in 2020.

## COMPARATIVE ANALYSIS OF ELASTOMERIC DIE MATERIALS FOR SEMIDIRECT COMPOSITE RESTORATIONS

Joao Luiz de Abreu, Steven Katz,  
Cristian Sbardelotto, Dindo Mijares, Lukasz Witek,  
Paulo G. Coelho, Ronaldo Hirata  
*Int J Esthet Dent. 2020;15(3):344-354.*

### ABSTRACT

**Aim:** Die silicone materials are used to build chairside composite restorations. The purpose of this study was to compare the flowability, dimension accuracy, and tear strength of four elastomeric die materials. Material and methods: Materials were divided into four groups: Mach-2 (M2), Scan Die (SD), GrandioSO Inlay System (GIS), and Impregum-F (IM). Flowability analysis was carried out using the shark fin test (SFT). For dimension accuracy, impressions were taken from a premolar Class I preparation and an elastomeric model was cast. Composite resin restorations were built and positioned into the premolar for gap measurement. The mean gap length was divided into

three levels: acceptable (A), not acceptable (NA), and misfit (M). For tear strength, strip specimens were made with a V-shaped notch (n = 6). The specimens were tested in a universal machine until tear. All data were analyzed statistically with a confidence interval of 95%. Results: GIS showed the lowest flowability values, with no differences between IM, M2, and SD. For dimension accuracy, IM showed 100% 'A' gap values, followed by M2 (80%), SD (60%), and GIS (60%). For tear strength, IM showed the highest values, followed by M2, GIS, and SD. Conclusions: M2, SD, and IM had similar flowability, while GIS had the lowest. IM presented higher tear strength than M2, followed by GIS and SD. IM showed the highest degrees of acceptable gap filling, followed by M2. **COMMENTS:** According to the results of the present study, the null hypothesis was rejected, since there were differences between the silicones for models in all the proposed tests. The results

showed that the silicones for models, especially those performed with March-2, were able to provide more accurate models for the manufacture of composite restorations using the semi-direct technique. However, when compared to Impregum, tear resistance and dimensional accuracy performed less than expected. These properties still need to be improved to make these materials potentially more accurate and reliable. Further studies should be done to elucidate the rheological properties of these silicone materials for models. The use of a rheometer has been shown to be useful for measuring some clinically relevant properties of impression materials, such

as elasticity and stiffness. These instruments could, therefore, be considered qualified for use when evaluating these materials in future investigations. Model silicones have recently replaced plaster models to manufacture composite restorations using a semi-direct technique. Although the reliability of plaster models has been proven, model silicones have the potential to facilitate and simplify the technique. Although these materials can positively influence clinical results, their properties have not yet been analyzed and compared from a clinical point of view.

The fourth article presents the direct-indirect technique, observing technical concepts and relevant clinical steps. The article was published in the *Compendium Continuing of Education Dentistry*, in the year 2017

## THE DIRECT-INDIRECT TECHNIQUE FOR COMPOSITE RESTORATIONS REVISITED

**André V. Ritter, Newton Fahl Jr, Marcos Vargas,  
Rodrigo R. Maia.**

*Compend Contin Educ Dent. 2017 Jun;38(6):e9-e12.*

### ABSTRACT

In the direct-indirect composite technique, composite is applied to a nonretentive tooth preparation (eg, a noncarious cervical lesion or a veneer/inlay/onlay preparation) without any



bonding agent, sculpted to a primary anatomic form, and light-cured. The partially polymerized restoration is then removed from the preparation and finished and tempered extraorally chairside. The finished inlay is bonded to the preparation using a resin-based luting agent. Advantages of this technique include enhanced physical and mechanical properties afforded by the extraoral chairside tempering process because of increased monomer conversion, and greater operator control over the final marginal adaptation, surface finishing and polishing, and anatomy of the restoration, given that these elements are defined outside of the patient's mouth. The direct-indirect approach also affords enhanced gingival health and patient comfort. This article presents a clinical case in which the direct-indirect composite technique was used to restore three noncarious cervical lesions on the same quadrant on an adult patient. Clinical steps and tips for success are offered. The authors also present scanning electron microscope and atomic force microscope images showing the excellent marginal fit obtained with the direct-indirect composite technique.

**COMMENTS:** Although the direct-indirect composite technique is not new, recent

advances in materials, instrumentation and LEDs have generated renewed interest in this restorative approach, given its advantages over directly placed composites. Modern composites, when effectively used, can achieve aesthetics, including surface texture, shadow matching and characterization, which are similar to ceramic in many cases. In addition, state-of-the-art light devices provide energy that comes close to composites processing devices made in the laboratory. All of these advances enable clinicians to obtain semi-direct resin restorations, which are an excellent restoration option for many cases that would otherwise be highly challenging to complete using a direct composite technique. The superior marginal finish obtained with the direct-indirect technique was confirmed by studies of scanning electron microscopy and atomic force microscopy in the results presented in this article. The technique of direct-indirect restoration represents a different technique, and this approach is not a solution for all problems related to composite resins and certainly has its limitations, as in situations where tooth preparation is retentive, in which case a direct restoration technique would allow for greater tooth conservation.

As with any evolving clinical technique, more research is needed to determine ideal adhesive protocols for the direct-indirect composite technique and to more adequately compare

its marginal adaptation and clinical performance with the traditional direct composite resin technique.

The fifth article presents a randomized clinical study between the direct and semi-direct technique in 24 months. The article was published in *Clinical Oral Investigations* in 2020.

### A RANDOMIZED CLINICAL TRIAL OF CLASS II COMPOSITE RESTORATIONS USING DIRECT AND SEMIDIRECT TECHNIQUES

Carlos Rocha Gomes Torres,  
Mariane Cintra Mailart, Érica Crastechini,  
Fernanda Alves Feitosa,  
Stella Renato Machado Esteves,  
Rebeca Di Nicoló, Alessandra Bühler Borges.  
*Clin Oral Investig.* 2020 Feb;24(2):1053-1063.

#### ABSTRACT

**Objective:** This prospective study evaluated the clinical performance of large class II restorations made with different techniques over 24 months. **Materials and methods:** Thirty patients received two class II restorations (n = 60) using a nanohybrid composite and different restorative

techniques (direct (DT), semidirect (SDT)), in a split-mouth randomized design. The same adhesive system was applied for all restorations. For DT, the restorative material was applied directly inside the tooth preparation. For SDT, a tooth preparation impression was obtained using alginate and a silicone flexible die was prepared. The restoration was made chairside on the model and additionally light cured. After that, it was cemented in preparation using resinous cement. All restorations were evaluated using the FDI criteria after 7 days, 6, 12, and 24 months postoperatively. **Results:** After 24 months, 24 patients attended the recall and 48 restorations

were evaluated. Fisher's statistical analysis (5%) showed no difference between the techniques. Nevertheless, Friedman's test showed significant differences for some criteria after 12 months of evaluation for both techniques. Postoperative sensitivity was reported in one DT restoration. Also, after 24 months, one SDT restoration presented marginal fracture, which was deemed unsatisfactory. **Conclusions:** After a 24-month follow-up, no significant difference between the tested techniques was detected. The restorations performed with both techniques produced clinically acceptable restorations.

Clinical relevance: This study demonstrated the viability of applying two different operator

techniques (direct and semidirect) for class II resin composite restorations.

**COMMENTS:** This randomized, split-mouth design clinical study evaluated composite resin restorations by the direct and semi-direct technique. Using the FDI criteria, the authors found no differences between the techniques over 24 months, with only one failure found for each group. Despite the similar results between the techniques, the authors draw attention to the higher percentage of "clinically excellent" scores for superficial smoothness and superficial pigmentation for the semi-direct technique. However, semi-direct restorations show greater marginal pepper, probably due to the cementation line.

The sixth article presents an evaluation of the clinical performance of restorations made by the direct and semi-direct technique, in 3.5 years of follow-up. The article was published in the *Journal of Dentistry* in 2005.

### CLINICAL PERFORMANCE AND MARGINAL ADAPTATION OF CLASS II DIRECT AND SEMIDIRECT COMPOSITE RESTORATIONS OVER 3.5 YEARS *IN VIVO*

Roberto C. Spreafico, Ivo Krejci, Didier Dietschi

*J Dent.* 2005 Jul;33(6):499-507.

#### ABSTRACT

**Objective:** The study evaluated the clinical performance and marginal adaptation of direct and semi-direct class II composite restorations in a split-mouth design over 3.5 years. **Design:** 44 upper posterior teeth in 11 adults with primary carious lesions were treated with 22 direct and 22 semi-direct restorations. Conventional cavities were prepared for both types of restorations. A fine fine hybrid composite (APH) and a multifunctional adhesive system (Prisma universal bond 3) were used for all restorations. The incremental “3-sided light curing” technique was applied to direct restorations. Semi-direct inlays were prefabricated on silicone casts and post-cured using light and heat. Clinical performance was evaluated using modified USPHS parameters, while marginal adaptation was

judged on replicas, using SEM and a standardized evaluation technique. **Results:** Clinical results after 3.5 years revealed a 100% retention rate with no fractures, sensitivity or recurrent caries for both types of restorations. SEM-evaluation of the occlusal margins showed at the tooth-restoration interface relatively low rates of marginal openings over the observation period (4-8%). Marginal restoration fractures ranged between 1 and 2%, marginal tooth fractures between 3 and 9%. Differences between the restorative techniques and after the different time observation periods were not statistically significant. Proportions of marginal fractures and openings at the restoration-luting composite interface were less than 10% after 3.5 years. **Conclusion:** The results indicated no significant differences for direct and semi-direct fine hybrid composite restorations in medium size cavities in posterior teeth with respect to clinical performance and marginal adaptation over 3.5 years.

**COMMENTS:** This study evaluated the clinical performance and marginal adaptation of composite resin restorations made by the direct (incremental) and semi-direct technique, through the making of the restoration in a flexible silicone cast, over a period of 3.5 years. Among the various assessments over 14 days, 9 months and 3.5 years, there were no differences between the techniques, and any flaws and sensitivity for both. Perhaps in a longer time of clinical evaluation the differences will be evident, since the extra-oral cure of the resin made by the

semi-direct technique is more effective, improving some properties. Another important factor to be considered is that in most clinical studies, operators are highly specialized, performing well in both techniques, a fact that can be different when observing a larger group of dentists in operation. Thus, in large cavities, the semi-direct technique can be a good alternative, facilitating a good adaptation, polishing, and occlusal adjustment.

The seventh article presents a clinical evaluation of the direct and semi-direct technique, in Class V cavities. The article was published in *Clinical Oral Investigations*, in the year 2020.

### **A 2-YEAR CLINICAL EVALUATION OF DIRECT AND SEMI-DIRECT RESIN COMPOSITE RESTORATIONS IN NON-CARIOUS CERVICAL LESIONS: A RANDOMIZED CLINICAL STUDY**

Taciana Marco Ferraz Caneppele,  
Laura Célia Fernandes Meirelles,  
Rafael Santos Rocha, Lucélia Lemes Gonçalves,  
Daniele Mara Silva Ávila,  
Sérgio Eduardo de Paiva Gonçalves,  
Eduardo Bresciani.

*Clin Oral Investig.* 2020 Mar;24(3):1321-1331.

#### **ABSTRACT**

**Objective:** The purpose of this study was to evaluate the 2-year success of resin composite restorations in non-cariou cervical lesions (NCCLs) using the direct or semi-direct techniques. **Materials and methods:** Thirty volunteers presenting with


at least two NCCLs were included. Each participant received one restoration using the direct technique and the other using the semi-direct technique, totaling 60 restorations. Time for completing the treatment was computed. Assessments at baseline, 7 days, and 6, 12, and 24 months were performed using the modified United States Public Health Service criteria. Descriptive analysis was reported as a percentage of successful treatments. For inferential analysis, the Student t test was used to evaluate the differences between extension, depth, and time. The chi-square/Fisher tests were used to compare treatment success after each period ( $\alpha = 0.05$ ). The results were evaluated by using the Kaplan-Meier survival analysis. **Results:** Differences were detected regarding mean  $\pm$  standard deviation time, in which direct and semi-direct procedures were accomplished in 21.8 ( $\pm$  14.5) and 35.3 ( $\pm$  19.9) min, respectively. Of the 60 restorations placed, 7 failed in the direct group while 8 failed in the semi-direct group up to 2 years. No differences were detected between restorative protocols. The cumulative survival was 88.5% and 88.4% for the direct technique and semi-direct techniques after 24 months,

respectively. **Conclusion:** The tested restorative protocols present similar results for NCCLs within the studied periods. **Clinical relevance:** The semi-direct technique exhibited clinical performance similar to direct technique for NCCL, demonstrating an alternative for restorations of these lesions.

**COMMENTS:** In most studies on semi-direct restorations, it is related to large cavities (Class II and Class II complex), usually in molars and premolars. The present study evaluated direct (incremental) and semi-direct restorations in non-carious cervical lesions. In fact, although this type of restoration is generally small, it presents a great challenge, as the cavity is difficult to retain, and the dentin present is often sclerotic, impairing the bonding via the hybrid layer. In this study, the semi-direct restorations procedure was performed directly on the cavity, the finishing and polishing performed outside the mouth, and then cemented with flow type resin. There were no differences between the techniques, but the execution time of the semi-direct technique was 50% longer.

## FINAL CONSIDERATIONS

Dentistry is in constantly evolution, and we have to keep up with this evolution, otherwise we will be negligent towards patients and ourselves. Composite resin restoration techniques are constantly evolving in an attempt to facilitate procedures, increase resistance, improve longevity, as well as expand the clinical indications for their use. The semi-direct technique, although it has

been described for some time, is nowadays in evidence. Among the literature highlighted above, it can be said that it is a promising technique. Good laboratory results, especially with regard to surface polishing, and curing of the composite. And clinical results comparable with the incremental technique, showing a low failure rate, and versatility similar to indirect techniques in large cavities. 

## REFERENCES

1. Soares LM, Razaghy M, Magne P. Optimization of large MOD restorations: composite resin inlays vs. short fiber-reinforced direct restorations. *Dent Mater*. 2018 Apr;34(4):587-97.
2. Dietschi D, Spreafico R. Evidence-based concepts and procedures for bonded inlays and onlays. Part III. A case series with long-term clinical results and follow-up. *Int J Esthet Dent*. 2019;14(2):118-33.
3. Abreu JL, Katz S, Sbardelotto C, Mijares D, Witek L, Coelho PG, et al. Comparative analysis of elastomeric die materials for semidirect composite restorations. *Int J Esthet Dent*. 2020;15(3):344-54.
4. Ritter AV, Fahl Júnior N, Vargas M, Maia RR. The direct-indirect technique for composite restorations revisited. *Compend Contin Educ Dent*. 2017 June;38(6):e9-e12.
5. Torres CRG, Mailart MC, Crastechini E, Feitosa FA, Esteves SRM, Di Nicoló R, et al. A randomized clinical trial of class II composite restorations using direct and semidirect techniques. *Clin Oral Investig*. 2020 Feb;24(2):1053-63.
6. Spreafico RC, Krejci I, Dietschi D. Clinical performance and marginal adaptation of class II direct and semidirect composite restorations over 3.5 years in vivo. *J Dent*. 2005 July;33(6):499-507.
7. Caneppele TMF, Meirelles LCF, Rocha RS, Gonçalves LL, Ávila DMS, Gonçalves SEP, et al. A 2-year clinical evaluation of direct and semi-direct resin composite restorations in non-carious cervical lesions: a randomized clinical study. *Clin Oral Investig*. 2020 Mar;24(3):1321-31.